



**PATIENT**

Zoe Kyle

**SPECIES**

Canine

**BREED**

Shih Tzu

**SEX**

Spayed Female

**AGE**

11 Years

**WEIGHT**

12.2 Lbs.

**PRESENTING CLINICAL SIGNS**

History: increased coughing and heavy breathing the past few days; evaluate current murmur. On lasix 12.5 mg bid, vetmedin 2.5 mg x 1/2 bid

Abnormal PE/Chem/CBC/UA Results: n/a

**ULTRASONOGRAPHIC EXAMINATION OF THE HEART**

| CANINE CARDIAC PARAMETERS | MR VMAX (m/s) | TR VMAX (m/s) | LA/AO (Boon method) | LA/AO (Heart Base; Swe) | FS (%)                          | EF (%)                                   | EPSS (cm)                                |
|---------------------------|---------------|---------------|---------------------|-------------------------|---------------------------------|--|--|
| NORMAL PARAMETER          | 4.5-5.5       | <2.7          | 1.3                 | <1.6                    | 28-40                           | 40-100                                   | <0.6                                     |
| PATIENT                   | 5.0           | --            | 2.0                 | 2.33                    | 48                              | 81                                       | 0.1                                      |
| CANINE CARDIAC PARAMETERS | HR (BPM)      | AV VMAX (m/s) | PV MAX (m/s)        | BODY WEIGHT (kg)        | LA 2D short axis Base view (cm) | LVIDd Avg; 2D and m-mode short axis (cm) | LVIDs Avg; 2D and m-mode short axis (cm) |
| NORMAL PARAMETER          | 50-100        | 0.7-1.7       | 0.7-1.6             |                         |                                 |  |  |
| PATIENT                   | 148           | --            | --                  | --                      | 3.67                            | 3.44                                     | --                                       |

**INTERPRETED BY**

Eric Lindquist, DMV  
DABVP, Cert. IVUSS

**IMAGING PERFORMED BY**

Diane McFadden

**HOSPITAL NAME**

Byram AH

**REFERRING VET**

Dr. Cruz

**INVOICE**

13031

**DATE**

12/13/21

**Cardiac Presentation**

The cardiac presentation in this patient presented volume overload of the left atrium and left ventricle. The left atrial size and left ventricular internal diameter have increased significantly compared to the prior sonogram. Prolapse of the anterior mitral valve leaflet noted. A comet tail lung pattern noted in the peripheral fields, likely owing to pulmonary edema- chest radiographs warranted to assess. Tricuspid insufficiency noted. Normal right atrial size. No evidence of passive congestion in the liver. Pericardial and pleural spaces were normal. Right ventricle was unremarkable. Arrhythmia also noted.

**ULTRASONOGRAPHIC FINDINGS**

- Progressed mitral insufficiency
- Stage C-1 valvular disease
- Arrhythmia. EKG indicated.

**INTERPRETATION OF THE FINDINGS & FURTHER RECOMMENDATIONS**

Triple therapy warranted in this patient in addition to Pimobendan at 0.3 mg per kg BID, Lasix 2-3 mg per kg BID, Ace-inhibitor .5 mg per kg SID progressing to BID and Spironolactone at 1-2 mg per kg BID. Recheck echo in one month. Hycodan may be utilized for cough.



**PATIENT**

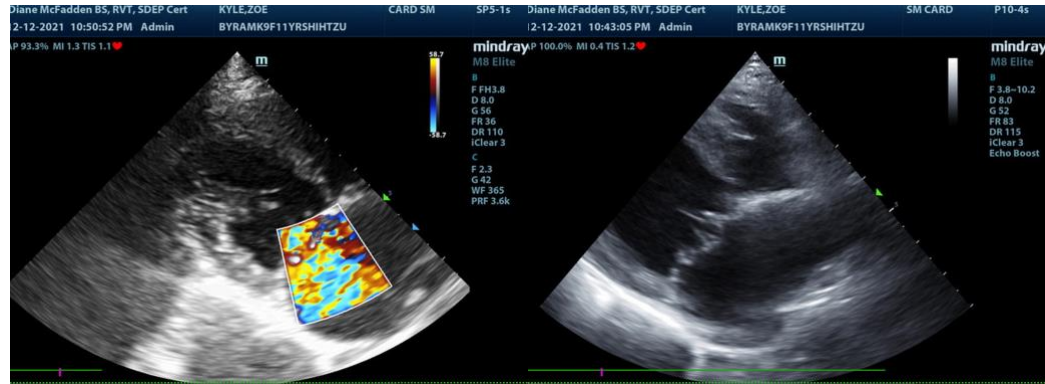
Zoe Kyle

**SPECIES**

Canine

**BREED**

Shih Tzu



**SEX**

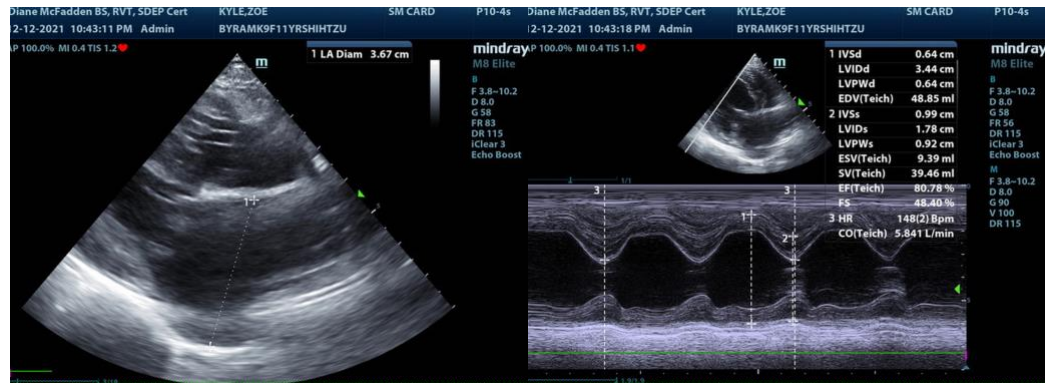
Spayed Female

**AGE**

11 Years

**WEIGHT**

12.2 Lbs.



**INTERPRETED BY**

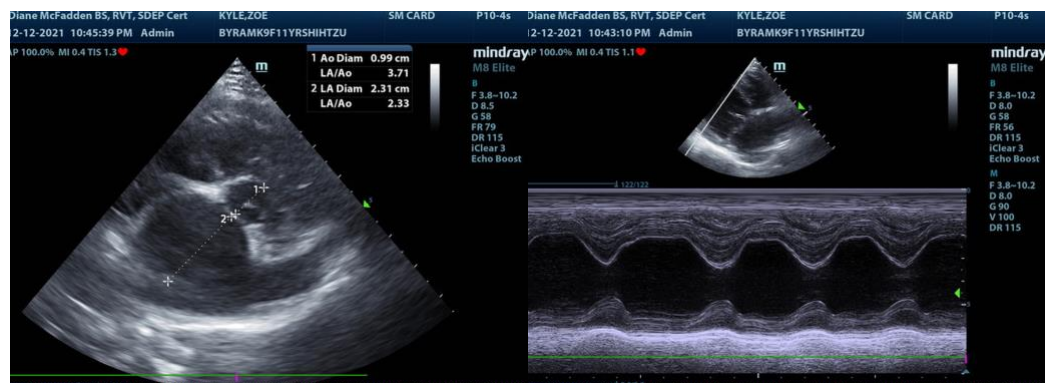
Eric Lindquist, DMV  
DABVP, Cert. IVUSS

**IMAGING PERFORMED BY**

Diane McFadden

**HOSPITAL NAME**

Byram AH



**REFERRING VET**

Dr. Cruz

**INVOICE**

13031

**DATE**

12/13/21

The information and recommendations provided are based on the images presented by the referring veterinarian. No evaluation can be communicated regarding pathology that was not visible in the image/video clips provided.

Thank you for this referral. If the clinical or image interpretation does not parallel your findings or if I can be of any further assistance please contact me.

**Eric Lindquist**, DMV, DABVP, Cert. IVUSS, CEO of SonoPath.com  
info@SonoPath.com