

PATIENT

Nugget Johnson

SPECIES

Canine

BREED

Shepherd Mix

SEX

Neutered Male

AGE

7 Years

WEIGHT

67 Lbs.

INTERPRETED BY

Eric Lindquist, DMV,
DABVP, Cert. IVUS

HOSPITAL NAME

Cottage Grove VC

REFERRING VET

Dr. Damewood

INVOICE NUMBER

13035

DATE

12/13/21

PRESENTING CLINICAL SIGNS

History: 15 lb weight loss in last 8 weeks. Anorectic, possibly bloody in urine. Pale mucous membranes, enlarged submandibular lymph nodes. Abdominal palpation suggests mass present but pt is painful and will not allow thorough palpation.
Abnormal PE/Chem/CBC/UA Results:

ULTRASONOGRAPHIC EXAMINATION OF THE ABDOMEN

Urinary System

The **urinary bladder** presented chronic cystitis pattern with a 7 mm bladder wall thickening. Echogenic mucosal remodeling noted.

The **kidneys** revealed normal size and structure, corticomedullary definition and ratio for this age. The cortices presented largely uniform texture with normal echogenic relationship to liver and spleen. Medullary structure differed distinctly from the cortex and no evidence of pelvic dilation was present. The capsules were acceptably uniform without significant irregularities. The left kidney measured 6.75 cm. The right kidney measured 6.74 cm.

Adrenal Glands

Both **adrenal glands** were visualized and recognized as having normal shape, size, position and echogenicity for this breed. The phrenic vasculature, glandular echogenicity and detail were unremarkable. Capsule, cortex, and medullary definition were normal for this age patient. The left adrenal gland measured 2.74 cm x 0.69 cm at the cranial pole and 0.68 cm at the caudal pole. The right adrenal gland measured 2.33 cm x 1.24 cm at the cranial pole and 0.97 cm at the caudal pole.

Spleen

The **spleen** was enlarged with micronodular changes and generalized swelling. Vascularity appeared normal.

Liver

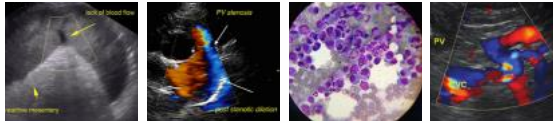
The **liver** was also swollen with mildly irregular contour and enhanced mesentery. The gallbladder and common bile duct were unremarkable. Hepatic lymph nodes were enlarged, rounded and hypoechoic (up to 3 cm).

Gastrointestinal

Examination of the **gastrointestinal tract** revealed a stomach and intestine free of stasis, of normal wall thickness, acceptable curvilinear mural detail, and peristaltic activity. The small intestine and colon were unremarkable. No obstructive or overt infiltrative disease was noted. No associated abnormal lymphatic activity was noted.

Pancreas

The base and limbs of the **pancreas** were observed to be largely isoechoic to surrounding omental fat. Pancreatic duct and capsular contour were acceptably normal and parenchyma respected normal curvilinear patterns. No overt evidence of active inflammatory or neoplastic disease was noted.



PATIENT *Other*

Nugget Johnson
A rapid view of the **heart** revealed no overt abnormality.

ULTRASONOGRAPHIC FINDINGS

- SPECIES**
- Splenohepatic infiltrative pattern. Strong concern for round cell neoplasia
 - Hepatic lymphadenopathy
- Canine
- Chronic cystitis bladder pattern

INTERPRETATION OF THE FINDINGS & FURTHER RECOMMENDATIONS

BREED

Shepherd Mix
FNA of the spleen and liver recommended.

SEX

Neutered Male

AGE

7 Years

WEIGHT

67 Lbs.

INTERPRETED BY

Eric Lindquist, DMV,
DABVP, Cert. IVUS

HOSPITAL NAME

Cottage Grove VC

REFERRING VET

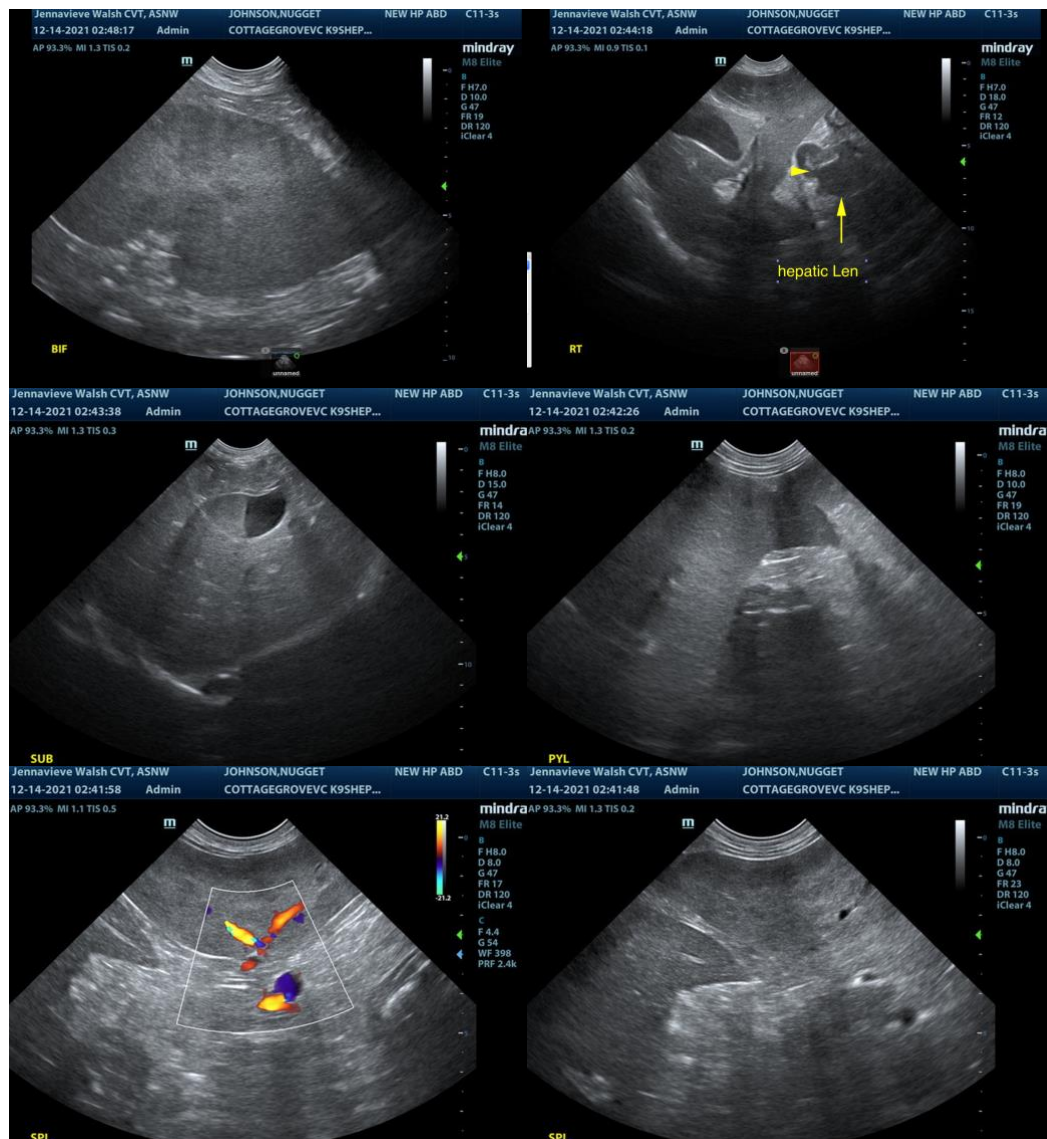
Dr. Damewood

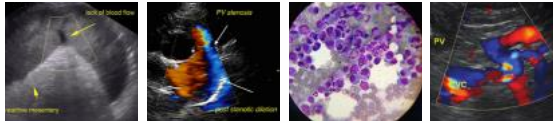
INVOICE NUMBER

13035

DATE

12/13/21





PATIENT

Nugget Johnson

SPECIES

Canine

BREED

Shepherd Mix

SEX

Neutered Male

AGE

7 Years

WEIGHT

67 Lbs.

INTERPRETED BY

Eric Lindquist, DMV,
DABVP, Cert. IVUSS

HOSPITAL NAME

Cottage Grove VC

REFERRING VET

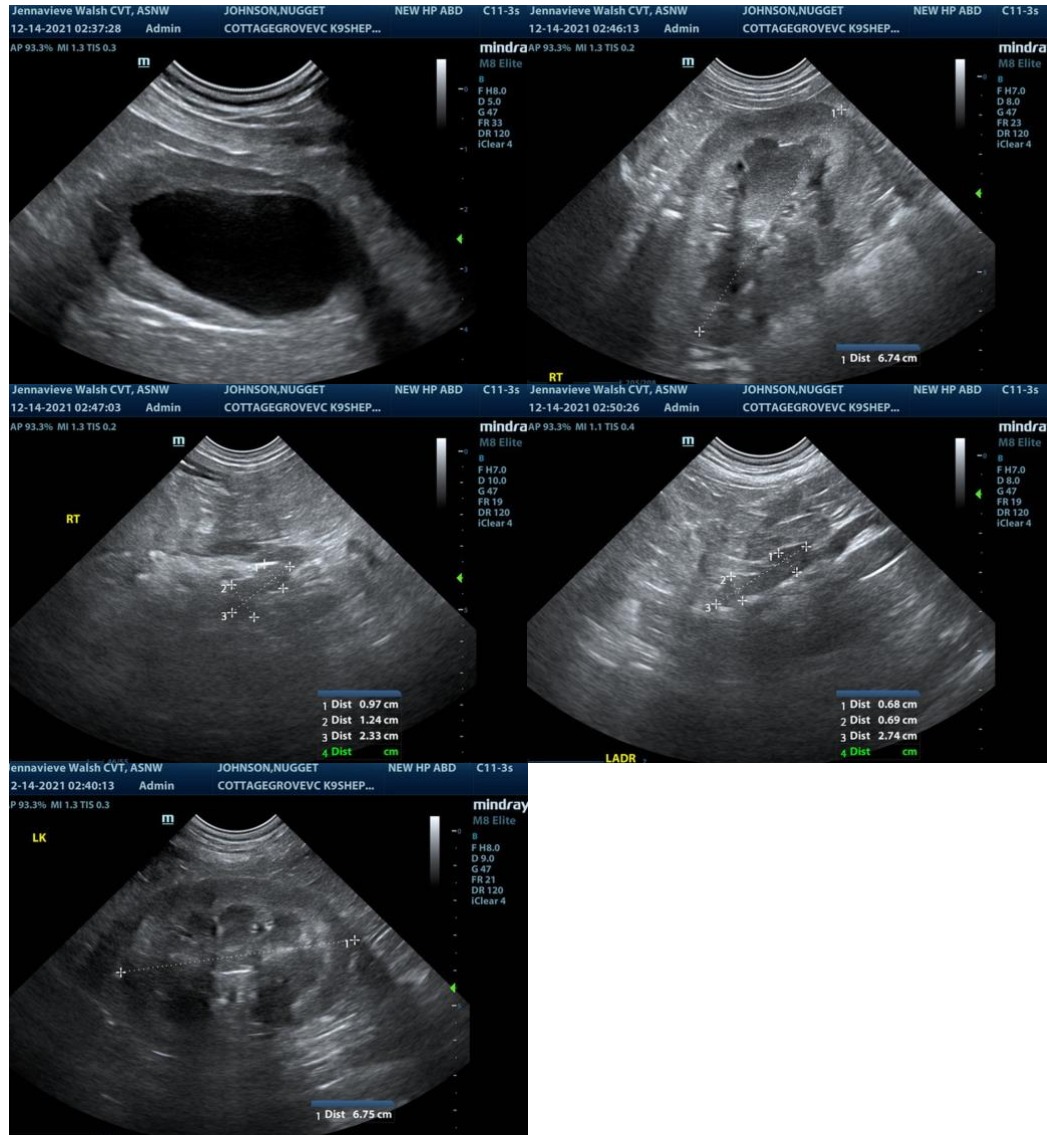
Dr. Damewood

INVOICE NUMBER

13035

DATE

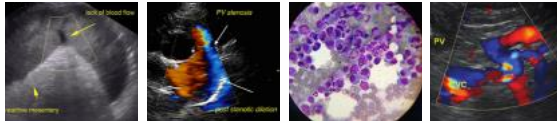
12/13/21



The information and recommendations provided are based on the images presented by the referring veterinarian. No evaluation can be communicated regarding pathology that was not visible in the image/video clips provided.

Thank you for this referral. If the clinical or image interpretation does not parallel your findings or if I can be of any further assistance please contact me.

Eric Lindquist, DMV, DABVP, Cert. IVUSS, CEO of SonoPath.com
Eric.Lindquist@SonoPath.com



PATIENT

Nugget Johnson

SPECIES

Canine

BREED

Shepherd Mix

SEX

Neutered Male

AGE

7 Years

WEIGHT

67 Lbs.

INTERPRETED BY

Eric Lindquist, DMV,
DABVP, Cert. IVUSS

HOSPITAL NAME

Cottage Grove VC

REFERRING VET

Dr. Damewood

INVOICE NUMBER

13035

DATE

12/13/21