



PATIENT

Maggie Munafo

SPECIES

Canine

BREED

Standard Poodle

SEX

Spayed Female

AGE

8 years

WEIGHT

53.8 lbs

INTERPRETED BY

Eric Lindquist, DMV
DABVP, Cert. IVUSS

IMAGING PERFORMED BY

Laux

HOSPITAL NAME

Round Valley VA

REFERRING VET

Dr. Laux

INVOICE

94526

DATE

12/13/21

PRESENTING CLINICAL SIGNS

History: Chronic Hematuria
Abnormal PE/Chem/CBC/UA Results: Vulva slightly recessed. E. coli grown on urine culture.

ULTRASONOGRAPHIC EXAMINATION OF THE ABDOMEN

Urinary System

The **urinary bladder**, trigone, and pelvic urethra presented normal thicknesses and normal tone. The pelvic urethra was imaged 2.0 cm beyond the cystourethral junction. The ureters were not visible which is normal. No uroliths or sediment were visualized and anechoic urine was present. No evidence of inflammatory or neoplastic changes was noted. Ureteral papillae were normal.

ULTRASONOGRAPHIC FINDINGS

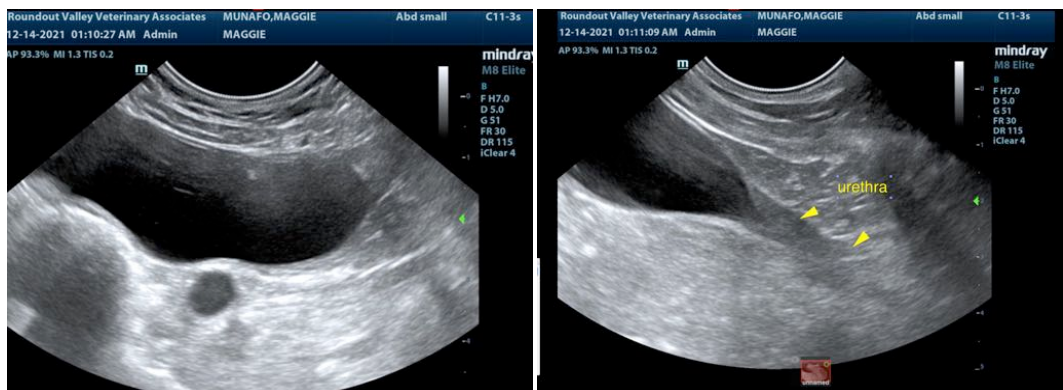
Normal bladder.

INTERPRETATION OF THE FINDINGS & FURTHER RECOMMENDATIONS

There is no evidence of structural bladder, cystourethral junction or urethral pathology. Other causes of hematuria may be derived from the kidneys such as pyelectasia, embedded urinary tract infection or passage of calculi. Imaging of the kidneys would be ideal.

Canine Chronic UTI Protocol

I recommend **Enrofloxacin** (5-10 mg/kg SID PO) (In patients > 1 year of age) in late pm after urination to maximize urinary concentrations overnight. This assumes that culture supports this use. Repeat **culture** at 3-4 weeks and continue treatment at least 7-10 days post negative urinary sediment and negative culture. *Note: Negative culture does not necessarily mean lack of UTI.* Other favorite antibiotics for chronic UTI include third generation Cefa (Ceftiafur or similar s.i.d. injectable) or Clavamox. If suspicion of occult urinary incontinence is present then **phenylpropanolamine (PPA)** (1-2 mg/kg BID) can be employed long term to enhance urethral tone.





PATIENT

Maggie Munafo

SPECIES

Canine

BREED

Standard Poodle

SEX

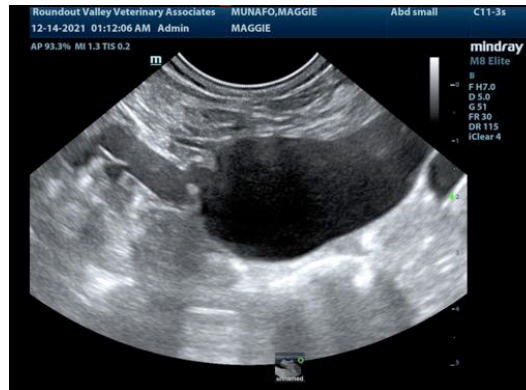Spayed Female

AGE

8 years

WEIGHT

53.8 lbs



The information and recommendations provided are based on the images presented by the referring veterinarian. No evaluation can be communicated regarding pathology that was not visible in the image/video clips provided.

Thank you for this referral. If the clinical or image interpretation does not parallel your findings or if I can be of any further assistance please contact me.

Eric Lindquist, DMV, DABVP, Cert. IVUSS, CEO of SonoPath.com
info@SonoPath.com

INTERPRETED BY

Eric Lindquist, DMV
DABVP, Cert. IVUSS

IMAGING PERFORMED BY

Laux

HOSPITAL NAME

Round Valley VA

REFERRING VET

Dr. Laux

INVOICE

94526

DATE

12/13/21