

PATIENT

Lily Marchlinski

PRESENTING CLINICAL SIGNS

History: Presented for vomiting several times Over weight Tachycardia (210) Broken tooth
Abnormal PE/Chem/CBC/UA Results: Hct (50.26%), ALP (166), ALT (826), Ca (12)

SPECIES

Feline

ULTRASONOGRAPHIC EXAMINATION OF THE ABDOMEN

Urinary System

The **urinary bladder**, trigone, and pelvic urethra presented normal thicknesses and normal tone. The ureters were not visible which is normal. No uroliths or sediment were visualized and anechoic urine was present. No evidence of inflammatory or neoplastic changes were noted. Ureteral papillae were normal.

BREED

DSH

The **kidneys** revealed largely normal size and structure, corticomedullary definition and ratio (cortex 1/3 of medulla) were essentially maintained with some minor age-related loss of curvilinear patterns regarding the capsule and C/M junction. The cortices presented largely uniform texture with some increased echogenicity expected for his age patient. Medullary structure differed distinctly from that of the cortex and no evidence of pelvic dilation was present. The left kidney measured 4.16 cm. The right kidney measured 4.07 cm.

SEX

Spayed Female

AGE

11 Years

Adrenal Glands

Both **adrenal glands** were visualized and recognized as having normal shape, size, position and echogenicity for this breed. The phrenic vasculature, glandular echogenicity and detail were unremarkable. Capsule, cortex, and medullary definition were normal for this age patient. The right adrenal gland measured 0.47 cm. The left adrenal gland measured 0.43 cm.

WEIGHT

16.7 Lbs.

Spleen

The **spleen** presented a smooth homogeneous parenchyma hyperechoic to liver and renal cortical parenchyma. The capsule was smooth without noticeable expansion or deviation from within the spleen or adjacent pathology. The splenic vasculature demonstrated normal volume without signs of congestion or thrombosis. No sonographic evidence of acute or chronic inflammatory, neoplastic, or infarctual changes were noted.

INTERPRETED BY

Eric Lindquist, DMV,
DABVP, Cert. IVUSS

Liver

The **liver** images submitted revealed subjectively normal liver size, contour, and structure. Parenchymal echogenicity was naturally coarse and hypoechoic to the spleen. Vascular and biliary tracts were of normal volume with no evidence of congestion. The gallbladder presented acceptably thin walls with primarily anechoic content. The cystic and common bile ducts were normal. No pathological hepatic lymphadenopathy was evident. No overt structural evidence of inflammatory, infiltrative or regenerative pathology was evident.

HOSPITAL NAME

West Eugene AH

REFERRING VET

Dr. Larsen

Gastrointestinal

The stomach revealed progressively shadowing material, possible hairball accumulation and/or ingesta, depending on when the patient ate prior to the sonogram.

INVOICE NUMBER

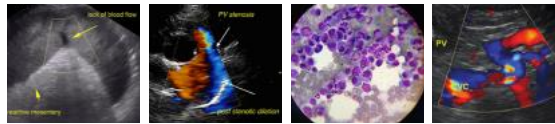
13037

Pancreas

The base and limbs of the **pancreas** were observed to be largely isoechoic to surrounding omental fat. Pancreatic duct and capsular contour were acceptably normal and parenchyma

DATE

12/13/21



PATIENT respected normal curvilinear patterns. No overt evidence of active inflammatory or neoplastic disease was noted.

Lily Marchlinski

ULTRASONOGRAPHIC FINDINGS

SPECIES • Structurally unremarkable abdomen with full stomach (hairball type density)

Feline

INTERPRETATION OF THE FINDINGS & FURTHER RECOMMENDATIONS

No evidence of significant pathology. Hairball therapy warranted, especially if the patient was NPO at the time of the sonogram as well as supportive care.

BREED

DSH

SEX

Spayed Female

AGE

11 Years

WEIGHT

16.7 Lbs.

INTERPRETED BY

Eric Lindquist, DMV,
DABVP, Cert. IVUSS

HOSPITAL NAME

West Eugene AH

REFERRING VET

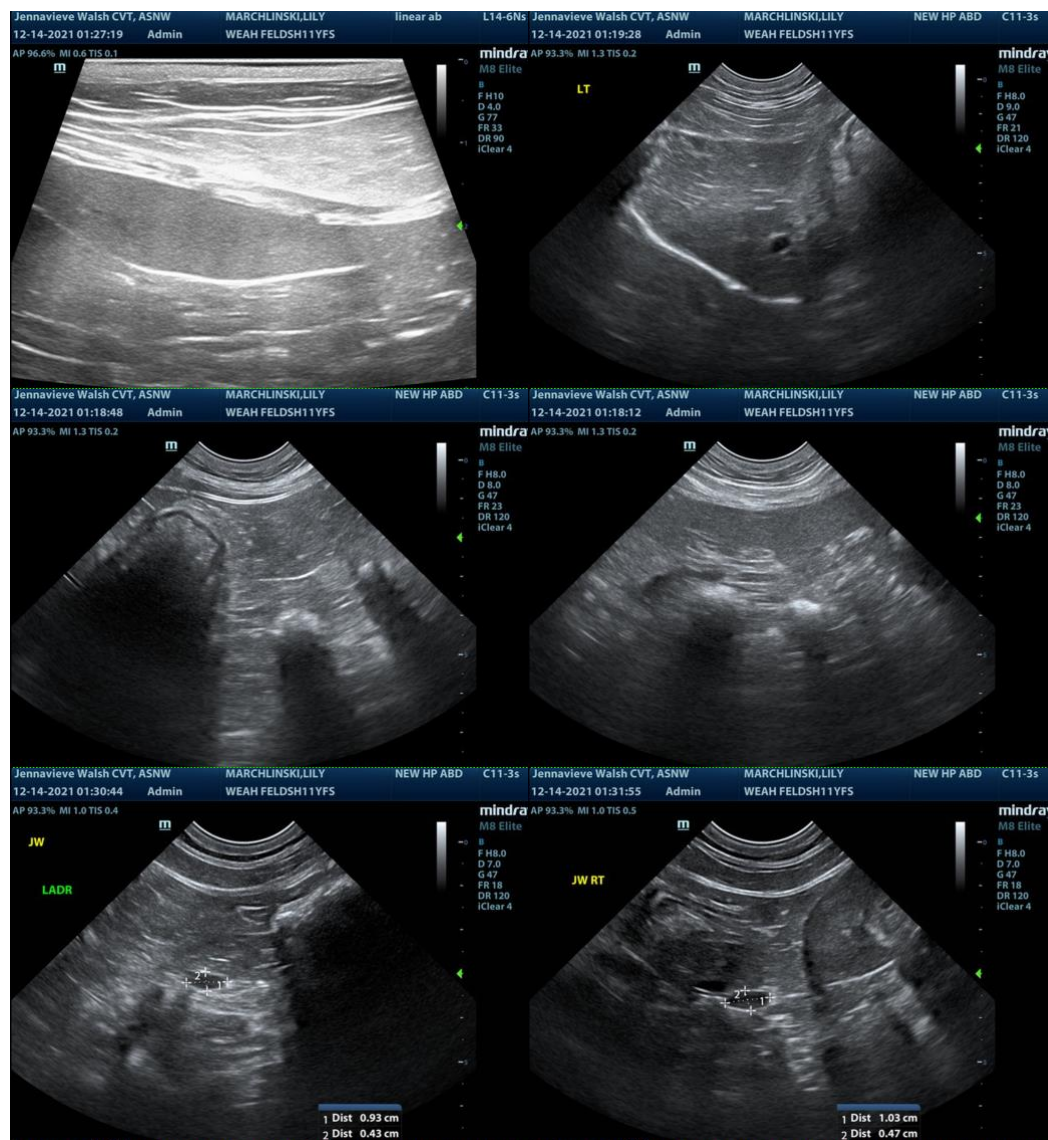
Dr. Larsen

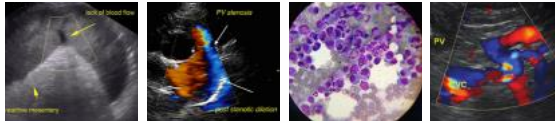
INVOICE NUMBER

13037

DATE

12/13/21





PATIENT

Lily Marchlinski

SPECIES

Feline

BREED

DSH

SEX

Spayed Female

AGE

11 Years

WEIGHT

16.7 Lbs.

INTERPRETED BY

Eric Lindquist, DMV,
DABVP, Cert. IVUSS

HOSPITAL NAME

West Eugene AH

REFERRING VET

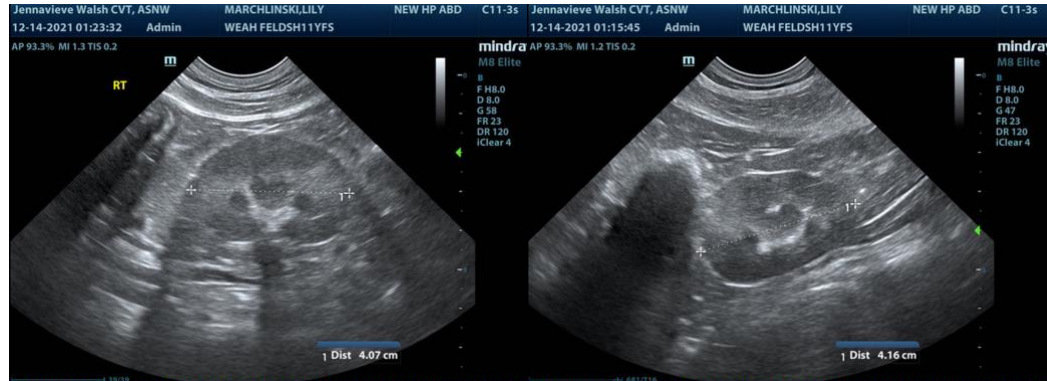
Dr. Larsen

INVOICE NUMBER

13037

DATE

12/13/21



The information and recommendations provided are based on the images presented by the referring veterinarian. No evaluation can be communicated regarding pathology that was not visible in the image/video clips provided.

Thank you for this referral. If the clinical or image interpretation does not parallel your findings or if I can be of any further assistance please contact me.

Eric Lindquist, DMV, DABVP, Cert. IVUSS, CEO of SonoPath.com
Eric.Lindquist@SonoPath.com