



PATIENT

Ginger Aguadro

SPECIES

Canine

BREED

Yorkshire Terrier

SEX

Spayed Female

AGE

8 Years

WEIGHT

9.1 Lbs.

INTERPRETED BY

Eric Lindquist, DMV
DABVP, Cert. IVUSS

IMAGING PERFORMED BY

Kelly Vazquez

HOSPITAL NAME

Ramapo Valley AH

REFERRING VET

Dr. Katara

INVOICE

13041

DATE

12/13/21

PRESENTING CLINICAL SIGNS

History: Chronic, intermittent vomiting of food/bile. Suspect hypomotility/delayed gastric emptying. Want to R/O neoplasia/foreign body/ vs other before starting patient on Reglan. Current med: Maropitant as needed.

Abnormal PE/Chem/CBC/UA Results: CBC/Chem: WNL.

ULTRASONOGRAPHIC EXAMINATION OF THE ABDOMEN

Urinary System

The **urinary bladder**, trigone, and pelvic urethra presented normal thicknesses and normal tone. The ureters were not visible which is normal. No uroliths or sediment were visualized and anechoic urine was present. No evidence of inflammatory or neoplastic changes were noted. Ureteral papillae were normal.

The **kidneys** revealed normal size and structure, corticomedullary definition and ratio for this age. The cortices presented largely uniform texture with normal echogenic relationship to liver and spleen. Medullary structure differed distinctly from the cortex and no evidence of pelvic dilation was present. The capsules were acceptably uniform without significant irregularities. The right kidney measured 3.84 cm. The left kidney measured 3.93 cm.

Adrenal Glands

Both **adrenal glands** were visualized and recognized as having normal shape, size, position and echogenicity for this breed. The phrenic vasculature, glandular echogenicity and detail were unremarkable. Capsule, cortex, and medullary definition were normal for this age patient. The left adrenal gland measured 1.26 cm x 0.41 cm at the caudal pole and 0.32 cm at the cranial pole. The right adrenal gland measured 1.63 cm x 0.38 cm at the caudal pole and 0.74 cm at the cranial pole.

Spleen

The **spleen** presented a smooth homogeneous parenchyma hyperechoic to liver and renal cortical parenchyma. The capsule was smooth without noticeable expansion or deviation from within the spleen or adjacent pathology. The splenic vasculature demonstrated normal volume without signs of congestion or thrombosis. No sonographic evidence of acute or chronic inflammatory, neoplastic, or infarctual changes were noted.

Liver

The **liver** images from right and left intercostal as well as subcostal views revealed subjectively normal liver size, contour, and structure. Some mild age-related parenchymal remodeling was noted but likely not clinically significant at this time. Vascular and biliary tracts were of normal volume and no evidence of congestion was noted. The gallbladder presented some dependent debris with essentially normal contour. The cystic and common bile ducts were normal. No overt evidence of active inflammatory, infiltrative or regenerative pathology was noted but should be paired with current or past LE elevations regarding any clinical significance to this presentation. The hepatic lymph nodes were unremarkable.

Gastrointestinal

The **stomach** revealed mild muscularis hypertrophy. The small intestine and colon were unremarkable.



PATIENT

Ginger Aguadro

SPECIES

Canine

BREED

Yorkshire Terrier

SEX

Spayed Female

AGE

8 Years

WEIGHT

9.1 Lbs.

INTERPRETED BY

Eric Lindquist, DMV
DABVP, Cert. IVUSS

IMAGING PERFORMED BY

Kelly Vazquez

HOSPITAL NAME

Ramapo Valley AH

REFERRING VET

Dr. Katara

INVOICE

13041

DATE

12/13/21

Pancreas

The base and limbs of the **pancreas** were observed to be largely isoechoic to surrounding omental fat. Pancreatic duct and capsular contour were acceptably normal and parenchyma respected normal curvilinear patterns. No overt evidence of active inflammatory or neoplastic disease was noted.

ULTRASONOGRAPHIC FINDINGS

- Age-related abdominal changes with mild pyloric hypertrophy

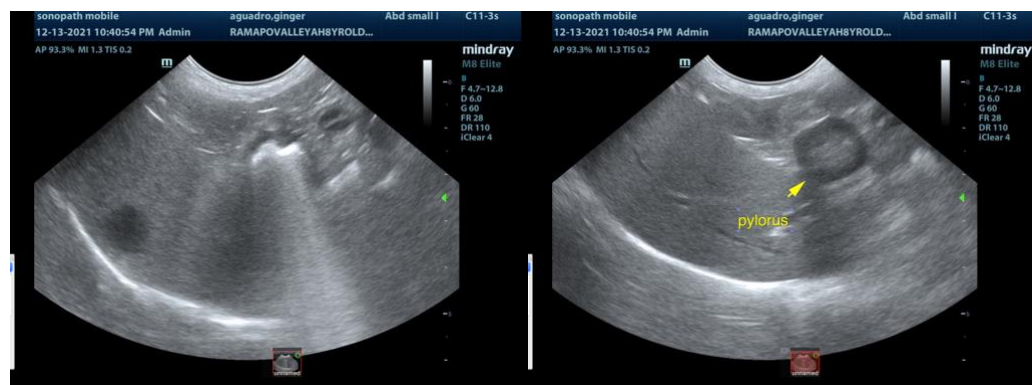
INTERPRETATION OF THE FINDINGS & FURTHER RECOMMENDATIONS

Underlying food intolerance likely playing a primary role in this patient. A clinical trial of the following may prove effective:

Helicobacter/Gastritis protocol

A clinical trial of **Zithromax (Dogs: 5-10 mg/kg p.o. q24h. May increase dosing interval to q48h after 3-5 days of treatment), Metronidazole (10-20 mg/kg p.o. b.i.d.), Pepcid (0.5-1 mg/kg s.i.d.) and Sucralfate (0.5-2 g/dog PO) or Omeprazole (1 mg/kg p.o. s.i.d.)** over the next 3 weeks along with a **novel-protein or hydrolyzed diet** with slurry feeding b.i.d./t.i.d. over the next 2-4 days and then increase to canned diet bid. Dry food should be avoided over the next 4 weeks. A recheck sonogram to assess GI improvement or progression would be ideal in 4 weeks.

Dietary indiscretion, food intolerance, structurally insignificant inflammatory bowel or occult parasitism and occult Addison's are all potentials.





PATIENT

Ginger Aguadro

SPECIES

Canine

BREED

Yorkshire Terrier

SEX

Spayed Female

AGE

8 Years

WEIGHT

9.1 Lbs.

INTERPRETED BY

Eric Lindquist, DMV
DABVP, Cert. IVUSS

IMAGING PERFORMED BY

Kelly Vazquez

HOSPITAL NAME

Ramapo Valley AH

REFERRING VET

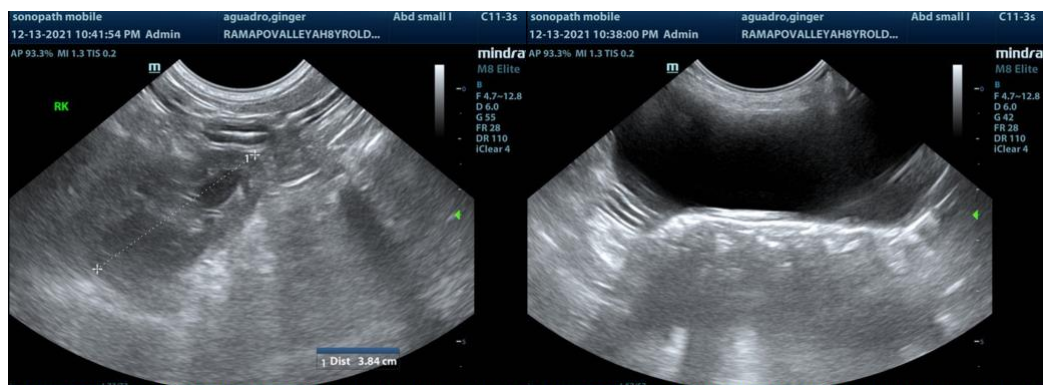
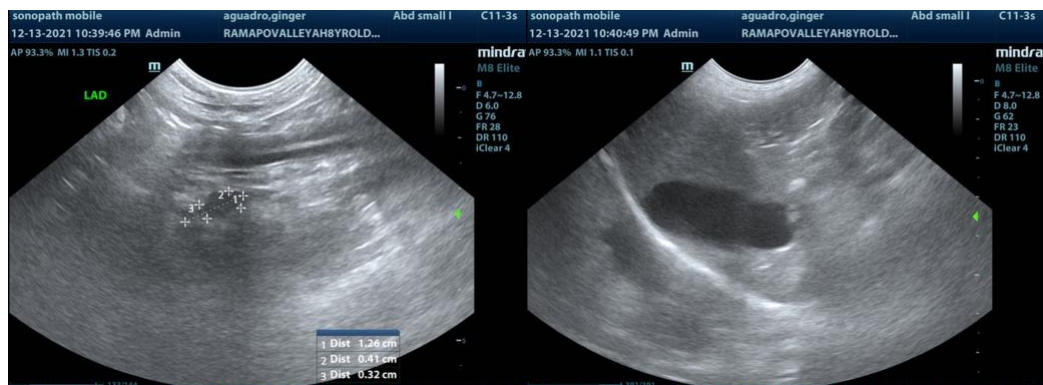
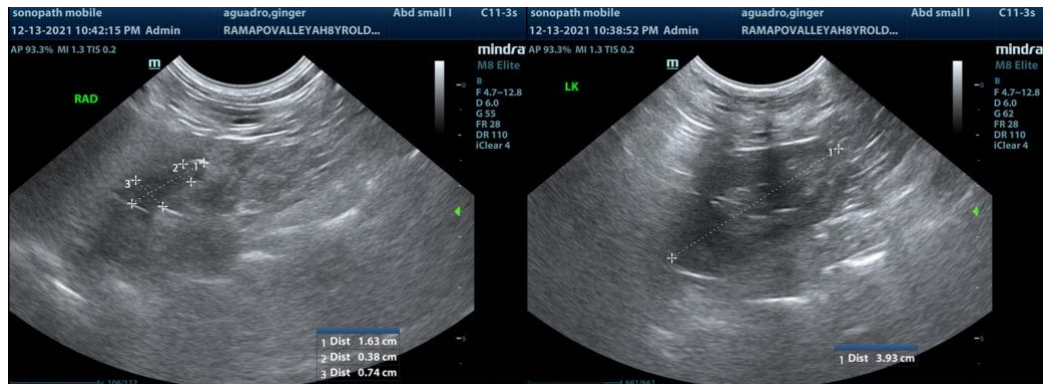
Dr. Katara

INVOICE

13041

DATE

12/13/21



The information and recommendations provided are based on the images presented by the referring veterinarian. No evaluation can be communicated regarding pathology that was not visible in the image/video clips provided.

Thank you for this referral. If the clinical or image interpretation does not parallel your findings or if I can be of any further assistance please contact me.

Eric Lindquist, DMV, DABVP, Cert. IVUSS, CEO of SonoPath.com
info@SonoPath.com