



## PATIENT

Faith Militello

## SPECIES

Canine

## BREED

Pug

## SEX

Spayed Female

## AGE

6

## WEIGHT

10.6

## INTERPRETED BY

Eric Lindquist, DMV,  
DABVP (CFM), Cert.  
IVUSS

## IMAGING PERFORMED BY

Kari Lemanski, DVM

## HOSPITAL NAME

Animal Emergency  
Hospital Deland

## REFERRING VET

Kari Lemanski, DVM

## INVOICE

72544

## DATE

12/12/25

## PRESENTING CLINICAL SIGNS

Faith is a 6 YO FS Pug who was presented for abdominal ultrasound. P was diagnosed with elevated liver and glucose values by pDVM and it was recommended she come here for additional imaging. P was seen on 12/11 for increased urination and drinking. O also noted weight loss. The bloodwork was completed and returned today. The results showed elevated liver, elevated glucose, as well as glucose and ketones in the urine. No bacteria noted in urine and 4DX negative x4.

Abnormal PE/Chem/CBC/UA Results: rDVM records 12/12: ALT- 272. ALP- 560. Sodium- 137. Chloride- 96. Cholesterol- 399. Triglycerides- 1378. PrecisionPSL- 144

## ULTRASONOGRAPHIC EXAMINATION OF THE ABDOMEN

### Urinary System

The **urinary bladder**, trigone, and pelvic urethra presented normal thicknesses and normal tone. The ureters were not visible which is normal. No uroliths or sediment were visualized and anechoic urine was present. No evidence of inflammatory or neoplastic changes were noted. Ureteral papillae were normal.

The **kidneys** were normal in size and contour; however, a minor hyperechoic ring was noted at the corticomedullary junction. This is consistent with diabetic nephropathy. This is likely from glucosuria. However, assessment for proteinuria is also warranted. This is an idiopathic finding, but an expected finding in diabetic patients. Slight pinpoint mineralizations noted in both kidneys. Left kidney measured 4.7 cm. Right kidney measured 4.6 cm.

### Adrenal Glands

The **adrenal glands** were not visualized.

### Spleen

The **spleen** was mildly heterogeneous with occasional hyperechoic lipid plaque noted. Parenchyma was uniform.

### Liver

The **liver** presented generalized enlargement and heterogeneous parenchymal changes. The gallbladder was mildly overdistended with slight suspended bile.

### Gastrointestinal

Examination of the **gastrointestinal tract** revealed a stomach and intestine free of stasis, of normal wall thickness, acceptable curvilinear mural detail, and peristaltic activity. Small and large intestine demonstrated normal luminal chyme and stool consistency respectively. No obstructive or overt infiltrative disease was noted. No associated abnormal lymphatic activity was noted.

### Pancreas

The **pancreas** was hypoechoic and irregular with mild enhanced surrounding mesentery.



## PATIENT

Faith Militello

## SPECIES

Canine

## BREED

Pug

## SEX

Spayed Female

## AGE

6

## WEIGHT

10.6

## INTERPRETED BY

Eric Lindquist, DMV,  
DABVP (CFM), Cert.  
IVUSS

## IMAGING PERFORMED BY

Kari Lemanski, DVM

## HOSPITAL NAME

Animal Emergency  
Hospital Deland

## REFERRING VET

Kari Lemanski, DVM

## INVOICE

72544

## DATE

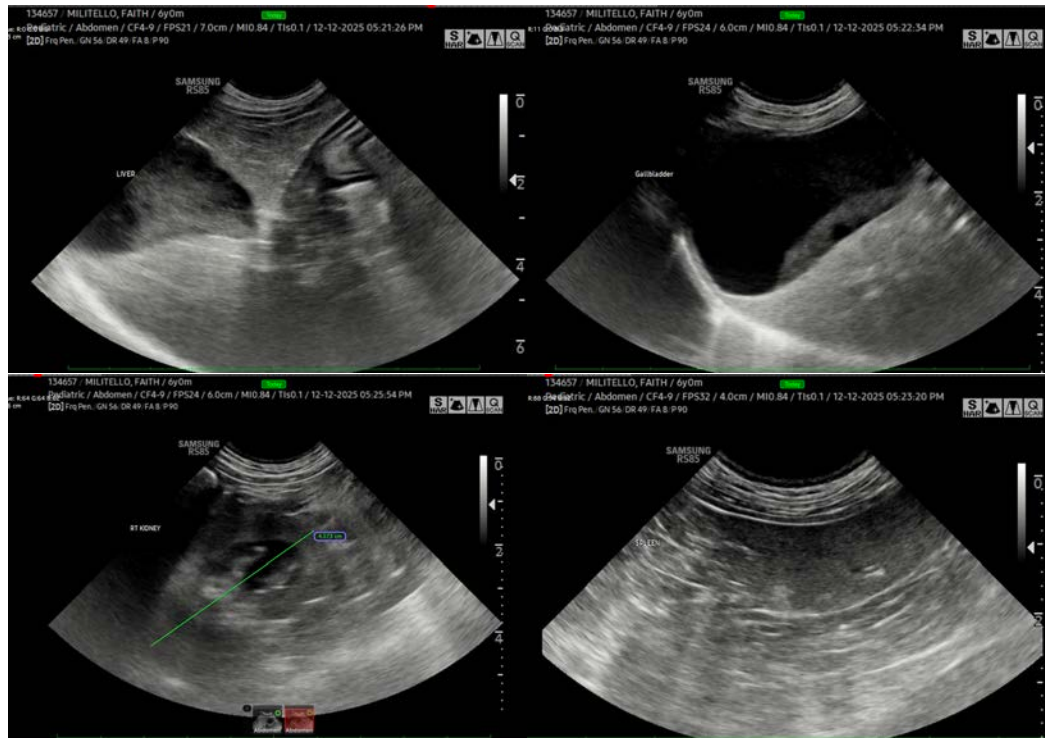
12/12/25

## ULTRASONOGRAPHIC FINDINGS

- Hepatic remodeling, no evidence of neoplasia.
- Low-grade pancreatitis suspected.
- Diabetic nephropathy.
- Heterogeneous spleen.

## INTERPRETATION OF THE FINDINGS & FURTHER RECOMMENDATIONS

Supportive care should prove effective in this patient.





## PATIENT

Faith Militello

## SPECIES

Canine

## BREED

Pug

## SEX

Spayed Female

## AGE

6

## WEIGHT

10.6

## INTERPRETED BY

Eric Lindquist, DMV,  
DABVP (CFM), Cert.  
IVUSS

## IMAGING PERFORMED BY

Kari Lemanski, DVM

## HOSPITAL NAME

Animal Emergency  
Hospital Deland

## REFERRING VET

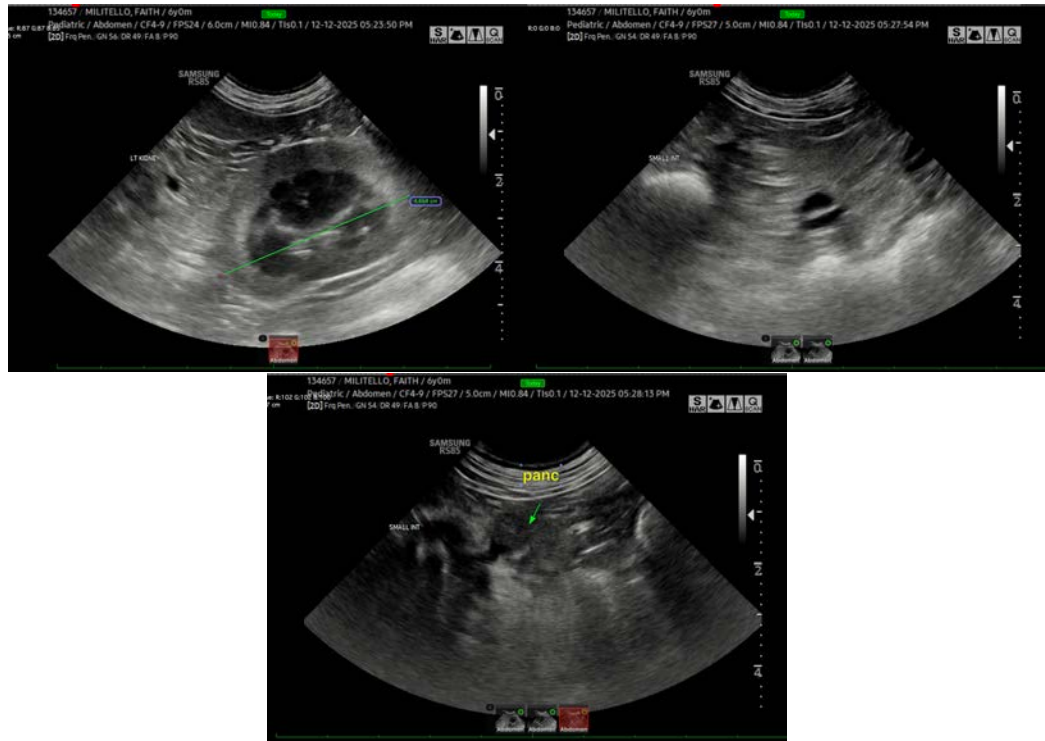
Kari Lemanski, DVM

## INVOICE

72544

## DATE

12/12/25



The information and recommendations provided are based on the images presented by the referring veterinarian/sonographer. No evaluation can be communicated regarding pathology that was not visible in the image/video clips provided.

Thank you for this referral. If the clinical or image interpretation does not parallel your findings or if I can be of any further assistance please contact me.

**Eric Lindquist, DMV, DABVP(CFM), Cert. IVUSS,**  
CEO, Owner, Founder -- SonoPath.com  
[info@SonoPath.com](mailto:info@SonoPath.com)