



PATIENT

Elmer Kinsley

SPECIES

Feline

BREED

Domestic Shorthair

SEX

Neutered male

AGE

3 years

WEIGHT

12.3 lbs

INTERPRETED BY

Eric Lindquist, DMV
DABVP, Cert. IVUSS

IMAGING PERFORMED BY

Heather

HOSPITAL NAME

Animal Care Center of
Flanders

REFERRING VET

Dr. Hallihan

INVOICE

69584

DATE

12/11/25

PRESENTING CLINICAL SIGNS

History: recheck - has history of left ventricular hypertrophy and mitral valve dysplasia has torb sensitivity so gabapentin only for scan heart murmur 4-5/6 medications : Lasix 12.5mg - 1/2 tab SID , Amitriptyline 10mg 1 tab sid, plavix 75mg 1/4 tab sid, atenolol 25mg sid, enalapril 2.5mg 1/2 sid , gabapentin 100mg prn for vet visits
Abnormal PE/Chem/CBC/UA Results: bloodwork sent out today- pending

ULTRASONOGRAPHIC EXAMINATION OF THE HEART

The left atrium was significantly enlarged. Mitral insufficiency was noted in this patient. Concentric left ventricular hypertrophy was noted. The right atrium and right ventricle were unremarkable. Slight pericardial effusion was noted. Minor B lines were noted.

FELINE CARDIAC PARAMETERS	BODY WEIGHT	HR (BPM)	IVSd (cm)	LVIDd (cm)	LVWd (cm)	FS (%)	EF (%)
NORMAL PARAMETER	-----	150-240	0.3-0.6	1.0-2.1	0.25-0.6	35-67	80-100
PATIENT	12.3 lbs	130	0.7	1.5	0.75	50	
FELINE CARDIAC PARAMETERS	LA/AO (M-mode)	LA/AO HEART BASE (Sisson)	LAD LA MAX 4 Chamber		LVOT VEL. (m/s)	RVOT VEL. (m/s)	IVRT (m)
NORMAL PARAMETER	<1.5	1.6	0.7-1.7		<1.6	<1.3	40-60
PATIENT	>2.0	2.5	>2.0				NM
Adapted from June Boon, Veterinary Echocardiography, 1998 Sisson D et al. JVIM 1991; 5: 232, Jacobs et al. Am J Vet Res 1985; 46:1705							

ULTRASONOGRAPHIC FINDINGS

Hypertrophic cardiomyopathy with persistent moderate to severe left atrial enlargement.
Trace pericardial effusion.

INTERPRETATION OF THE FINDINGS & FURTHER RECOMMENDATIONS

EKG is indicated. Continuation of Lasix, Plavix, Atenolol and Enalapril are all recommended. If any exercise intolerance is an issue then Pimobendan trial can be considered. If any pulmonary edema is present then increase in the Lasix frequency is indicated. Prognosis long term is guarded.



PATIENT

Elmer Kinsley

SPECIES

Feline

BREED

Domestic Shorthair

SEX

Neutered male

AGE

3 years

WEIGHT

12.3 lbs

INTERPRETED BY

Eric Lindquist, DMV
DABVP, Cert. IVUSS

IMAGING PERFORMED BY

Heather

HOSPITAL NAME

Animal Care Center of
Flanders

REFERRING VET

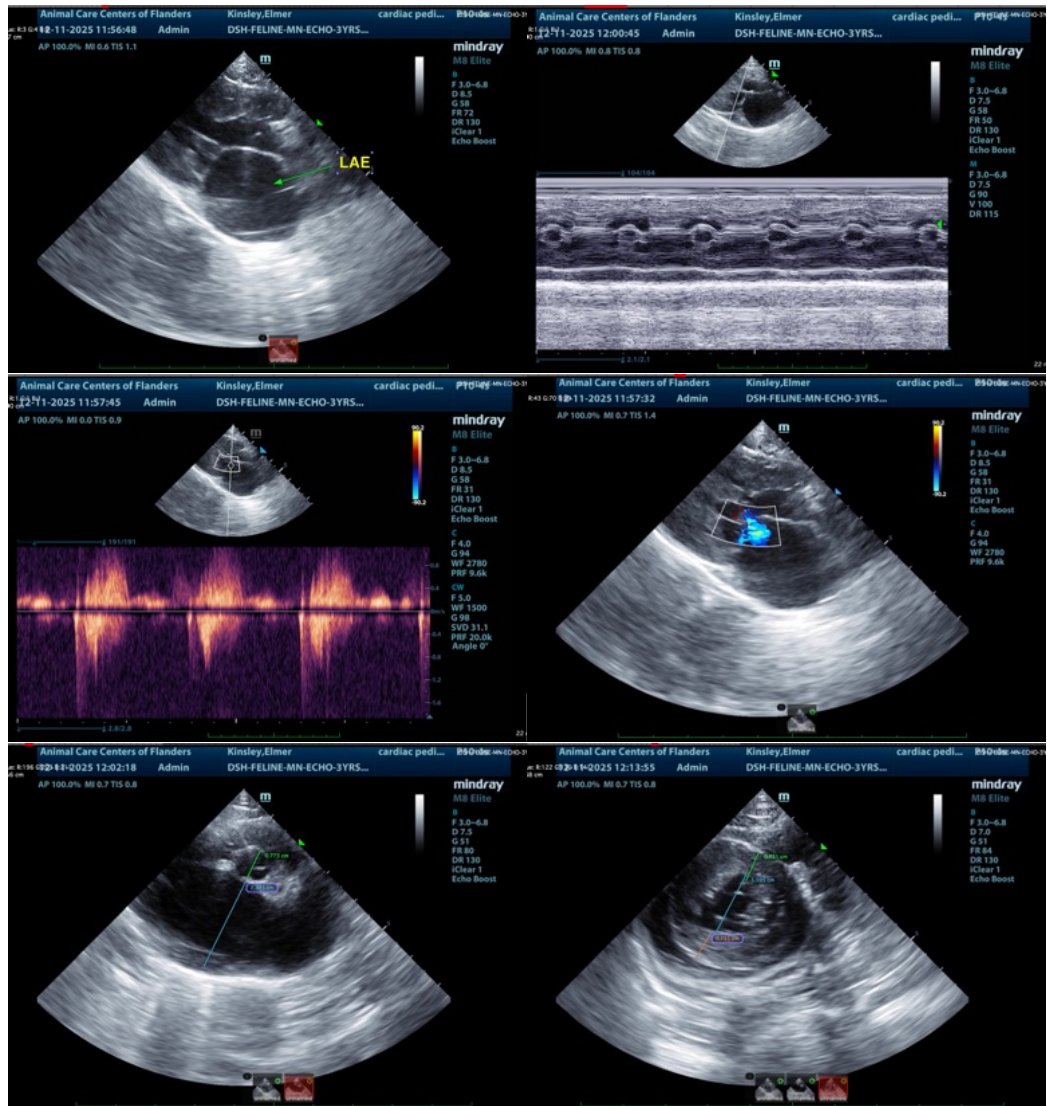
Dr. Hallihan

INVOICE

69584

DATE

12/11/25



The information and recommendations provided are based on the images presented by the referring veterinarian/sonographer. No evaluation can be communicated regarding pathology that was not visible in the image/video clips provided.

Thank you for this referral. If the clinical or image interpretation does not parallel your findings or if I can be of any further assistance please contact me.

Eric Lindquist, DMV, DABVP (CFM), Cert. IVUSS, CEO of SonoPath.com

info@SonoPath.com