



PATIENT

Theo Roldan

SPECIES

Canine

BREED

Papillion

SEX

Male

AGE

10 months

WEIGHT

3.325 lbs

INTERPRETED BY

Eric Lindquist, DMV
DABVP, Cert. IVUSS

IMAGING PERFORMED BY

Arielle Roldan, CVT

HOSPITAL NAME

Milford AH

REFERRING VET

Dr. Grasso

INVOICE

69501

DATE

12/10/25

PRESENTING CLINICAL SIGNS

History: Patient was given up by previous owner due to on going diarrhea issues and continued weight loss. Eats well, active, no vomiting. Suspected liver shunt. Is also cryptorchid
Abnormal PE/Chem/CBC/UA Results: Bile Acids: Pre <1 nl post: 41.0 (0-29.9) bun 40 (7-27) Cortisol NL

ULTRASONOGRAPHIC EXAMINATION OF THE ABDOMEN

Urinary System

The **urinary bladder**, trigone, and pelvic urethra presented normal thicknesses and normal tone. The ureters were not visible which is normal. No uroliths or sediment were visualized and anechoic urine was present. No evidence of inflammatory or neoplastic changes was noted. Ureteral papillae were normal.

The **kidneys** revealed normal size and structure, corticomedullary definition and ratio for this age. The cortices presented largely uniform texture with normal echogenic relationship to liver and spleen. Medullary structure differed distinctly from the cortex and no evidence of pelvic dilation was present. The capsules were acceptably uniform without significant irregularities. The left kidney measured 2.9 cm.

The prostate was uniform and measured 1.0 cm.

Adrenal Glands

The **right adrenal gland** was visualized and recognized as having normal shape, size, position and echogenicity for this breed. The phrenic vasculature, glandular echogenicity and detail were unremarkable. Capsule, cortex, and medullary definition were normal for this age patient. The right adrenal gland measured 0.4 cm. The **region of the left adrenal gland** was unremarkable.

Spleen

The **spleen** presented a smooth homogeneous parenchyma hyperechoic to liver and renal cortical parenchyma. The capsule was smooth without noticeable expansion or deviation from within the spleen or adjacent pathology. The splenic vasculature demonstrated normal volume without signs of congestion or thrombosis. No sonographic evidence of acute or chronic inflammatory, neoplastic, or infarctual changes was noted.

Liver

The **liver** was slightly subnormal in size. Vascular and biliary tracts were of normal volume with no evidence of congestion. The portal vein was visualized with normal termination and volume at 0.32 cm for this size patient. The portal vein to vena cava ratio was 1:1. There was no evidence of macroscopic shunting. Intrahepatic vascular volume appeared adequate. The gallbladder presented acceptably thin



PATIENT

Theo Roldan

walls with primarily anechoic content. The cystic and common bile ducts were normal. No pathological hepatic lymphadenopathy was evident. No overt structural evidence of inflammatory, infiltrative or regenerative pathology was evident.

SPECIES

Canine

Gastrointestinal

BREED

Papillion

Hyperperistalsis was noted in the upper **gastrointestinal tract** with an empty lumen. There was no evidence of mural disease other than minor colonic thickening. The descending colon presented minor wall thickening measuring 0.27 cm. Soft minimal stool was noted. The mesenteric lymph nodes were reactive.

SEX

Male

Pancreas

AGE

10 months

The base and limbs of the **pancreas** were observed to be largely isoechoic to surrounding omental fat. Pancreatic duct and capsular contour were acceptably normal and parenchyma respected normal curvilinear patterns. No overt evidence of active inflammatory or neoplastic disease was noted.

WEIGHT

3.325 lbs

ULTRASONOGRAPHIC FINDINGS

INTERPRETED BY

Eric Lindquist, DMV
DABVP, Cert. IVUSS

Minor microhepatica without macroscopic shunting, yet would necessitate liver biopsy.

Mild gastrointestinal upset, non-specific.

Slight colitis pattern.

Reactive mesenteric lymph nodes.

IMAGING PERFORMED BY

Arielle Roldan, CVT

INTERPRETATION OF THE FINDINGS & FURTHER RECOMMENDATIONS

HOSPITAL NAME

Milford AH

Bile acids may be occurring owing to intestinal dysbiosis given the GI presentation. Parasitic disease, intestinal dysbiosis and dietary intolerance may all be playing a role. Malassimilation of nutrients is likely playing a role in the weight loss. Retained testicle was not visualized in this image set. Screening for Addison's is also indicated.

REFERRING VET

Dr. Grasso

Maldigestion panel, three view chest radiographs and full CNS examination is recommended to examine for occult disease that could be responsible for the weight loss. Evaluation for competitive eating environments should also be considered.

INVOICE

69501

DATE

12/10/25



PATIENT

Theo Roldan

SPECIES

Canine

BREED

Papillion

SEX

Male

AGE

10 months

WEIGHT

3.325 lbs

INTERPRETED BY

Eric Lindquist, DMV
DABVP, Cert. IVUSS

IMAGING PERFORMED BY

Arielle Roldan, CVT

HOSPITAL NAME

Milford AH

REFERRING VET

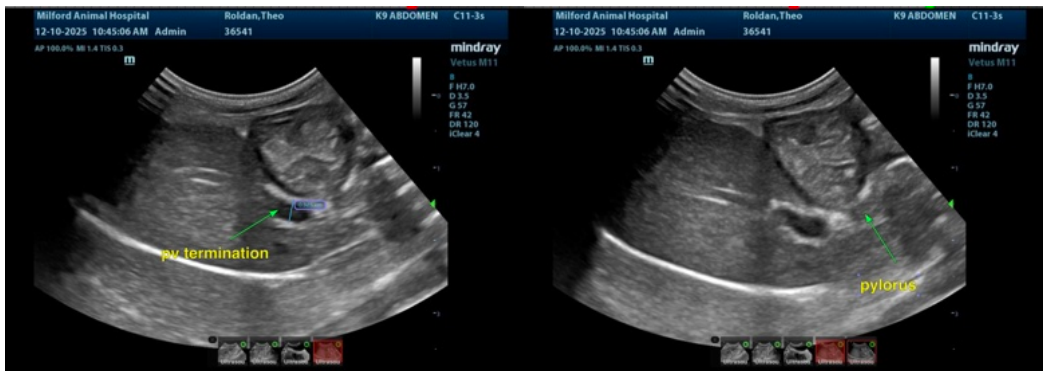
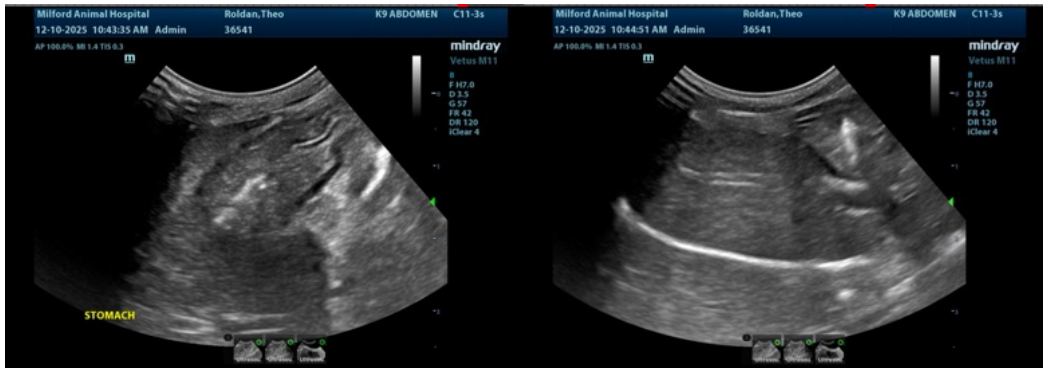
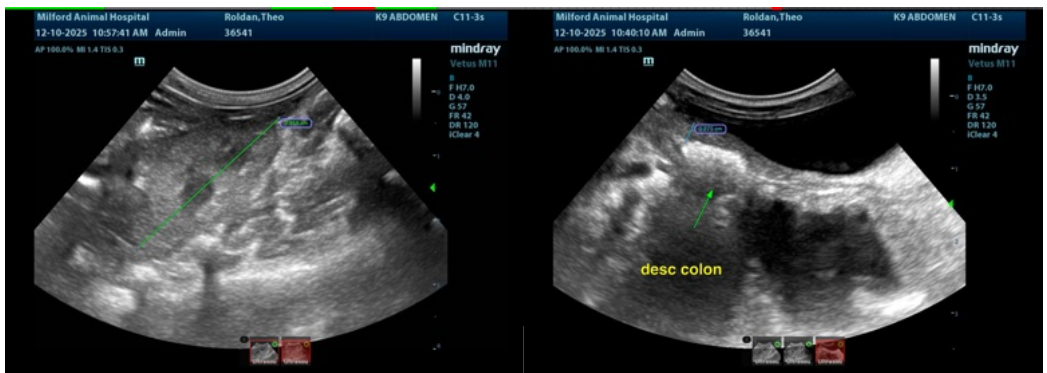
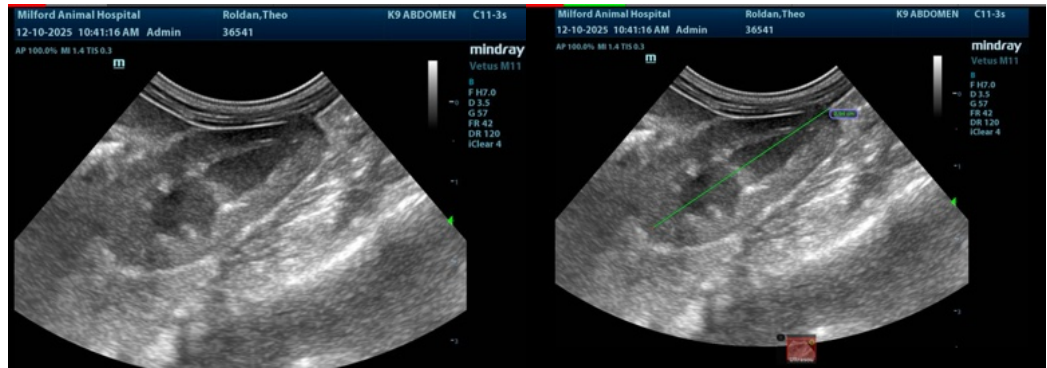
Dr. Grasso

INVOICE

69501

DATE

12/10/25





PATIENT

Theo Roldan

SPECIES

Canine

BREED

Papillion

SEX

Male

AGE

10 months

WEIGHT

3.325 lbs

INTERPRETED BY

Eric Lindquist, DMV
DABVP, Cert. IVUSS

IMAGING PERFORMED BY

Arielle Roldan, CVT

HOSPITAL NAME

Milford AH

REFERRING VET

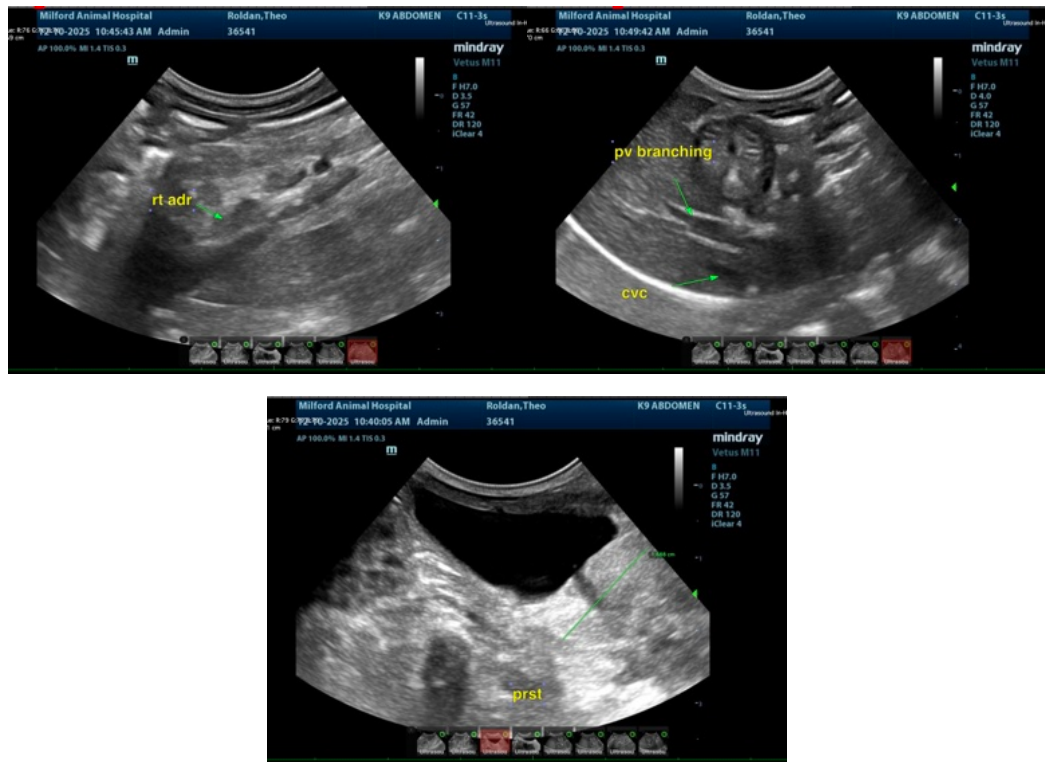
Dr. Grasso

INVOICE

69501

DATE

12/10/25



The information and recommendations provided are based on the images presented by the referring veterinarian/sonographer. No evaluation can be communicated regarding pathology that was not visible in the image/video clips provided.

Thank you for this referral. If the clinical or image interpretation does not parallel your findings or if I can be of any further assistance please contact me.

Eric Lindquist, DMV, DABVP (CFM), Cert. IVUSS, CEO of SonoPath.com

info@SonoPath.com