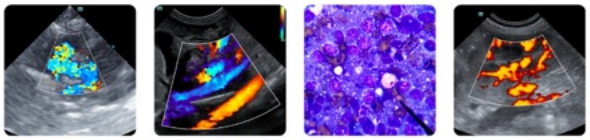

PATIENT
DriftR Johnston

SPECIES
Canine

BREED
Husky Mix

SEX
Neutered male

AGE
10 years

WEIGHT
25.9 kgs

INTERPRETED BY
Eric Lindquist, DMV DABVP, Cert. IVUSS

IMAGING PERFORMED BY
Kim Nystoruk

HOSPITAL NAME
Riverside Small AH

REFERRING VET
Dr. Sarah Pihowich

INVOICE
69519

DATE
12/10/25

PRESENTING CLINICAL SIGNS

History: Has had intermittent vomiting and diarrhea to soft stools for approx 3months. Lost 1kg since July 2025. Has trialed Hypo HP diet, RC fiber response, probiotics and omeprazole 20mg BID - no improvements. Potential Ddx: Chronic pancreatitis, IBD, neoplasia, Pancreatic insufficiency, GERD, anxiety related, hepatopathy
CBC unremarkable Biochem: Mild hypophosphatemia (0.7) - decreased intestinal absorption most likely given v/d, ddx renal Mild elevation in ALT (197) - age related hepatopathy, neoplasia, open -> recommend monitoring for trends Fecal negative 4DX negative T4 WNLs Cortisol - Resting 256.9 nmol/L rules out Addison's Chest/Abd Rads (Nov 5th): 2 view chest appeared clear/naf. Abd rad showed gravel or radio-opaque material. Pending GI panel (TLI, folate, cobalamin, spec cPL) - patient was given oral medication this AM and so were not able to pursue this testing today

ULTRASONOGRAPHIC EXAMINATION OF THE ABDOMEN

Urinary System

The **urinary bladder**, trigone, and pelvic urethra presented normal thicknesses and normal tone. The ureters were not visible which is normal. No uroliths or sediment were visualized and anechoic urine was present. No evidence of inflammatory or neoplastic changes was noted. Ureteral papillae were normal.

The **kidneys** revealed normal size and structure, corticomedullary definition and ratio for this age. The cortices presented largely uniform texture with normal echogenic relationship to liver and spleen. Medullary structure differed distinctly from the cortex and no evidence of pelvic dilation was present. The capsules were acceptably uniform without significant irregularities. The left kidney measured 6.01 cm.

Adrenal Glands

Both **adrenal glands** were visualized and recognized as having normal shape, size, position and echogenicity for this breed. The phrenic vasculature, glandular echogenicity and detail were unremarkable. Capsule, cortex, and medullary definition were normal for this age patient. The left adrenal gland measured 0.62 cm. The right adrenal gland measured 0.57 cm.

Spleen

The **spleen** presented a smooth homogeneous parenchyma hyperechoic to liver and renal cortical parenchyma. The capsule was smooth without noticeable expansion or deviation from within the spleen or adjacent pathology. The splenic vasculature demonstrated normal volume without signs of congestion or thrombosis. No sonographic evidence of acute or chronic inflammatory, neoplastic, or infarctual changes was noted.

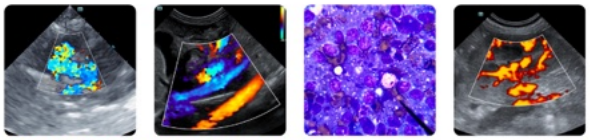

PATIENT

DriftR Johnston

SPECIES

Canine

BREED

Husky Mix

SEX

Neutered male

AGE

10 years

WEIGHT

25.9 kgs

INTERPRETED BY

Eric Lindquist, DMV
DABVP, Cert. IVUSS

IMAGING PERFORMED BY

Kim Nystoruk

HOSPITAL NAME

Riverside Small AH

REFERRING VET

Dr. Sarah Pihowich

INVOICE

69519

DATE

12/10/25

Liver

The **liver** images submitted revealed subjectively normal liver size, contour, and structure. Parenchymal echogenicity was naturally coarse and hypoechoic to the spleen. Vascular and biliary tracts were of normal volume with no evidence of congestion. The gallbladder presented acceptably thin walls with primarily anechoic content. The cystic and common bile ducts were normal. No pathological hepatic lymphadenopathy was evident. No overt structural evidence of inflammatory, infiltrative or regenerative pathology was evident.

Gastrointestinal

Examination of the **gastrointestinal tract** revealed a stomach and intestine free of stasis, of normal wall thickness, acceptable curvilinear mural detail, and peristaltic activity. Small and large intestine demonstrated normal luminal chyme and stool consistency respectively. The mesenteric lymph ndoes were reactive.

Pancreas

Minor heterogenous **pancreatic** changes were noted.

Free Abdomen

The pancreatic lymph node was mildly enlarged and reactive measuring 1.5 x 0.5 cm.

ULTRASONOGRAPHIC FINDINGS

Slight pancreatic lymphadenopathy.

Otherwise, unremarkable abdomen.

INTERPRETATION OF THE FINDINGS & FURTHER RECOMMENDATIONS

Ultrasound-guided FNA, cytology and culture of the accessible lymph nodes are recommended for further definition. There was no evidence of significant structural disease.

SonoPath

FOSTERING THE ART OF VETERINARY MEDICINE™

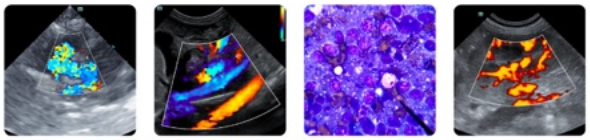

Clinical Sonography & Telecytology

Educational Teleconsultation Services™

SonoPath.com info@sonopath.com 1.800.838.4268

PATIENT

DriftR Johnston

SPECIES

Canine

BREED

Husky Mix

SEX

Neutered male

AGE

10 years

WEIGHT

25.9 kgs

INTERPRETED BY

Eric Lindquist, DMV
DABVP, Cert. IVUSS

IMAGING PERFORMED BY

Kim Nystoruk

HOSPITAL NAME

Riverside Small AH

REFERRING VET

Dr. Sarah Pihowich

INVOICE

69519

DATE

12/10/25

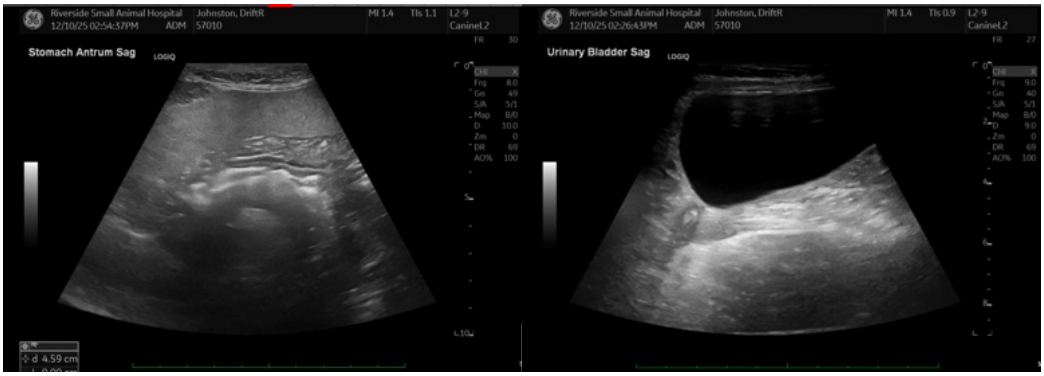

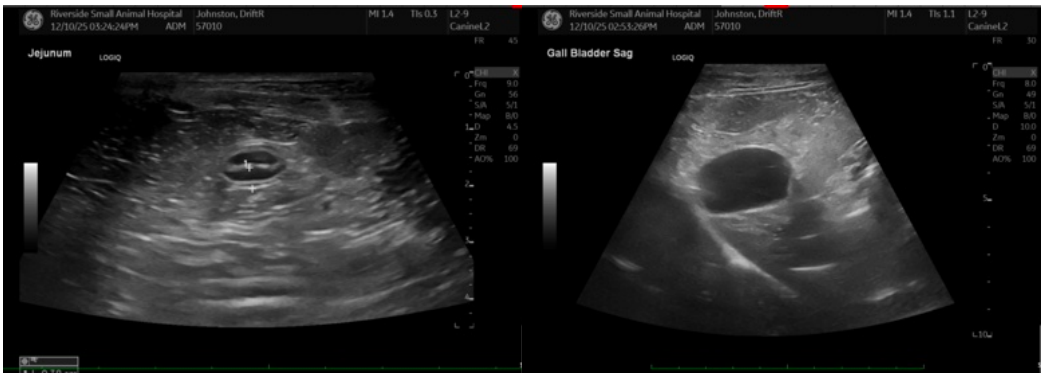

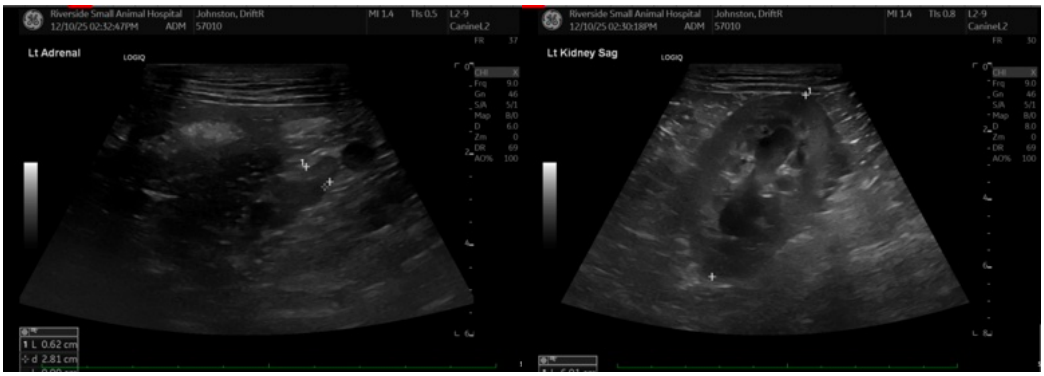

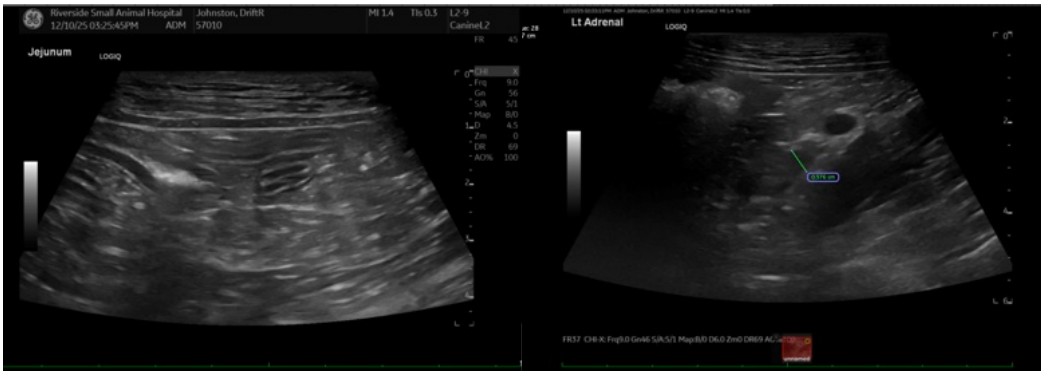

SonoPath
FOSTERING THE ART OF VETERINARY MEDICINE™

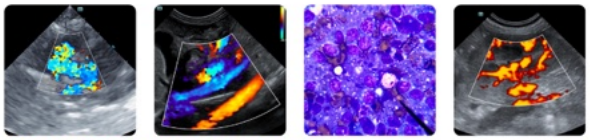

Clinical Sonography & Telecytology
Educational Teleconsultation Services™

SonoPath.com info@sonopath.com 1.800.838.4268

PATIENT

DriftR Johnston

SPECIES

Canine

BREED

Husky Mix

SEX

Neutered male

AGE

10 years

WEIGHT

25.9 kgs

INTERPRETED BY

Eric Lindquist, DMV
DABVP, Cert. IVUSS

IMAGING PERFORMED BY

Kim Nystoruk

HOSPITAL NAME

Riverside Small AH

REFERRING VET

Dr. Sarah Pihowich

INVOICE

69519

DATE

12/10/25

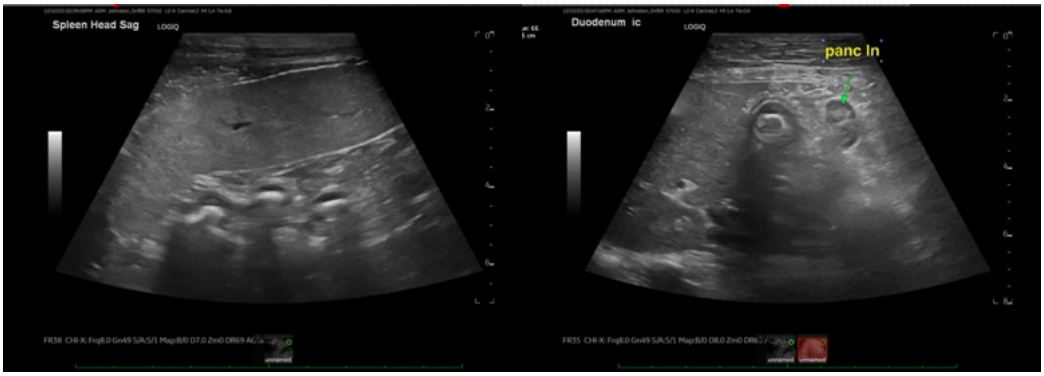

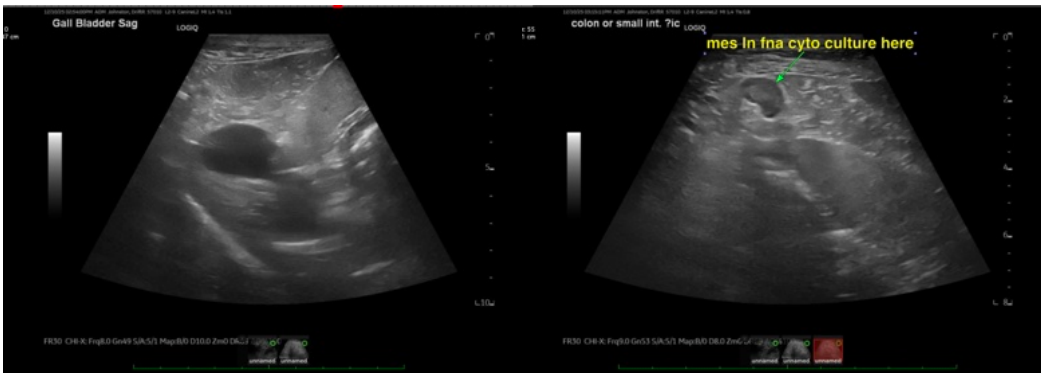

The information and recommendations provided are based on the images presented by the referring veterinarian/sonographer. No evaluation can be communicated regarding pathology that was not visible in the image/video clips provided.

Thank you for this referral. If the clinical or image interpretation does not parallel your findings or if I can be of any further assistance please contact me.

Eric Lindquist, DMV, DABVP (CFM), Cert. IVUSS, CEO of SonoPath.com

info@SonoPath.com