



## PATIENT

Cali Watson

## SPECIES

Canine

## BREED

Pit Bull

## SEX

Spayed Female

## AGE

11 Years

## WEIGHT

65 lbs

## INTERPRETED BY

Eric Lindquist, DMV,  
DABVP (CFM), Cert.  
IVUSS

## IMAGING PERFORMED BY

Dr. Brandon Holmes

## HOSPITAL NAME

West Newton Animal  
Clinic

## REFERRING VET

Dr. Brandon Holmes

## INVOICE

72492

## DATE

12/10/25

## PRESENTING CLINICAL SIGNS

Grade 3/ 6 murmur audible on yearly exam on 12/4/2025. History of intermittent cough and decreased energy.

Abnormal PE/Chem/CBC/UA Results: Lymphocytes = 935, eosinophils = 90

## ULTRASONOGRAPHIC EXAMINATION OF THE HEART & ABDOMEN

CANINE CARDIAC PARAMETERS	MR VMAX (m/s)	TR VMAX (m/s)	LA/AO (M-Mode)	LA/AO (Heart Base; Swe)	FS (%)	EF (%)	EPSS (cm)
NORMAL PARAMETER	4.5-5.5	<2.7	1.3	Up to 1.6	28-40	40-100	<0.6
PATIENT	--	--	1.2	1.4	45	--	0.1
CANINE CARDIAC PARAMETERS	HR (BPM)	AV VMAX (m/s)	PV MAX (m/s)	BODY WEIGHT (lbs)	LAD LA MAX 4 Chamber	LVIDd Avg; 2D and m-mode short axis (cm)	LVIDs Avg; 2D and m-mode short axis (cm)
NORMAL PARAMETER	50-100	0.7-1.7	0.7-1.6				
PATIENT	--	1.3	0.6	65	3.8	3.7	--

### Cardiac Presentation

The echocardiogram in this patient demonstrated normal **left atrial** size based on 3 separate methods of LA evaluation. Minor **mitral** insufficiency noted with eccentric and minor jet. The **left ventricle** presented thicknesses with linear contour and was not dilated nor restricted. The **myocardium** presented normal echogenicity without subjective evidence of significant fibrotic or ischemic disease. **Contractility** of the ventricular walls was adequate and in normal range for this patient evidenced by the fractional shortening measurement and subjective evaluation of the different regions of the myocardium. The **left ventricular outflow** tract demonstrated normal laminar flow and subjective structural integrity. The **right atrium** and auricle revealed normal size, structure and content. No evidence of masses was noted. **Tricuspid** valvular assessment demonstrated adequate linear morphology and kinesis. The **right ventricle** was of normal size (1/3 diameter of LV), chordae structure, myocardial echogenicity and thickness. **Pulmonary outflow** tract assessment revealed normal valve structure, laminar flow, and diameter (approx. 1:1 pa/ao ratio). No visible **pericardial** or free pleura fluid was noted. The cranial **mediastinum and pericardial and extra-cardiac regions** were free of masses in the visible window.

### Urinary System

The **urinary bladder**, trigone, and pelvic urethra presented normal thicknesses and normal tone. The ureters were not visible which is normal. No uroliths or sediment were visualized and anechoic urine was present. No evidence of inflammatory or neoplastic changes were noted. Ureteral papillae were normal. The pelvic urethra was imaged 2.0 cm beyond the cystourethral junction.



## PATIENT

Cali Watson

## SPECIES

Canine

## BREED

Pit Bull

## SEX

Spayed Female

## AGE

11 Years

## WEIGHT

65 lbs

## INTERPRETED BY

Eric Lindquist, DMV,  
DABVP (CFM), Cert.  
IVUSS

## IMAGING PERFORMED BY

Dr. Brandon Holmes

## HOSPITAL NAME

West Newton Animal  
Clinic

## REFERRING VET

Dr. Brandon Holmes

## INVOICE

72492

## DATE

12/10/25

The **kidneys** revealed largely normal size and structure, corticomedullary definition and ratio (cortex 1/3 of medulla) were essentially maintained with some age-related loss of curvilinear patterns regarding the capsule and C/M junction. The cortices presented largely uniform texture with some increased echogenicity expected for his age patient. Medullary structure differed distinctly from that of the cortex and no evidence of pelvic dilation was present. Left kidney measured 5.56 cm. Right kidney measured 6.0 cm.

### **Adrenal Glands**

Both **adrenal glands** were visualized and recognized as having normal shape, size, position and echogenicity for this breed. The phrenic vasculature, glandular echogenicity and detail were unremarkable. Capsule, cortex, and medullary definition were normal for this age patient. Left measured 1.94 cm x 0.50 cm at the caudal pole and 0.80 cm at the cranial pole. Right measured 0.80 cm at the cranial pole and 0.90 cm at the caudal pole.

### **Spleen**

The **spleen** presented a smooth homogeneous parenchyma hyperechoic to liver and renal cortical parenchyma. The capsule was smooth without noticeable expansion or deviation from within the spleen or adjacent pathology. The splenic vasculature demonstrated normal volume without signs of congestion or thrombosis. No sonographic evidence of acute or chronic inflammatory, neoplastic, or infarctual changes were noted.

### **Liver**

The **liver** images submitted revealed subjectively normal liver size, contour, and structure. Parenchymal echogenicity was naturally coarse and hypoechoic to the spleen. Vascular and biliary tracts were of normal volume with no evidence of congestion. The gallbladder presented acceptably thin walls with primarily anechoic content. The cystic and common bile ducts were normal. No pathological hepatic lymphadenopathy was evident. No overt structural evidence of inflammatory, infiltrative or regenerative pathology was evident.

### **Gastrointestinal**

Examination of the **gastrointestinal tract** revealed a stomach and intestine free of stasis, of normal wall thickness, acceptable curvilinear mural detail, and peristaltic activity. Small and large intestine demonstrated normal luminal chyme and stool consistency respectively. No obstructive or overt infiltrative disease was noted. No associated abnormal lymphatic activity was noted.

### **Pancreas**

The base and limbs of the **pancreas** were observed to be largely isoechoic to surrounding omental fat. Pancreatic duct and capsular contour were acceptably normal and parenchyma respected normal curvilinear patterns. No overt evidence of active inflammatory or neoplastic disease was noted.

## ULTRASONOGRAPHIC FINDINGS

- Minor mitral insufficiency, Stage B1 valvular disease.
- Structurally unremarkable abdomen, no evidence of pathology.



**PATIENT**

Cali Watson

**SPECIES**

Canine

**BREED**

Pit Bull

**SEX**

Spayed Female

**AGE**

11 Years

**WEIGHT**

65 lbs

**INTERPRETED BY**

Eric Lindquist, DMV,  
DABVP (CFM), Cert.  
IVUSS

**IMAGING PERFORMED BY**

Dr. Brandon Holmes

**HOSPITAL NAME**

West Newton Animal  
Clinic

**REFERRING VET**

Dr. Brandon Holmes

**INVOICE**

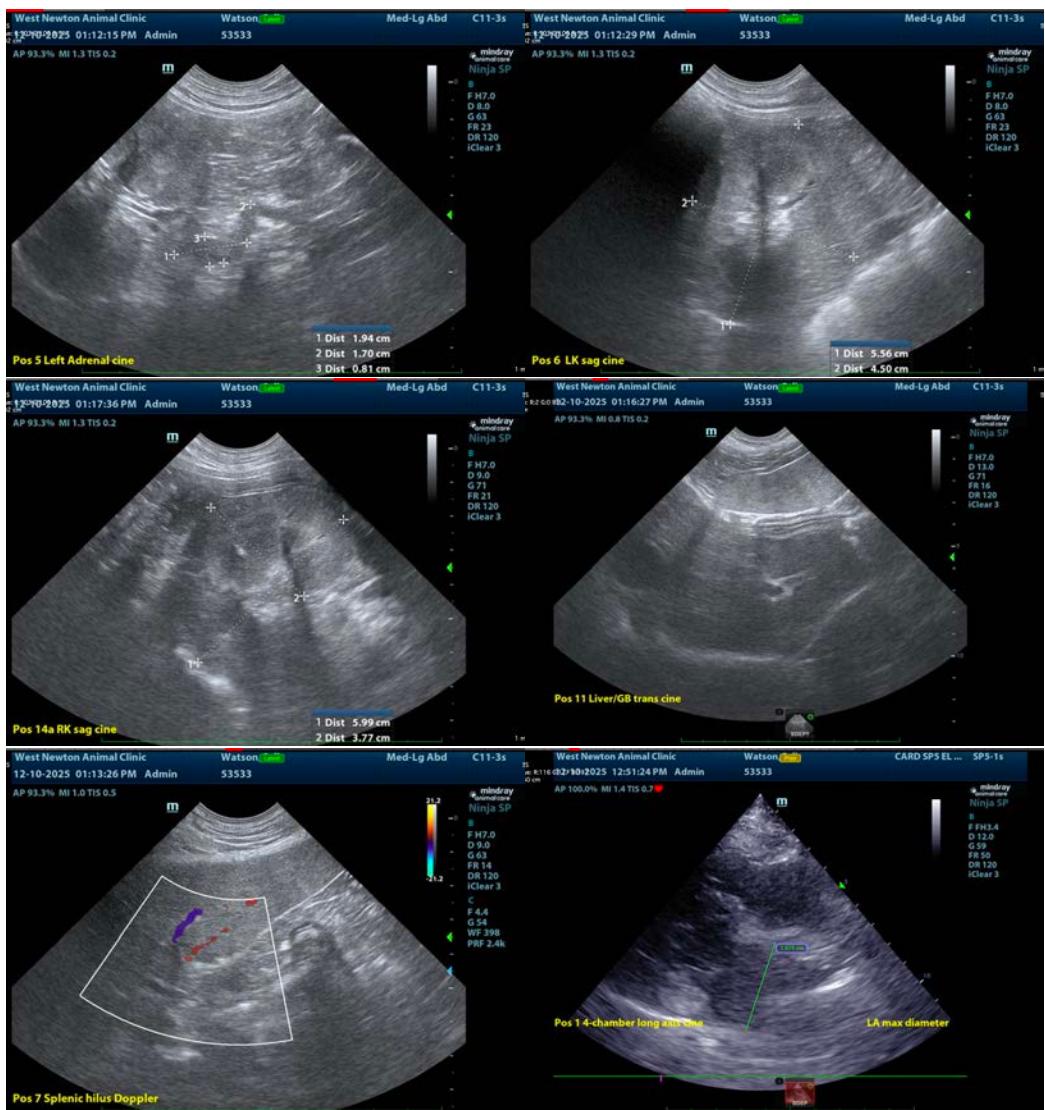
72492

**DATE**

12/10/25

**INTERPRETATION OF THE FINDINGS & FURTHER RECOMMENDATIONS**

The heart is stable without clinical disease. No overt contraindication for anesthesia of brief to moderate duration. I suggest Torbutrol premed, Propofol induction, Isoflo maintenance or similar protocol if anesthesia is desired. Blood pressure, EKG and chest radiographs are recommended if not already performed. Target white coat negative systolic pressure of < 160 mmHg. If higher than this ACE-inhibitor is suggested to reach this level. Recheck echocardiogram is recommended in 6 months, earlier if murmur grade increases or clinical signs initiate.





**PATIENT**

Cali Watson

**SPECIES**

Canine

**BREED**

Pit Bull

**SEX**

Spayed Female

**AGE**

11 Years

**WEIGHT**

65 lbs

**INTERPRETED BY**

Eric Lindquist, DMV,  
DABVP (CFM), Cert.  
IVUSS

**IMAGING  
PERFORMED BY**

Dr. Brandon Holmes

**HOSPITAL NAME**

West Newton Animal  
Clinic

**REFERRING VET**

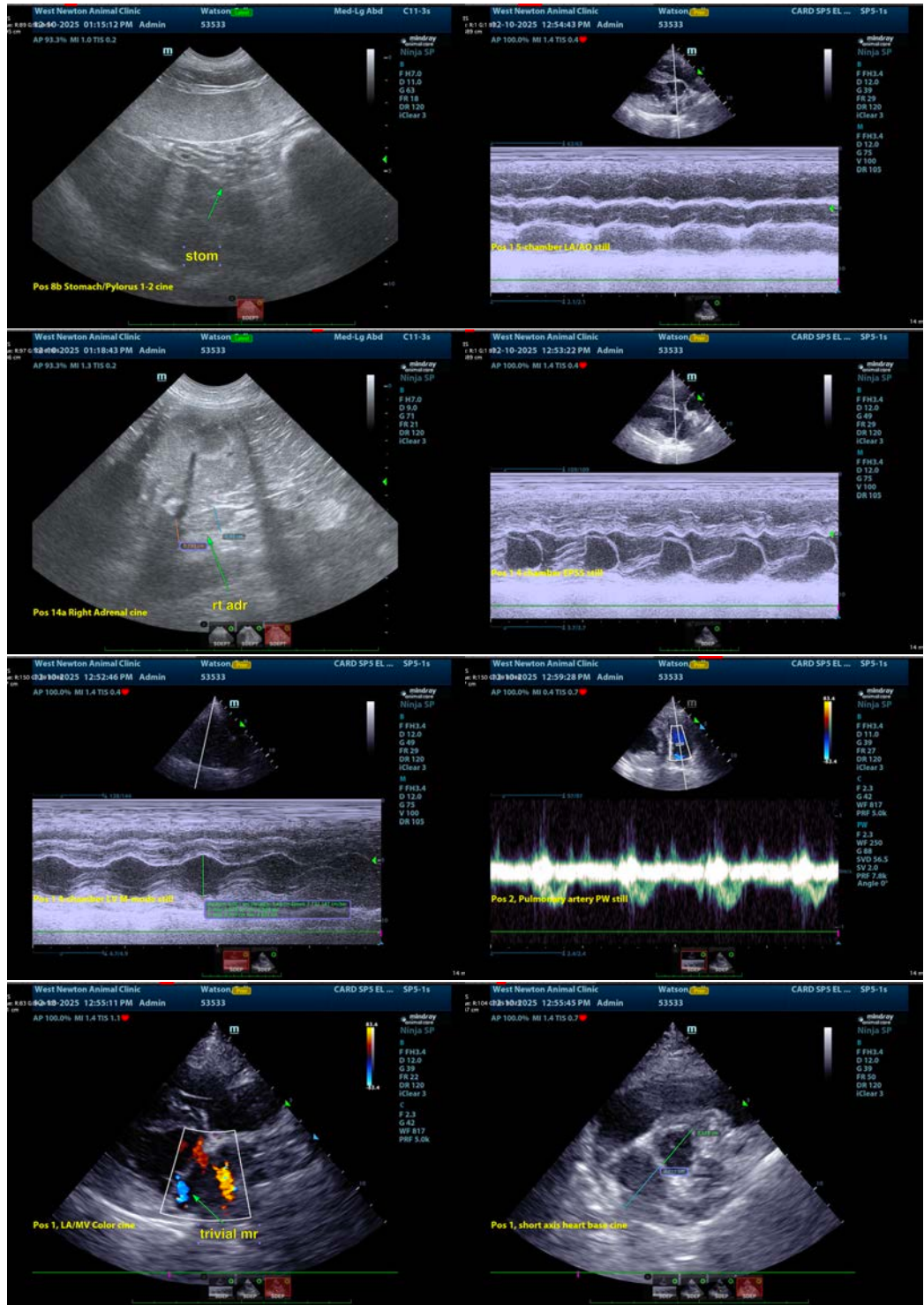
Dr. Brandon Holmes

**INVOICE**

72492

**DATE**

12/10/25





## PATIENT

Cali Watson

## SPECIES

Canine

## BREED

Pit Bull

## SEX

Spayed Female

## AGE

11 Years

## WEIGHT

65 lbs

## INTERPRETED BY

Eric Lindquist, DMV,  
DABVP (CFM), Cert.  
IVUSS

## IMAGING PERFORMED BY

Dr. Brandon Holmes

## HOSPITAL NAME

West Newton Animal  
Clinic

## REFERRING VET

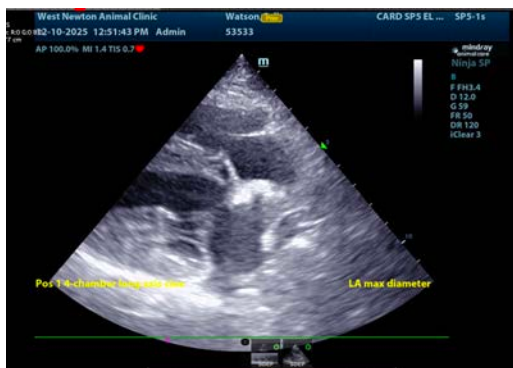
Dr. Brandon Holmes

## INVOICE

72492

## DATE

12/10/25



The information and recommendations provided are based on the images presented by the referring veterinarian/sonographer. No evaluation can be communicated regarding pathology that was not visible in the image/video clips provided.

Thank you for this referral. If the clinical or image interpretation does not parallel your findings or if I can be of any further assistance please contact me.

**Eric Lindquist**, DMV, DABVP(CFM), Cert. IVUSS,  
CEO, Owner, Founder -- SonoPath.com  
[info@SonoPath.com](mailto:info@SonoPath.com)