

**DATE PRESENTING CLINICAL SIGNS**

12-10-21 History: mild PU/PD otherwise p appears clinically normal
 noted elevated ALT and ALP on Pre-op BW. Have been giving Denamarin and monitoring slow increase in ALT, ALP always high.

PATIENT

Sadie Ryland

SPECIES

Canine

BREED

Beagle Mixed Breed

SEX

Spayed Female

AGE

8/20/10

WEIGHT

72.4 Lbs.

INTERPRETED BYEric Lindquist, DMV
DABVP, Cert. IVUSS**IMAGING PERFORMED BY**

Rachel Brillhart RDMS

HOSPITAL NAME

Northwind AH

REFERRING VET

Dr. Repsher

INVOICE

13008

Current Medications: Levothyroxine 0.3 mg tab - 2am and 1 pm chronically.
 Lab Results: in house 10/1/21: ALP 270; ALP>993. Idexx 10/29/2021: ALT 232; ALP 1405; T4 1.6. In house 12/4:
 ALT 383, ALP >993.
 Date of Previous IntraPet Ultrasound: No previous IntraPet scans.
 Sedation: 0.36 telazol IV.
 Stat Report: Not requested.

ULTRASONOGRAPHIC EXAMINATION OF THE ABDOMEN**Urinary System**

The **urinary bladder**, trigone, and pelvic urethra presented normal thicknesses and normal tone. The ureters were not visible which is normal. No uroliths or sediment were visualized and anechoic urine was present. No evidence of inflammatory or neoplastic changes were noted. Ureteral papillae were normal.

The **kidneys** revealed largely normal size and structure, corticomedullary definition and ratio (cortex 1/3 of medulla) were essentially maintained with some mild age-related loss of curvilinear patterns regarding the capsule and C/M junction. The cortices presented largely uniform texture with some increased echogenicity expected for his age patient. Medullary structure differed distinctly from that of the cortex and no evidence of pelvic dilation was present. The right kidney measured 8.0 cm. The left kidney measured 7.3 cm.

Adrenal Glands

The **right adrenal gland** was visualized and recognized as having normal shape, size, position and echogenicity for this breed. The phrenic vasculature, glandular echogenicity and detail were unremarkable. Capsule, cortex, and medullary definition were normal for this age patient. The right adrenal gland measured 2.82 cm x 0.87 cm at the caudal pole and 0.8 cm at the cranial pole.

The **left adrenal gland** was enlarged, hypoechoic and irregular, measuring 3.3 cm x 1.46 cm at the cranial pole and 1.19 cm at the caudal pole.

Spleen

The **spleen** presented a smooth homogeneous parenchyma hyperechoic to liver and renal cortical parenchyma. The capsule was smooth without noticeable expansion or deviation from within the spleen or adjacent pathology. The splenic vasculature demonstrated normal volume without signs of congestion or thrombosis. No sonographic evidence of acute or chronic inflammatory, neoplastic, or infarctual changes were noted.

Liver

The **liver** revealed generalized enlargement with coarse architecture and was diffusely hyperechoic to falciform fat. The gallbladder was overdistended with echogenic debris.

Gastrointestinal

Examination of the **gastrointestinal tract** revealed a stomach and intestine free of stasis, of normal wall thickness, acceptable curvilinear mural detail, and peristaltic activity. Small and large intestine demonstrated

normal luminal chyme and stool consistency respectively. No obstructive or overt infiltrative disease was noted. No associated abnormal lymphatic activity was noted.

Pancreas

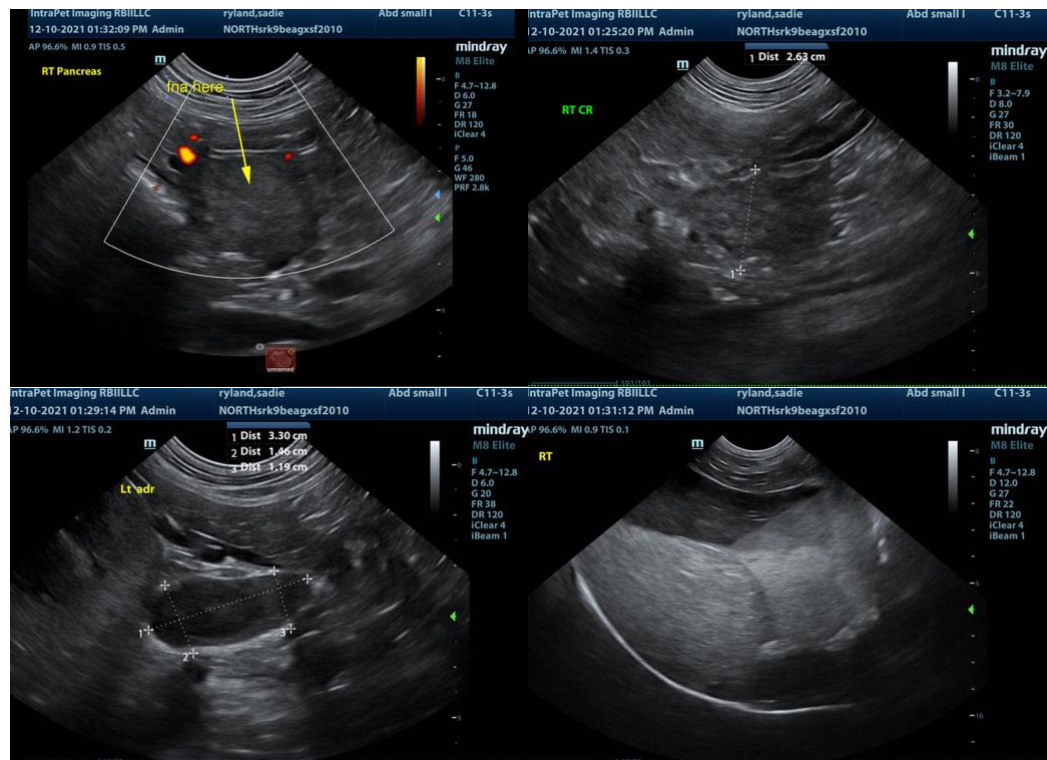
The **pancreas** revealed heterogeneous parenchymal changes with irregular contour. An overt mass was noted, measuring 4.4 cm x 2.4 cm in the right limb. Other nodular changes were noted throughout the pancreas.

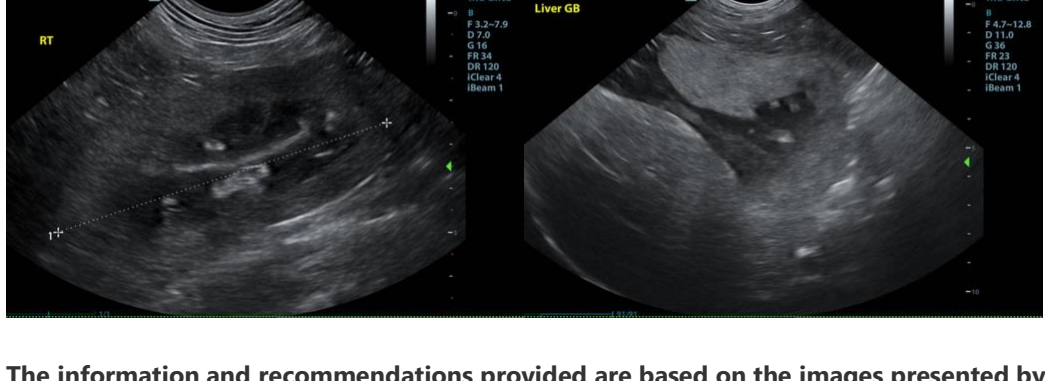
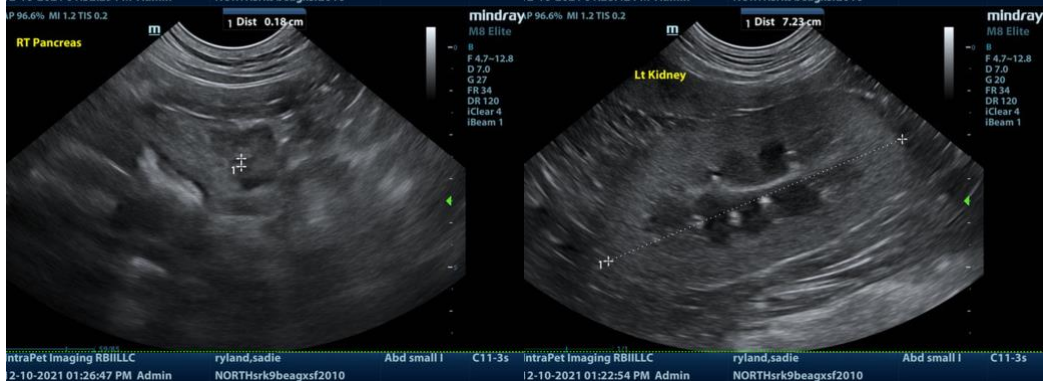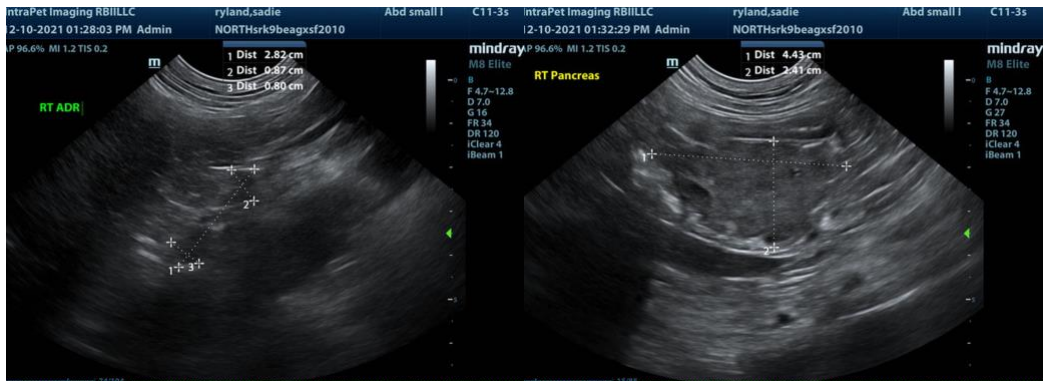
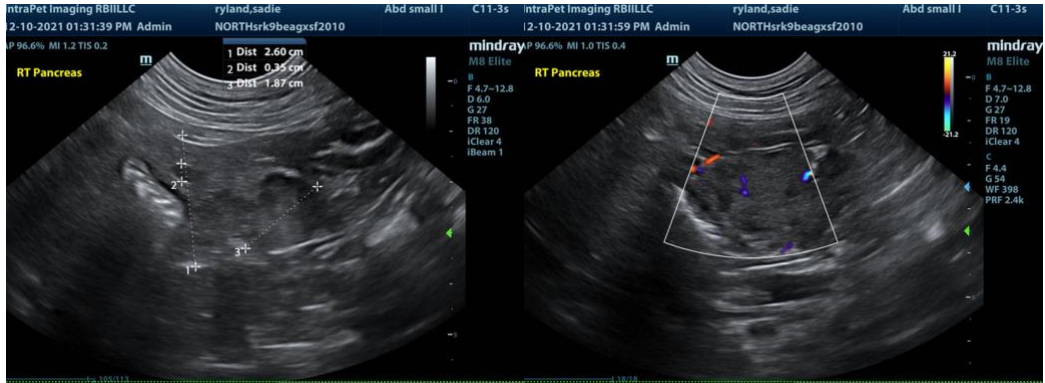
ULTRASONOGRAPHIC FINDINGS

- Enlarged irregular left adrenal gland.
- Nodular pancreatic changes
- Non-specific benign hepatopathy with inflammatory component
- Emerging gallbladder mucocele
- Age-related renal changes

INTERPRETATION OF THE FINDINGS & FURTHER RECOMMENDATIONS

Left adrenal differentials include adenocarcinoma, pheochromocytoma or pronounced hyperplasia, appears resectable. The nodular pancreatic changes are creating a mass, likely pronounced hyperplasia, potential for carcinoma, less likely lymphoma. Gallbladder motility study would be ideal, however, ursodiol therapy over the next 6-8 weeks and recheck sonogram could be considered. Ultrasound guided FNA of the pancreas recommended of the variable nodular changes. Serial blood pressures warranted. If hypertension is present, urine catecholamin warranted. Alternatively, left adrenalectomy, pancreatic biopsy/partial pancreatectomy and manual expression of the gallbladder could also be considered with liver biopsy.





The information and recommendations provided are based on the images presented by the

referring veterinarian. No evaluation can be communicated regarding pathology that was not visible in the image/video clips provided.

Thank you for this referral. If the clinical or image interpretation does not parallel your findings or if I can be of any further assistance please contact me.

Eric Lindquist, DMV, DABVP, Cert. IVUSS, CEO of SonoPath.com
Eric.Lindquist@SonoPath.com