



PATIENT

Jackson Rodriguez

SPECIES

Canine

BREED

Bernadoodle

SEX

Male

AGE

10 weeks

WEIGHT

17 lbs

INTERPRETED BY

Eric Lindquist, DMV
DABVP, Cert. IVUSS

IMAGING PERFORMED BY

Adrienne Ligenza

HOSPITAL NAME

Rush Veterinary
Urgent Care

REFERRING VET

Dr. Milot

INVOICE

94458

DATE

12/10/21

PRESENTING CLINICAL SIGNS

History: being treated for Parvo since Sunday, did stop vomiting for 36 hours now vomiting large amounts - bright green vomit, vomited 25 times in 24 hours period, diarrhea constantly, trying to rule out intussusception
Abnormal PE/Chem/CBC/UA Results: original BW was wnl, repeat CBC pending

ULTRASONOGRAPHIC EXAMINATION OF THE ABDOMEN

Urinary System

The **urinary bladder**, trigone, and pelvic urethra presented normal thicknesses and normal tone. The ureters were not visible which is normal. No uroliths or sediment were visualized and anechoic urine was present. No evidence of inflammatory or neoplastic changes was noted. Ureteral papillae were normal.

The **kidneys** revealed normal size and structure, corticomedullary definition and ratio for this age. The cortices presented largely uniform texture with normal echogenic relationship to liver and spleen. Medullary structure differed distinctly from the cortex and no evidence of pelvic dilation was present. The capsules were acceptably uniform without significant irregularities. The left kidney measured 6.0 cm. The right kidney measured 6.03 cm.

Adrenal Glands

Both **adrenal glands** were visualized and recognized as having normal shape, size, position and echogenicity for this breed. The phrenic vasculature, glandular echogenicity and detail were unremarkable. Capsule, cortex, and medullary definition were normal for this age patient. The left adrenal gland measured 1.26 x 0.45 cm at the caudal pole and 0.34 cm at the cranial pole. The right adrenal gland measured 1.82 x 0.42 cm at the caudal pole.

Spleen

The **spleen** presented a smooth homogeneous parenchyma hyperechoic to liver and renal cortical parenchyma. The capsule was smooth without noticeable expansion or deviation from within the spleen or adjacent pathology. The splenic vasculature demonstrated normal volume without signs of congestion or thrombosis. No sonographic evidence of acute or chronic inflammatory, neoplastic, or infarctual changes was noted.

Liver

The **liver** images submitted revealed subjectively normal liver size, contour, and structure. Parenchymal echogenicity was naturally coarse and hypoechoic to the spleen. Vascular and biliary tracts were of normal volume with no evidence of congestion. The gallbladder presented acceptably thin walls with primarily anechoic content. The cystic and common bile ducts were normal. No pathological hepatic lymphadenopathy was evident. No overt structural evidence of inflammatory, infiltrative or regenerative pathology was evident.



PATIENT

Gastrointestinal

Jackson Rodriguez

The **gastrointestinal tract** revealed an edematous wall and hyperperistalsis with no loss of mural detail. Minor enhanced surrounding fat was noted around the regions of the gastrointestinal serosa. There was no evidence of foreign body or neoplastic criteria. Images from the stomach, small intestine and colon were presented. This is most consistent with gastroenteritis owing to viral, bacterial/endotoxin or possible parasitic disease. Reactive mesentery was noted associated with the small intestine. The mesenteric lymph nodes were reactive and measured up to 2.0 x 1.0 cm.

SPECIES

Canine

BREED

Bernadoodle

Pancreas

The base and limbs of the **pancreas** were observed to be largely isoechoic to surrounding omental fat. Pancreatic duct and capsular contour were acceptably normal and parenchyma respected normal curvilinear patterns. No overt evidence of active inflammatory or neoplastic disease was noted.

SEX

Male

AGE

10 weeks

ULTRASONOGRAPHIC FINDINGS

Gastroenteritis.

Otherwise, unremarkable abdomen.

WEIGHT

17 lbs

INTERPRETATION OF THE FINDINGS & FURTHER RECOMMENDATIONS

There was no evidence of foreign bodies. Plasma expanders, plasma transfusion and treatment for enterotoxin and parasites are all indicated. There was no evidence of intussusception.

INTERPRETED BY

Eric Lindquist, DMV
DABVP, Cert. IVUS

IMAGING PERFORMED BY

Adrienne Ligenza

HOSPITAL NAME

Rush Veterinary
Urgent Care

REFERRING VET

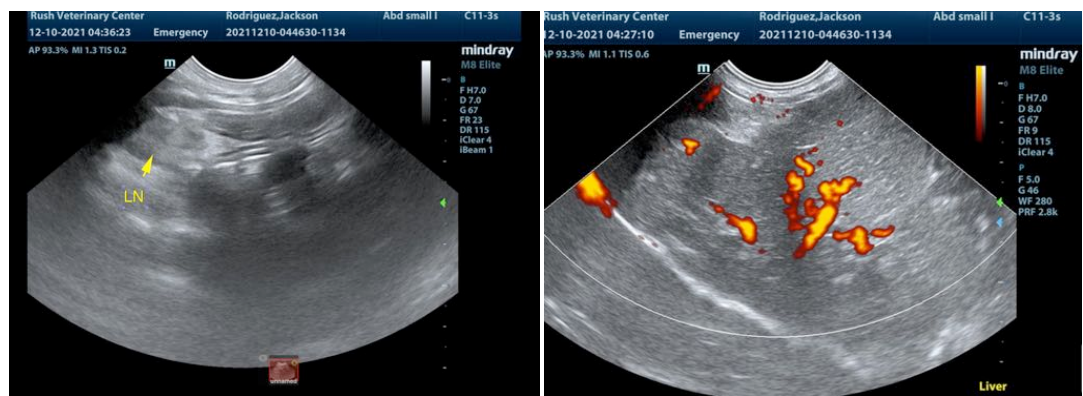
Dr. Milot

INVOICE

94458

DATE

12/10/21





PATIENT

Jackson Rodriguez

SPECIES

Canine

BREED

Bernadoodle

SEX

Male

AGE

10 weeks

WEIGHT

17 lbs

INTERPRETED BY

Eric Lindquist, DMV
DABVP, Cert. IVUS

IMAGING PERFORMED BY

Adrienne Ligenza

HOSPITAL NAME

Rush Veterinary
Urgent Care

REFERRING VET

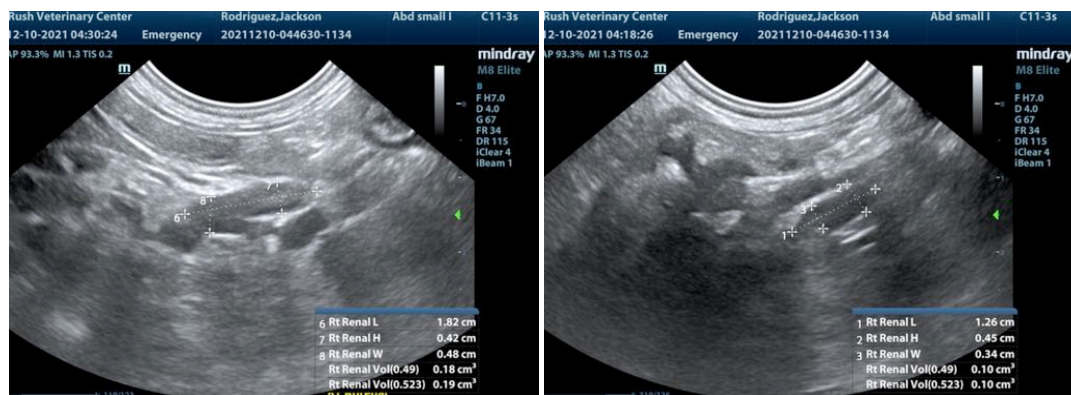
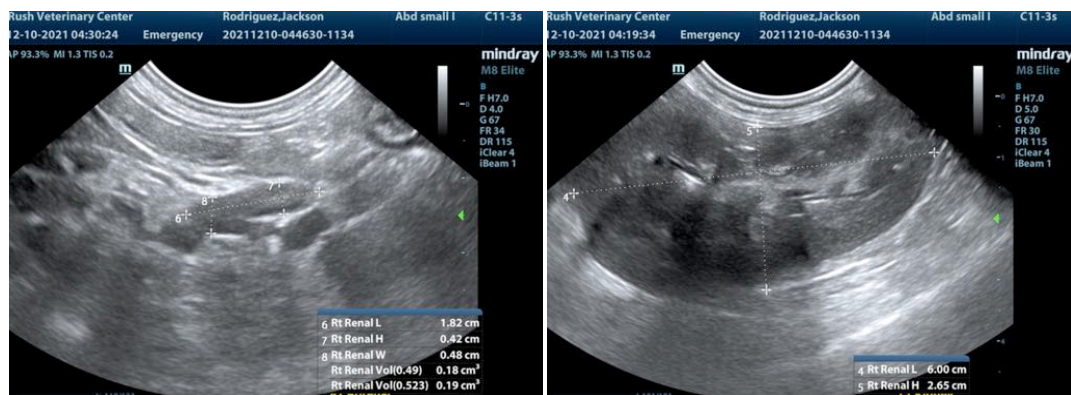
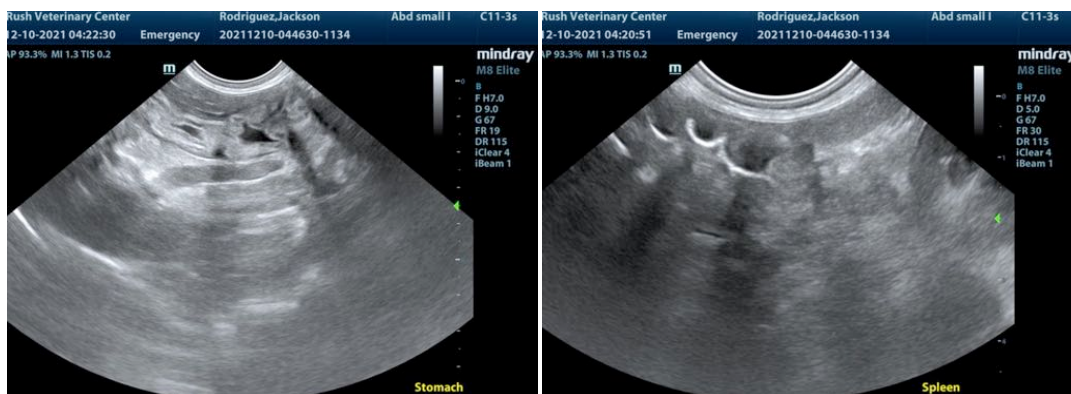
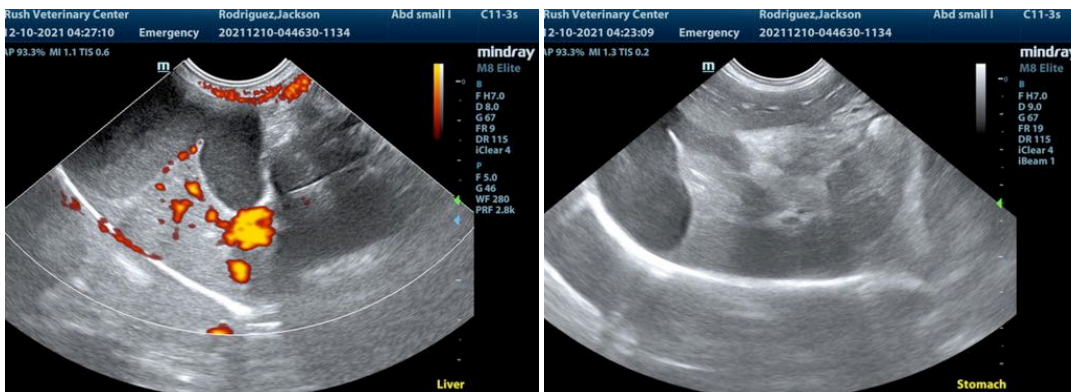
Dr. Milot

INVOICE

94458

DATE

12/10/21





PATIENT

Jackson Rodriguez

SPECIES

Canine

BREED

Bernadoodle

The information and recommendations provided are based on the images presented by the referring veterinarian. No evaluation can be communicated regarding pathology that was not visible in the image/video clips provided.

Thank you for this referral. If the clinical or image interpretation does not parallel your findings or if I can be of any further assistance please contact me.

SEX

Male

Eric Lindquist, DMV, DABVP, Cert. IVUSS, CEO of SonoPath.com
info@SonoPath.com

AGE

10 weeks

WEIGHT

17 lbs

INTERPRETED BY

Eric Lindquist, DMV
DABVP, Cert. IVUSS

**IMAGING
PERFORMED BY**

Adrienne Ligenza

HOSPITAL NAME

Rush Veterinary
Urgent Care

REFERRING VET

Dr. Milot

INVOICE

94458

DATE

12/10/21