**DATE PRESENTING CLINICAL SIGNS**

12/10/21

History: P has intermittent vomiting (every other day per O). Can be hours after eating - vomit usually contains undigested food but occasionally may just be bile. No PU/PD. Bowel movements WNL.

PATIENT

Gracie Nielsen

Lab Results: Bloodwork done 12/01/21, CBC: Mild neutropenia, Chem: Crea 1.6, BUN 13, Cardiopet: WNL, Urinalysis: SG 1.052, 2+ pro, glu neg, 2-5 WBCs/hpf, >100 RBCs/hpf, T4: WNL. Attached separately.

Date of Previous IntraPet Ultrasound: No previous IntraPet scans.

SPECIES

Sedation: IM Kitty Magic.

Feline

Stat Report: Not requested.

BREED**ULTRASONOGRAPHIC EXAMINATION OF THE ABDOMEN**

DSH

Urinary System

The **urinary bladder**, trigone, and pelvic urethra presented normal thicknesses and normal tone. The ureters were not visible which is normal. No uroliths or sediment were visualized and anechoic urine was present. No evidence of inflammatory or neoplastic changes were noted. Ureteral papillae were normal.

SEX

Spayed Female

AGE

2/2/09

The **kidneys** revealed largely normal size and structure, corticomedullary definition and ratio (cortex 1/3 of medulla) were essentially maintained with some minor age-related loss of curvilinear patterns regarding the capsule and C/M junction. The cortices presented largely uniform texture with some increased echogenicity expected for his age patient. Medullary structure differed distinctly from that of the cortex and no evidence of pelvic dilation was present. Slight mineralization was present in the right kidney. The right kidney measured 3.97cm. The left kidney measured 3.97 cm.

WEIGHT

11.9 Lbs.

Adrenal Glands

The **left adrenal gland** was visualized and recognized as having normal shape, size, position and echogenicity for this breed. The phrenic vasculature, glandular echogenicity and detail were unremarkable. Capsule, cortex, and medullary definition were normal for this age patient. The left adrenal gland measured 0.52 cm.

INTERPRETED BY

Eric Lindquist, DMV
DABVP, Cert. IVUSS

The region of the **right adrenal gland** revealed no evident pathology.

IMAGING PERFORMED BY**Spleen**

The **spleen** presented a smooth homogeneous parenchyma hyperechoic to liver and renal cortical parenchyma. The capsule was smooth without noticeable expansion or deviation from within the spleen or adjacent pathology. The splenic vasculature demonstrated normal volume without signs of congestion or thrombosis. No sonographic evidence of acute or chronic inflammatory, neoplastic, or infarctual changes were noted.

Rachel Brillhart RDMS

HOSPITAL NAME

Churchville VC

Liver

The **liver** revealed increased portal markings and multifocal lobar biliary mineralization. The gallbladder was unremarkable, other than minor sand accumulation.

REFERRING VET

Dr. Kauffman

Gastrointestinal

Examination of the **gastrointestinal tract** revealed a stomach and intestine free of stasis, of normal wall thickness, acceptable curvilinear mural detail, and peristaltic activity. Small and large intestine demonstrated normal luminal chyme and stool consistency respectively. No obstructive or overt infiltrative disease was noted. No associated abnormal lymphatic activity was noted.

INVOICE

13002

Pancreas

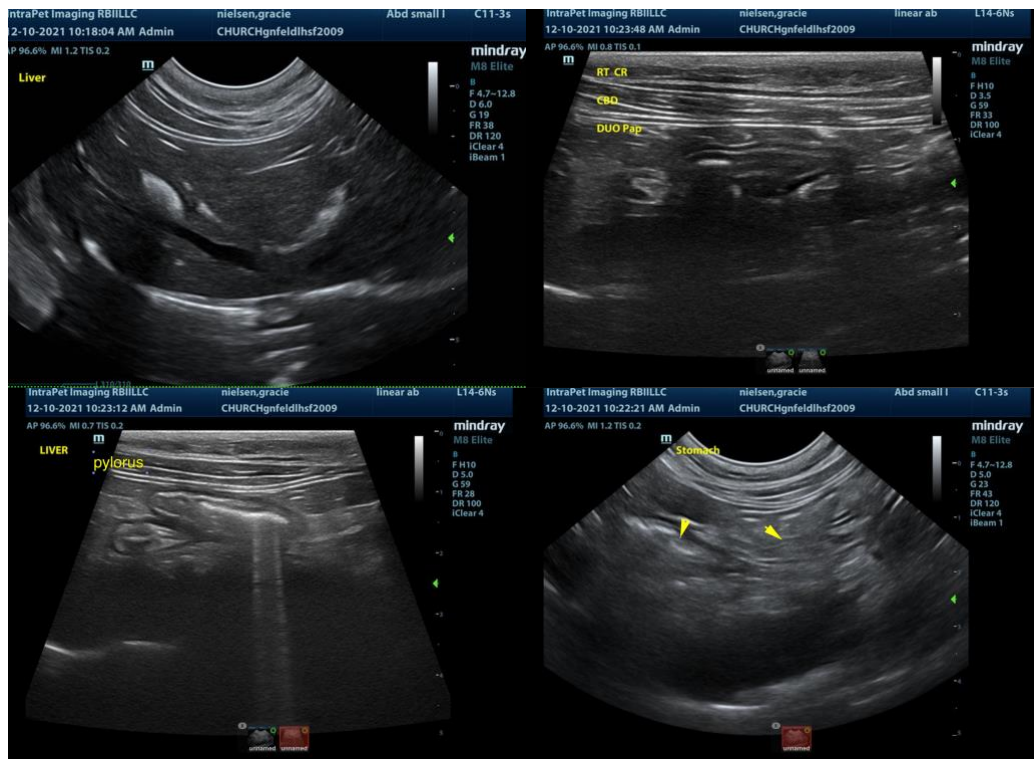
The base and limbs of the **pancreas** were observed to be largely isoechoic to surrounding omental fat. Some minor parenchymal remodeling, however, with mild deviation from curvilinear normalcy was observed. The pancreatic duct was dilated (0.19 cm). If pain upon imaging (+ Murphy sign) was present or if the patient is focally painful in subxyphoid palpation then low-grade smoldering chronic pancreatitis should be suspected.

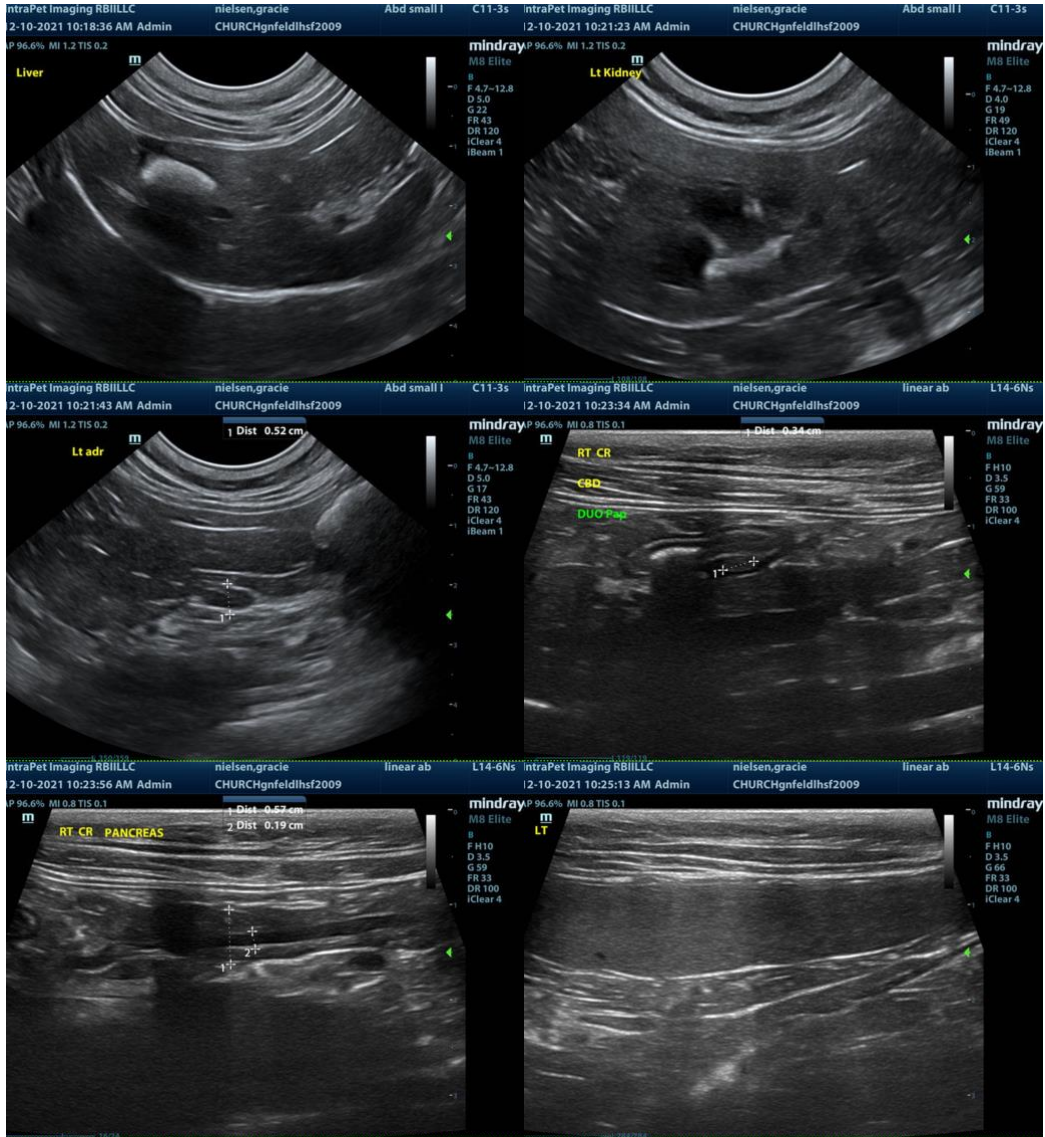
ULTRASONOGRAPHIC FINDINGS

- Gallbladder and biliary sand, history of cholangitis likely.
- Age-related pancreatic and renal changes

INTERPRETATION OF THE FINDINGS & FURTHER RECOMMENDATIONS

No evidence of significant structural GI disease. Underlying food intolerance likely playing a role. Occult parasitism and biliary sand movement are also a potential. Ursodiol therapy warranted over the next 6-8 weeks and reassessment of the sonogram for any improvement. History of pancreatitis with potential low grade inflammation may be playing a role.





The information and recommendations provided are based on the images presented by the referring veterinarian. No evaluation can be communicated regarding pathology that was not visible in the image/video clips provided.

Thank you for this referral. If the clinical or image interpretation does not parallel your findings or if I can be of any further assistance please contact me.

Eric Lindquist, DMV, DABVP, Cert. IVUSS, CEO of SonoPath.com
Eric.Lindquist@SonoPath.com