

**PATIENT PRESENTING CLINICAL SIGNS**

Cubby Wisinski History: Grade IV/VI L apical systolic murmur. No current meds.

**SPECIES ULTRASONOGRAPHIC EXAMINATION OF THE HEART**

Feline The echocardiogram in this patient demonstrated normal **left atrial** size and structure with no evidence of “smoke” or thrombi. The cranial and caudal **mitral** valve leaflets appeared mildly thickened with some insufficiency noted on Doppler. The **left ventricle** presented excessive free wall and septal thicknesses with hypertrophic thicknesses compared to normal for this species. The **myocardium** presented essentially normal echogenicity without immediate signs of fibrotic or ischemic disease. **Contractility** of the ventricular walls was considered excessive for this patient evidenced by the elevated fractional shortening measurement. The **aortic outflow** revealed turbulence with secondary aortic insufficiency. Moderate fixed LVOT obstruction was noted with moderate to severe excessive **left ventricular outflow velocity**. Subjective assessment of the **right atrium** and auricle revealed normal size, structure and content. No evidence of masses was noted. **Tricuspid** valvular assessment demonstrated linear morphology. The **right ventricle** was of normal size with normal chordae structure, myocardial echogenicity and thickness. **Pulmonic** tract assessment revealed normal valve structure, laminar flow, and diameter. No visible **pericardial** or free pleura fluid was noted. No echographically detectable evidence of infiltrative disease was visible. The **mediastinum** was free of masses in the visible window.

**WEIGHT**

9.4 lbs

**INTERPRETED BY**

Eric Lindquist, DMV  
DABVP, Cert. IVUSS

**IMAGING PERFORMED BY**

Shari Reffi, CVT

**HOSPITAL NAME**

VCA Blairstown AH

**REFERRING VET**

Dr. Lovell

**INVOICE**

94472

**DATE**

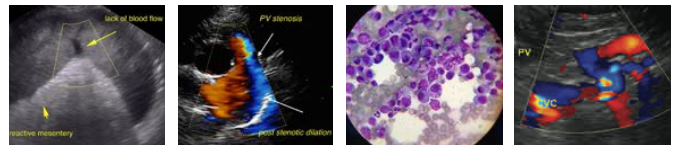
12/10/21

**ULTRASONOGRAPHIC FINDINGS**

Hypertrophic cardiomyopathy with fixed LVOT obstruction.

| FELINE CARDIAC PARAMETERS | BODY WEIGHT (kg) | HR (BPM)                  | IVSd (cm)  | LVIDd (cm)      | LVWd (cm)       | FS (%)    | EF (%) |
|---------------------------|------------------|---------------------------|--|-----------------|-----------------|-----------|--------|
| NORMAL PARAMETER          | -----            | 150-240                   | 0.3-0.6  | 1.0-2.1         | 0.25-0.6        | 35-67     | 80-100 |
| PATIENT                   |                  | NM                        |  |                 |                 |           |        |
| FELINE CARDIAC PARAMETERS | LA/AO (Boon)     | LA/AO HEART BASE (Sisson) | LA 2D 4-chamber long axis AS to FW (Sisson) (cm) | LVOT VEL. (m/s) | RVOT VEL. (m/s) | IVRT (m/) |        |
| NORMAL PARAMETER          | <1.5             | 0.88-1.79                 | 0.7-1.7  | <1.6            | <1.3            | 40-60     |        |
| PATIENT                   |                  |                           | 1.2  | 4.96            | 0.81            | NM        |        |

Adapted from June Boon, Veterinary Echocardiography, 1998  
Sisson D et al. JVIM 1991; 5: 232, Jacobs et al. Am J Vet Res 1985; 46:1705



**PATIENT**

Cubby Wisinski

**SPECIES**

Feline

**BREED**

Persian

**SEX**

Neutered male

**AGE**

3 years

**WEIGHT**

9.4 lbs

**INTERPRETED BY**

Eric Lindquist, DMV  
DABVP, Cert. IVUSS

**IMAGING PERFORMED BY**

Shari Reffi, CVT

**HOSPITAL NAME**

VCA Blairstown AH

**REFERRING VET**

Dr. Lovell

**INVOICE**

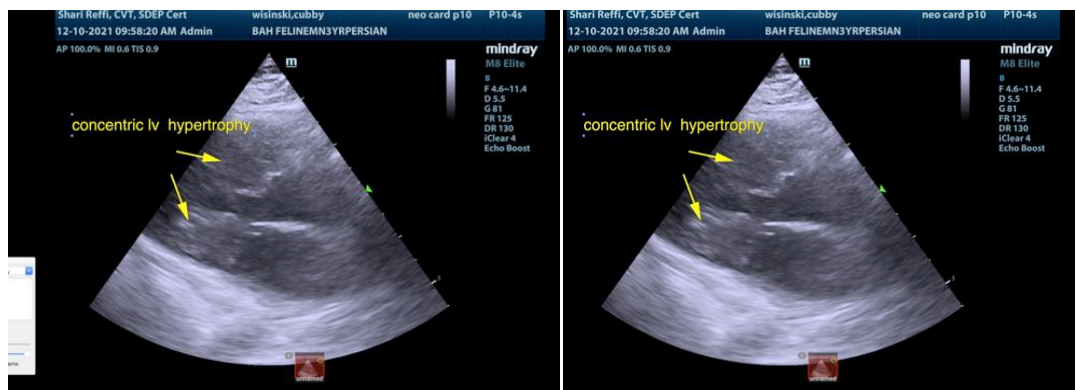
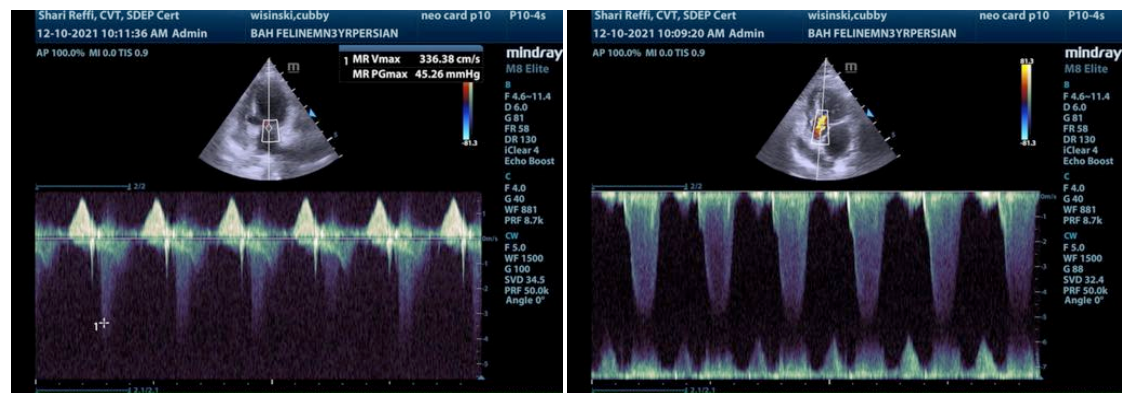
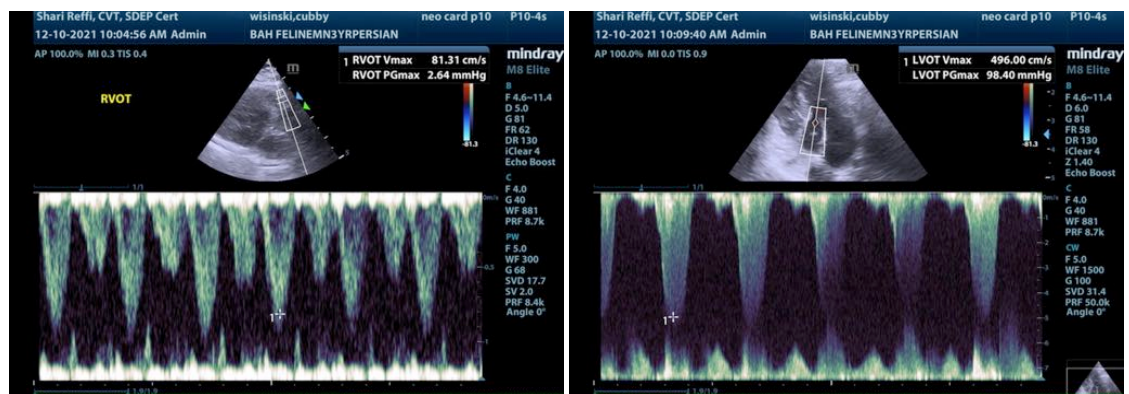
94472

**DATE**

12/10/21

**INTERPRETATION OF THE FINDINGS & FURTHER RECOMMENDATIONS**

I recommend Atenolol therapy at 6.25 mg b.i.d. A recheck echocardiogram is recommended in 3-6 months or earlier if exercise intolerance is an issue. There was no volume overload noted at this time.





**PATIENT**

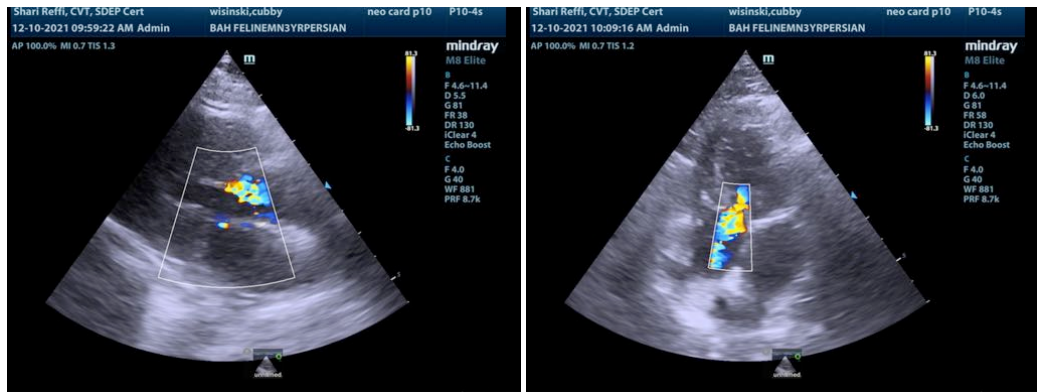
Cubby Wisinski

**SPECIES**

Feline

**BREED**

Persian



**SEX**

Neutered male

The information and recommendations provided are based on the images presented by the referring veterinarian. No evaluation can be communicated regarding pathology that was not visible in the image/video clips provided.

**AGE**

3 years

Thank you for this referral. If the clinical or image interpretation does not parallel your findings or if I can be of any further assistance please contact me.

**WEIGHT**

9.4 lbs

**Eric Lindquist, DMV, DABVP, Cert. IVUSS, CEO of SonoPath.com**  
Info@SonoPath.com

**INTERPRETED BY**

Eric Lindquist, DMV  
DABVP, Cert. IVUSS

**IMAGING PERFORMED BY**

Shari Reffi, CVT

**HOSPITAL NAME**

VCA Blairstown AH

**REFERRING VET**

Dr. Lovell

**INVOICE**

94472

**DATE**

12/10/21