

PATIENT

Oliver Quirk

SPECIES

Canine

BREED

Bichon Frise Mix

SEX

Neutered male

AGE

11 years

WEIGHT

30.8 lbs

INTERPRETED BY

Eric Lindquist, DMV
DABVP, Cert. IVUSS

IMAGING PERFORMED BY

Dr. Carlos Abdul Chani

HOSPITAL NAME

Byram AH

REFERRING VET

Dr. Cruz

INVOICE

69193

DATE

12/1/25

PRESENTING CLINICAL SIGNS

History: Recheck stomach area for possible lesion. Fasting for 14 hours. Initial US submitted 11/26/2025

ULTRASONOGRAPHIC EXAMINATION

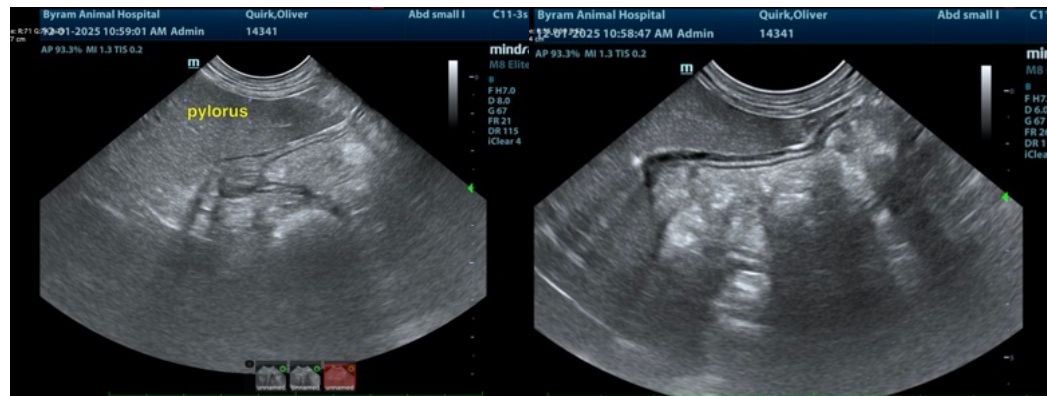The stomach in this patient presented a mild amount of ingesta and normal wall thicknesses. The gastroesophageal inlet was unremarkable. Amid the ingesta a 2.0 x 1.0 cm polypoid change noted. The muscularis and submucosa appeared unremarkable. The small intestines and colon were unremarkable with normal curvilinear mural patterns and content.

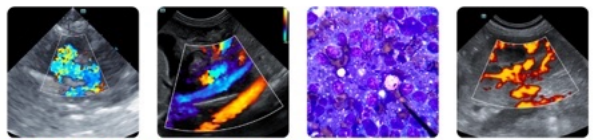
ULTRASONOGRAPHIC FINDINGS

Gastric mucosal polyps in the stomach, appears persistent and does not appear overtly pathological.

INTERPRETATION OF THE FINDINGS & FURTHER RECOMMENDATIONS

If any upper GI signs are persistently present, then endoscopy is indicated. Power Doppler signals were positive upon the polyps, yet these appear to be benign or low-grade. Recheck sonogram is recommended in a month at n.p.o. status.





PATIENT

Oliver Quirk

SPECIES

Canine

BREED

Bichon Frise Mix

SEX

Neutered male

AGE

11 years

WEIGHT

30.8 lbs

INTERPRETED BY

Eric Lindquist, DMV
DABVP, Cert. IVUSS

IMAGING PERFORMED BY

Dr. Carlos Abdul Chani

HOSPITAL NAME

Byram AH

REFERRING VET

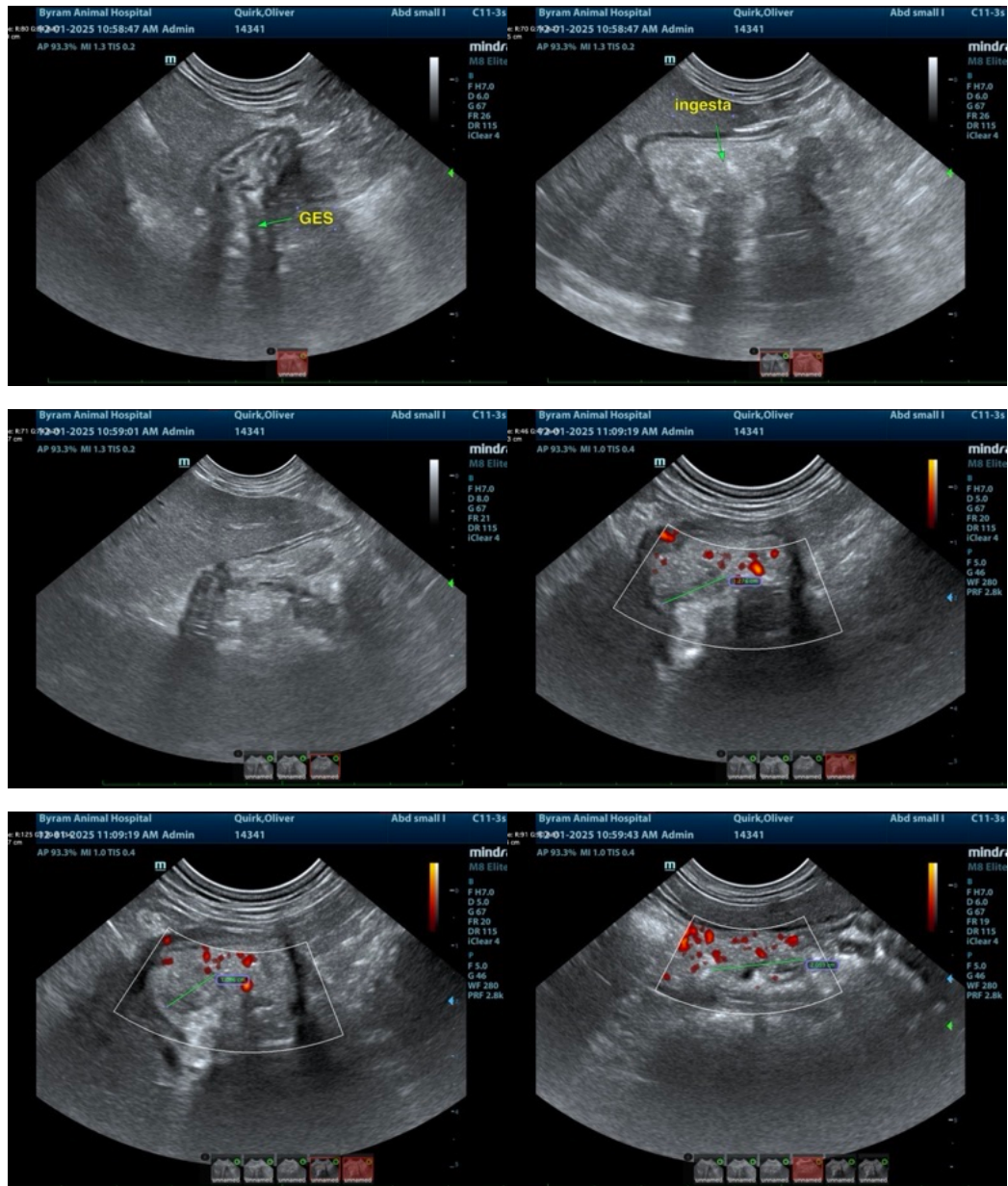
Dr. Cruz

INVOICE

69193

DATE

12/1/25



The information and recommendations provided are based on the images presented by the referring veterinarian/sonographer. No evaluation can be communicated regarding pathology that was not visible in the image/video clips provided.

Thank you for this referral. If the clinical or image interpretation does not parallel your findings or if I can be of any further assistance please contact me.

Eric Lindquist, DMV, DABVP (CFM), Cert. IVUSS, CEO of SonoPath.com

info@SonoPath.com