



PATIENT

Shea Ryan

SPECIES

Canine

BREED

Labrador Retriever

SEX

Neutered male

AGE

11 years

WEIGHT

94 lbs

INTERPRETED BY

Eric Lindquist, DMV
DABVP, Cert. IVUSS

**IMAGING
PERFORMED BY**

Dr. Scott

HOSPITAL NAME

HoHoKus VH

REFERRING VET

Dr. Gannon

INVOICE

42818

DATE

12/1/22

PRESENTING CLINICAL SIGNS

History: Here in sept/oct for lethargy. Favoring RH leg, lyme + on 4dx. UPC 1.1, Tx with doxy and rimadyl. Follow up in October - dog back to normal. Past few weeks seemed to regress. Off rimadyl dog will limp.

Abnormal PE/Chem/CBC/UA Results: Hx of slightly low Alb 2.4, Continued weight loss. Dec 2021- 107lb, Aug 2022- 99.8lb, Nov 2022- 90lb., Today 94lb

ULTRASONOGRAPHIC EXAMINATION OF THE ABDOMEN

Urinary System

The **urinary bladder**, trigone, and pelvic urethra presented normal thicknesses and normal tone. The ureters were not visible which is normal. No uroliths or sediment were visualized and anechoic urine was present. No evidence of inflammatory or neoplastic changes was noted. Ureteral papillae were normal.

The **kidneys** revealed normal size and structure, corticomedullary definition and ratio for this age. The cortices presented largely uniform texture with normal echogenic relationship to liver and spleen. Medullary structure differed distinctly from the cortex and no evidence of pelvic dilation was present. The capsules were acceptably uniform without significant irregularities. The left kidney measured 6.0 cm. The right kidney measured 6.0 cm.

Adrenal Glands

Both **adrenal glands** were visualized and recognized as having normal shape, size, position and echogenicity for this breed. The phrenic vasculature, glandular echogenicity and detail were unremarkable. Capsule, cortex, and medullary definition were normal for this age patient. The left adrenal gland measured 0.6 cm. The right adrenal gland measured 0.6 cm.

Spleen

The **spleen** revealed a subtle, hypoechoic nodule noted. The nodule was non-disruptive and measured 0.5 cm at the mid body.

Liver

The **liver** images submitted revealed subjectively normal liver size, contour, and structure. Parenchymal echogenicity was naturally coarse and hypoechoic to the spleen. Vascular and biliary tracts were of normal volume with no evidence of congestion. The gallbladder presented acceptably thin walls with primarily anechoic content. The cystic and common bile ducts were normal. No pathological hepatic lymphadenopathy was evident. No overt structural evidence of inflammatory, infiltrative or regenerative pathology was evident.



PATIENT

Gastrointestinal

Shea Ryan

Examination of the **gastrointestinal tract** revealed a stomach and intestine free of stasis, of normal wall thickness, acceptable curvilinear mural detail, and peristaltic activity. Small and large intestine demonstrated normal luminal chyme and stool consistency respectively. No obstructive or overt infiltrative disease was noted. No associated abnormal lymphatic activity was noted.

SPECIES

Canine

BREED

Labrador Retriever

Pancreas

The base and limbs of the **pancreas** were observed to be largely isoechoic to surrounding omental fat. Pancreatic duct and capsular contour were acceptably normal and parenchyma respected normal curvilinear patterns. No overt evidence of active inflammatory or neoplastic disease was noted.

SEX

Neutered male

ULTRASONOGRAPHIC FINDINGS

Splenic nodules.

AGE

11 years

Otherwise, structurally unremarkable abdomen.

WEIGHT

94 lbs

INTERPRETATION OF THE FINDINGS & FURTHER RECOMMENDATIONS

FNA of the splenic nodule and recheck in a month is recommended to assess for any growth. There was no evidence of visceral disease that would be responsible for the clinical signs. Given the low albumin baseline cortisol or ACTH stimulation is indicated even though the adrenal glands appear normal. Underlying protein losing enteropathy may be an issue given the minor proteinuria; however, structurally the GI tract appears unremarkable.

INTERPRETED BY

Eric Lindquist, DMV
DABVP, Cert. IVUSS

Maldigestion panel, three view chest radiographs and full CNS examination is recommended to examine for occult disease that could be responsible for the weight loss. Evaluation for competitive eating environments should also be considered.

IMAGING PERFORMED BY

Dr. Scott

HOSPITAL NAME

HoHoKus VH

REFERRING VET

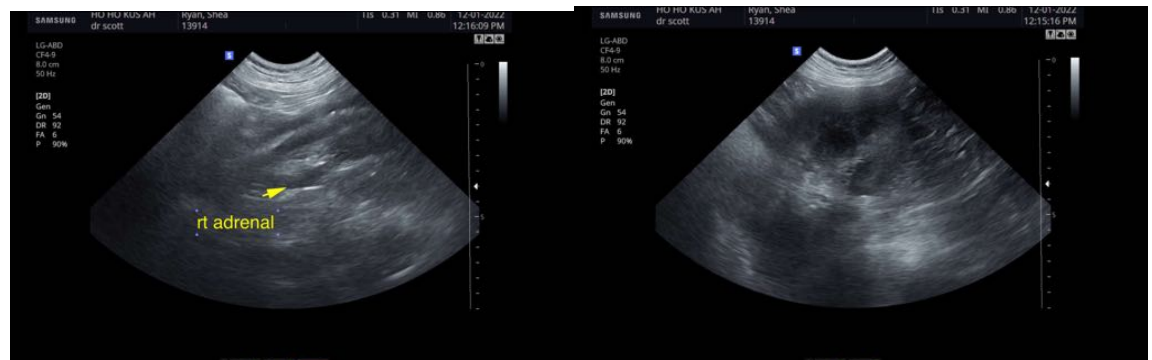
Dr. Gannon

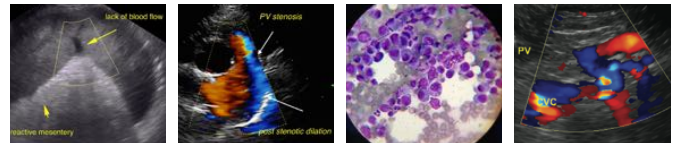
INVOICE

42818

DATE

12/1/22





PATIENT

Shea Ryan

SPECIES

Canine

BREED

Labrador Retriever

SEX

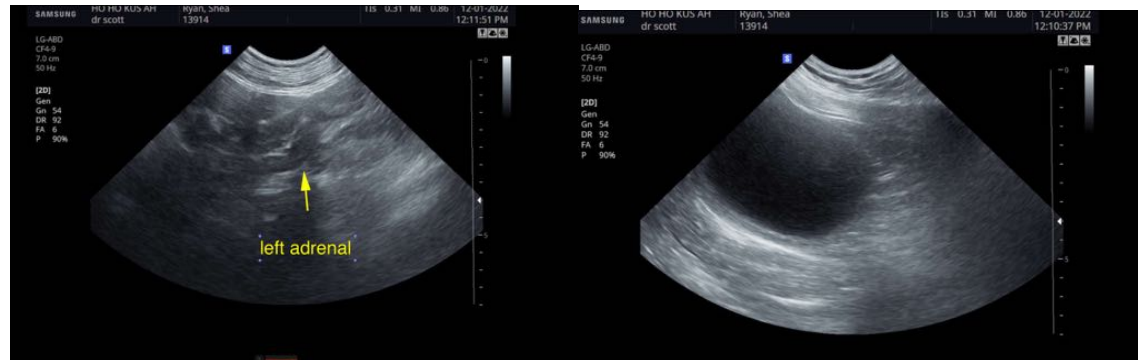
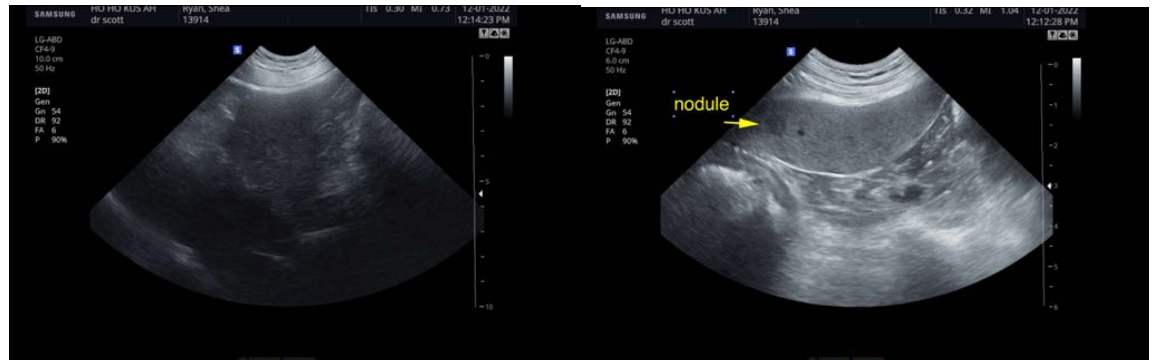
Neutered male

AGE

11 years

WEIGHT

94 lbs



INTERPRETED BY

Eric Lindquist, DMV
DABVP, Cert. IVUSS

IMAGING PERFORMED BY

Dr. Scott

HOSPITAL NAME

HoHoKus VH

REFERRING VET

Dr. Gannon

INVOICE

42818

DATE

12/1/22

The information and recommendations provided are based on the images presented by the referring veterinarian/sonographer. No evaluation can be communicated regarding pathology that was not visible in the image/video clips provided.

Thank you for this referral. If the clinical or image interpretation does not parallel your findings or if I can be of any further assistance please contact me.

Eric Lindquist, DMV, DABVP, Cert. IVUSS, CEO of SonoPath.com
info@SonoPath.com