



PATIENT PRESENTING CLINICAL SIGNS

Teddy Davies woke up with body swollen around chest, cries when trying to poop and pee

SPECIES ULTRASONOGRAPHIC EXAMINATION OF THE HEART & ABDOMEN

Canine

BREED

Yorkie

SEX

Spayed Female

AGE

13 Years

WEIGHT

10.3 Pounds

CANINE CARDIAC PARAMETERS	MR VMAX (m/s)	TR VMAX (m/s)	LA/AO (Boon method)	LA/AO (Heart Base; Swe)	FS (%)	EF (%)	EPSS (cm)
NORMAL PARAMETER	4.5-5.5	<2.7	1.3	<1.6	28-40	40-100	<0.6
PATIENT	--		1.6	1.8	50		NM
CANINE CARDIAC PARAMETERS	HR (BPM)	AV VMAX (m/s)	PV MAX (m/s)	BODY WEIGHT (kg)	LA 2D short axis Base view (cm)	LVIDd Avg; 2D and m-mode short axis (cm)	LVIDs Avg; 2D and m-mode short axis (cm)
NORMAL PARAMETER	50-100	0.7-1.7	0.7-1.6				
PATIENT		1.2	0.62		3.34	2.5	

Cardiac Presentation

The echocardiogram for this patient presented mildly excessive **left atrial size** expressed both in the LA/AO and LA max measurements Chamber volumes and echogenicity were normal. The cranial and caudal **mitral** valve leaflets presented vegetative thickening consistent with endocardiosis. Doppler indicated measurable insufficiency. The **left ventricle** presented thicknesses with linear contour and was not dilated nor restricted. The **myocardium** presented normal echogenicity without subjective evidence of significant fibrotic or ischemic disease. **Contractility** of the ventricular walls was adequate and in normal range for this patient evidenced by the fractional shortening measurement and subjective evaluation of the different regions of the myocardium. The **left ventricular outflow** tract demonstrated normal laminar flow and subjective structural integrity. The **right atrium** and auricle revealed normal size, structure and content. No evidence of masses was noted or chamber overload. **Tricuspid** valvular assessment demonstrated adequate linear morphology. The **right ventricle** was of normal size (1/3 diameter of LV), chordae structure, myocardial echogenicity and thickness. **Pulmonic** tract assessment revealed normal valve structure, laminar flow, and diameter (approx.1:1 pa/ao ratio). No visible **pericardial** or free pleura fluid was noted. No echographically detectable evidence of infiltrative disease was visible. The cranial **mediastinum and pericardial regions** were free of masses in the visible window.

Urinary System

The **urinary bladder**, trigone, and pelvic urethra presented normal thicknesses and normal tone. The ureters were not visible which is normal. No uroliths or sediment were visualized and anechoic urine was present. No evidence of inflammatory or neoplastic changes were noted. Ureteral papillae were normal.

The **kidneys** revealed largely normal size and structure, corticomedullary definition and ratio (cortex 1/3 of medulla) were essentially maintained with some age-related loss of curvilinear patterns regarding the capsule and C/M junction. The cortices presented largely uniform texture with some increased

INTERPRETED BY

Eric Lindquist, DMV DABVP, Cert. IVUSS

IMAGING PERFORMED BY

Jenn

HOSPITAL NAME

Rockaway AH

REFERRING VET

Dr. Maniar

INVOICE

33133

DATE

12/1/21



PATIENT

Teddy Davies

echogenicity expected for his age patient. Medullary structure differed distinctly from that of the cortex and no evidence of pelvic dilation was present. The right kidney measured 3.43 cm. The left kidney measured 3.7 cm.

SPECIES

Canine

Adrenal Glands

Both **adrenal glands** were visualized and recognized as having normal shape, size, position and echogenicity for this breed. The phrenic vasculature, glandular echogenicity and detail were unremarkable. Capsule, cortex, and medullary definition were normal for this age patient. The right adrenal gland measured 1.31 cm x 0.5 cm at the caudal pole and 0.87 cm at the cranial pole. The left adrenal gland measured 1.25 cm x 0.47 cm at the caudal pole and 0.51 cm at the cranial pole.

BREED

Yorkie

Spleen

The **spleen** presented a smooth homogeneous parenchyma hyperechoic to liver and renal cortical parenchyma. The capsule was smooth without noticeable expansion or deviation from within the spleen or adjacent pathology. The splenic vasculature demonstrated normal volume without signs of congestion or thrombosis. No sonographic evidence of acute or chronic inflammatory, neoplastic, or infarctual changes were noted.

SEX

Spayed Female

AGE

13 Years

Liver

The **liver** images submitted revealed subjectively normal liver size, contour, and structure. Parenchymal echogenicity was naturally coarse and hypoechoic to the spleen. Vascular and biliary tracts were of normal volume with no evidence of congestion. The gallbladder presented acceptably thin walls with primarily anechoic content. The cystic and common bile ducts were normal. No pathological hepatic lymphadenopathy was evident. No overt structural evidence of inflammatory, infiltrative or regenerative pathology was evident.

WEIGHT

10.3 Pounds

INTERPRETED BY

Eric Lindquist, DMV
DABVP, Cert. IVUSS

Gastrointestinal

Minor **gastritis** pattern noted. The small intestine and colon were unremarkable.

IMAGING PERFORMED BY

Jenn

Pancreas

The base and limbs of the **pancreas** were observed to be largely isoechoic to surrounding omental fat. Pancreatic duct and capsular contour were acceptably normal and parenchyma respected normal curvilinear patterns. No overt evidence of active inflammatory or neoplastic disease was noted.

HOSPITAL NAME

Rockaway AH

ULTRASONOGRAPHIC FINDINGS

- Early Stage B2 valvular disease with mitral insufficiency and mild left atrial enlargement
- Gastritis pattern

REFERRING VET

Dr. Maniar

INTERPRETATION OF THE FINDINGS & FURTHER RECOMMENDATIONS

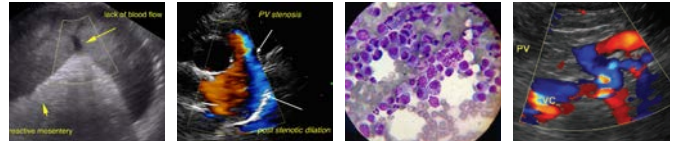
GI protectant protocol indicated. After GI presentation has clinically resolved, I would recommend Pimobendan 0.3 mg/kg BID. Recheck echo in 1-3 months.

INVOICE

33133

DATE

12/1/21



PATIENT

Teddy Davies

SPECIES

Canine

BREED

Yorkie

SEX

Spayed Female

AGE

13 Years

WEIGHT

10.3 Pounds

INTERPRETED BY

Eric Lindquist, DMV
DABVP, Cert. IVUSS

IMAGING PERFORMED BY

Jenn

HOSPITAL NAME

Rockaway AH

REFERRING VET

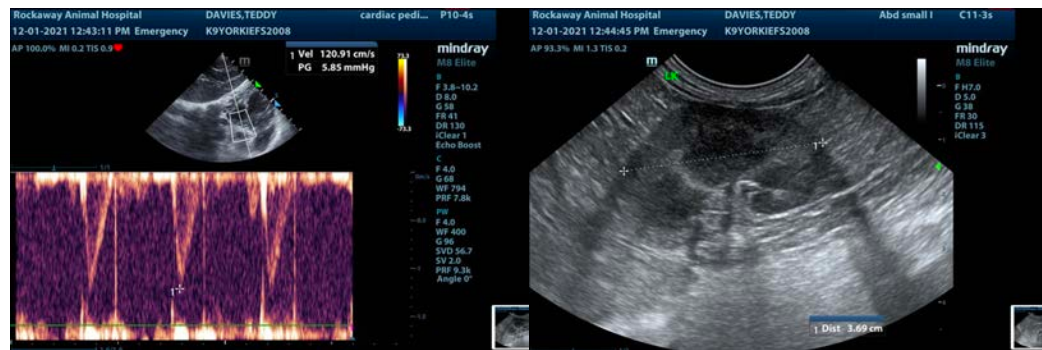
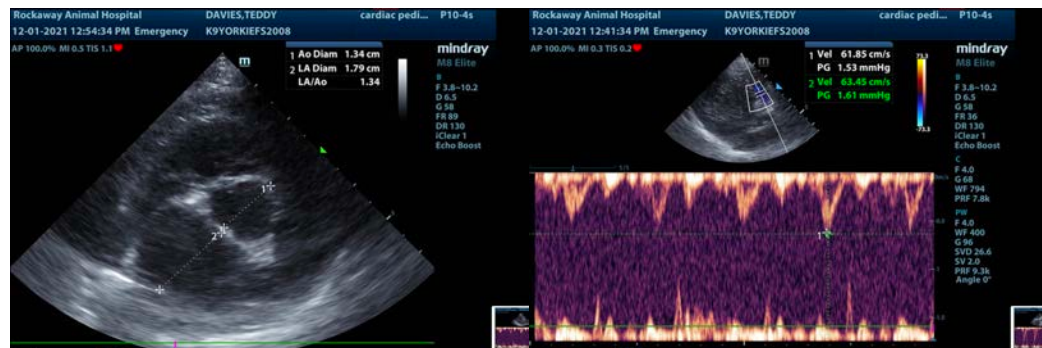
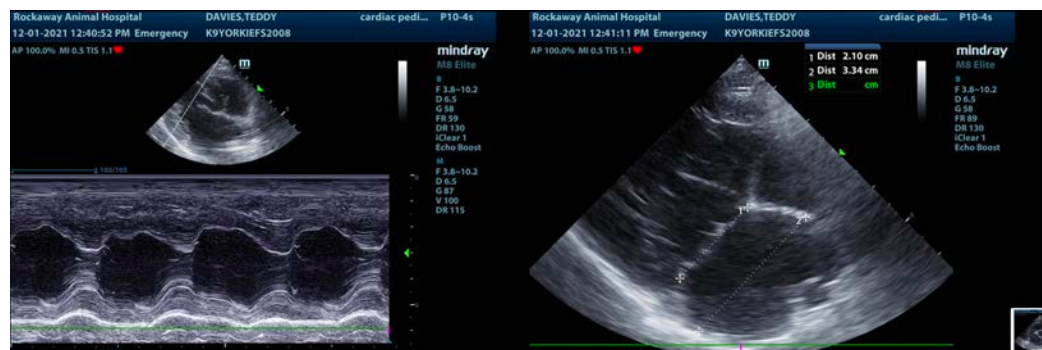
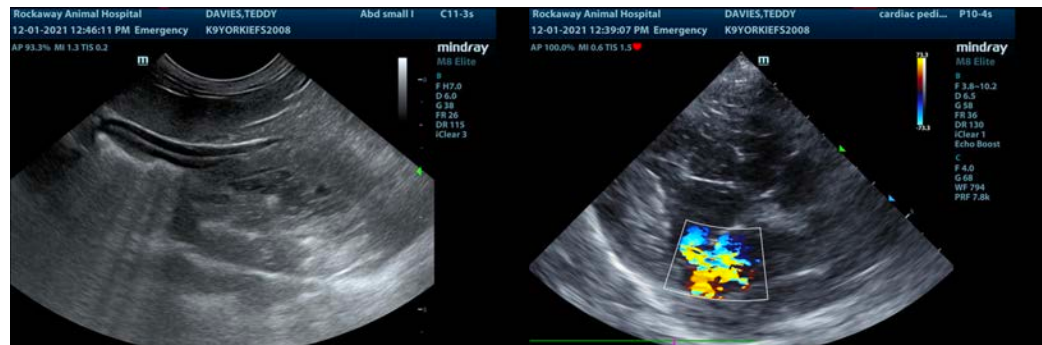
Dr. Maniar

INVOICE

33133

DATE

12/1/21





PATIENT

Teddy Davies

SPECIES

Canine

BREED

Yorkie

SEX

Spayed Female

AGE

13 Years

WEIGHT

10.3 Pounds

INTERPRETED BY

Eric Lindquist, DMV
DABVP, Cert. IVUSS

IMAGING PERFORMED BY

Jenn

HOSPITAL NAME

Rockaway AH

REFERRING VET

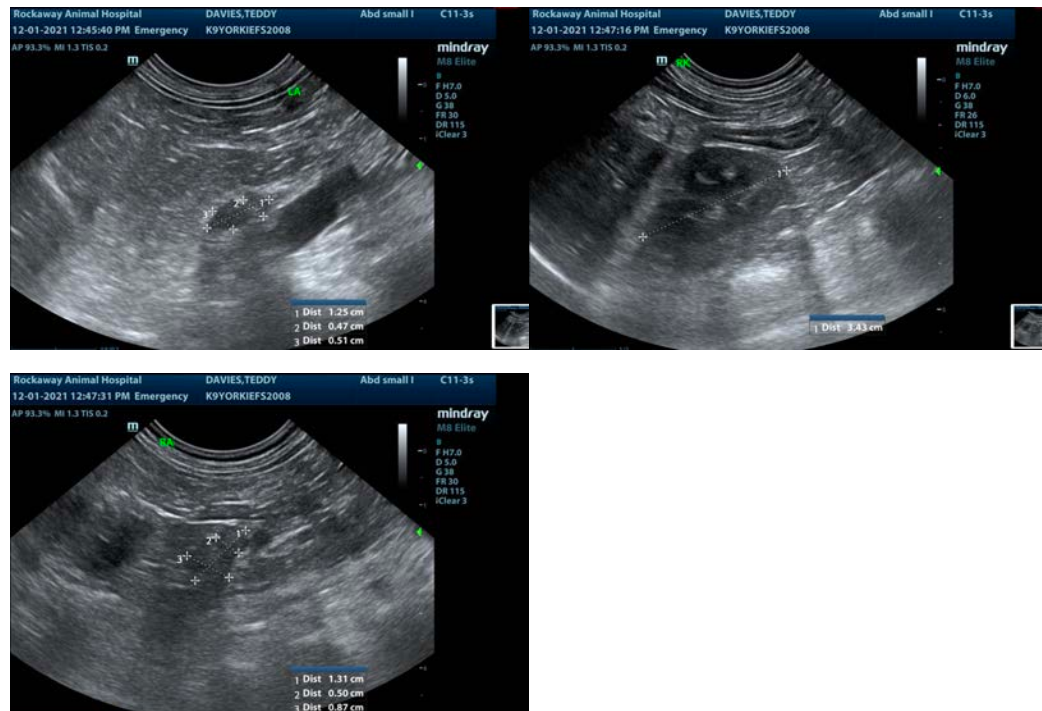
Dr. Maniar

INVOICE

33133

DATE

12/1/21



The information and recommendations provided are based on the images presented by the referring veterinarian. No evaluation can be communicated regarding pathology that was not visible in the image/video clips provided.

Thank you for this referral. If the clinical or image interpretation does not parallel your findings or if I can be of any further assistance please contact me.

Eric Lindquist, DMV, DABVP, Cert. IVUSS, CEO of SonoPath.com
info@SonoPath.com