



PATIENT PRESENTING CLINICAL SIGNS

Simon O'Beirne Anorexic and vomiting. Current meds: Cerenia inj. , SQF.
Abnormal PE/Chem/CBC/UA Results: ALT 305 (130H); Bili 1.8 (0.9H); U/A- elevated bilirubin.

SPECIES ULTRASONOGRAPHIC EXAMINATION OF THE ABDOMEN

Feline

Urinary System

BREED

DSH

The **urinary bladder**, trigone, and pelvic urethra presented normal thicknesses and normal tone. The ureters were not visible which is normal. No uroliths or sediment were visualized and anechoic urine was present. No evidence of inflammatory or neoplastic changes were noted. Ureteral papillae were normal. The pelvic urethra was imaged 2.0 cm beyond the cystourethral junction.

SEX

Neutered Male

The **right kidney** presented a chronic interstitial nephrosis pattern with caudal infarct. The right kidney measured 3.37 cm.

AGE

13 Years

The **left kidney** was enlarged at 5.62 cm with pelvic mineralization and loss of corticomedullary definition. Subnormal vascularity noted on power doppler assessment.

Adrenal Glands

WEIGHT

11 Pounds

Both **adrenal glands** were visualized and recognized as having normal shape, size, position and echogenicity for this breed. The phrenic vasculature, glandular echogenicity and detail were unremarkable. Capsule, cortex, and medullary definition were normal for this age patient. The left adrenal gland measured 0.5 cm. The right adrenal gland measured 0.52 cm.

Spleen

INTERPRETED BY

Eric Lindquist, DMV
DABVP, Cert. IVUSS

The **spleen** was slightly enlarged at 0.97 cm, otherwise unremarkable.

Liver

IMAGING PERFORMED BY

Shari Reffi, CVT

The **liver** presented swollen irregular contour. The gallbladder was overdistended. The common bile duct was dilated at 0.64 cm with thickening at the termination of the common bile to the duodenal papilla. Lobar biliary duct dilation also noted, consistent with post-hepatic obstruction. Minor gallbladder sand present. The cystic duct was tortuous.

Gastrointestinal

HOSPITAL NAME

Animal Mansion

Examination of the **gastrointestinal tract** revealed a stomach and intestine free of stasis, of normal wall thickness, acceptable curvilinear mural detail, and peristaltic activity. Small and large intestine demonstrated normal luminal chyme and stool consistency respectively. No obstructive or overt infiltrative disease was noted. No associated abnormal lymphatic activity was noted.

REFERRING VET

Dr. Parker

Pancreas

INVOICE

33138

The **pancreas** was hypoechoic and irregular in the left limb. Regional inflammation noted around the left limb, which extended caudally owing to generalized swelling. Dilated duct noted at 0.2 cm. The right limb measured 1.18 cm.

ULTRASONOGRAPHIC FINDINGS

DATE

12/1/21

- Swollen spleen and liver with post-hepatic obstruction owing to mucoduct, possible embedded calculus, or concurrent pancreatic pathology.
- Concurrent pancreatitis



PATIENT

Simon O'Beirne

SPECIES

Feline

BREED

DSH

SEX

Neutered Male

AGE

13 Years

WEIGHT

11 Pounds

INTERPRETED BY

Eric Lindquist, DMV
DABVP, Cert. IVUSS

IMAGING PERFORMED BY

Shari Reffi, CVT

HOSPITAL NAME

Animal Mansion

REFERRING VET

Dr. Parker

INVOICE

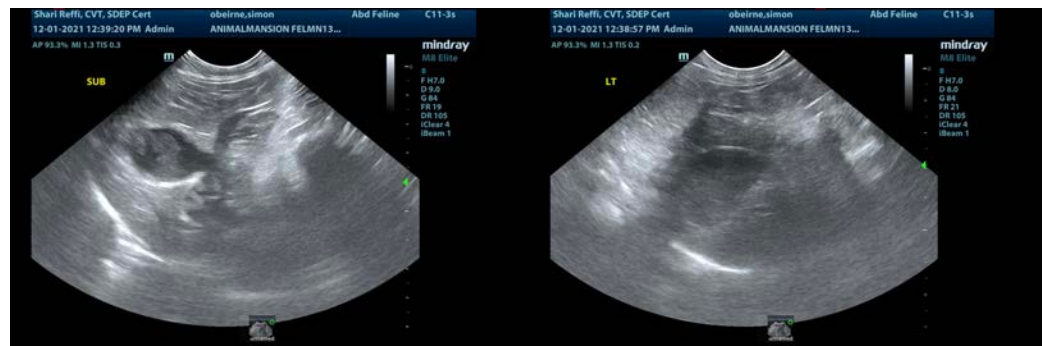
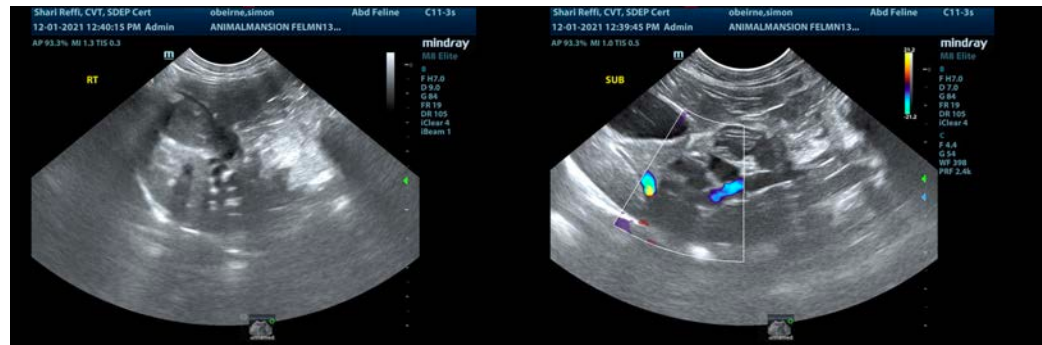
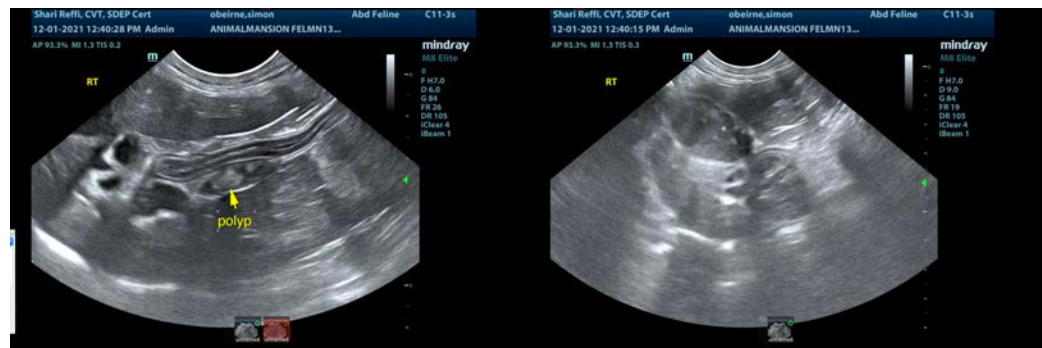
33138

DATE

12/1/21

INTERPRETATION OF THE FINDINGS & FURTHER RECOMMENDATIONS

Ultrasound guided FNA of the spleen, pancreas and liver warranted for cursory evaluation. However, if the aspirates are benign and non-neoplastic, then cholecystectomy and common bile duct lavage +/- biliary duct deviation procedure would be appropriate. The thickening at the termination of the common bile duct may represent inflammatory polyp or possible biliary carcinoma, and measures approximately 1.0 cm x 0.5 cm. Guarded prognosis. If surgery is to be performed, resection of the left limb of the pancreas may be appropriate.





PATIENT

Simon O'Beirne

SPECIES

Feline

BREED

DSH

SEX

Neutered Male

AGE

13 Years

WEIGHT

11 Pounds

INTERPRETED BY

Eric Lindquist, DMV
DABVP, Cert. IVUSS

IMAGING PERFORMED BY

Shari Reffi, CVT

HOSPITAL NAME

Animal Mansion

REFERRING VET

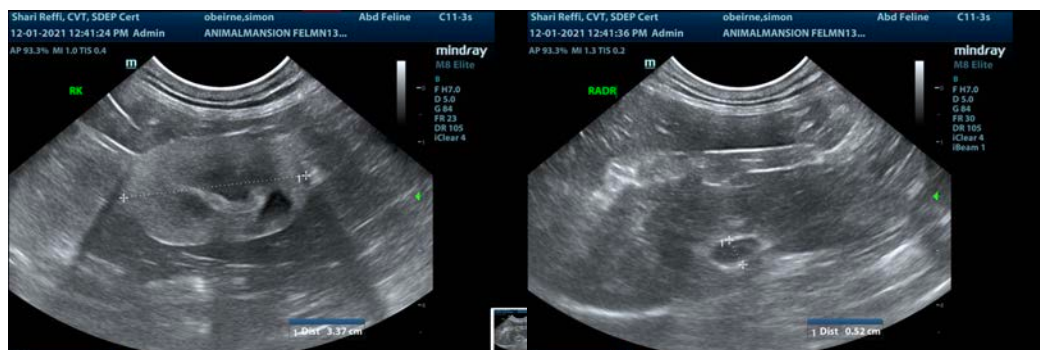
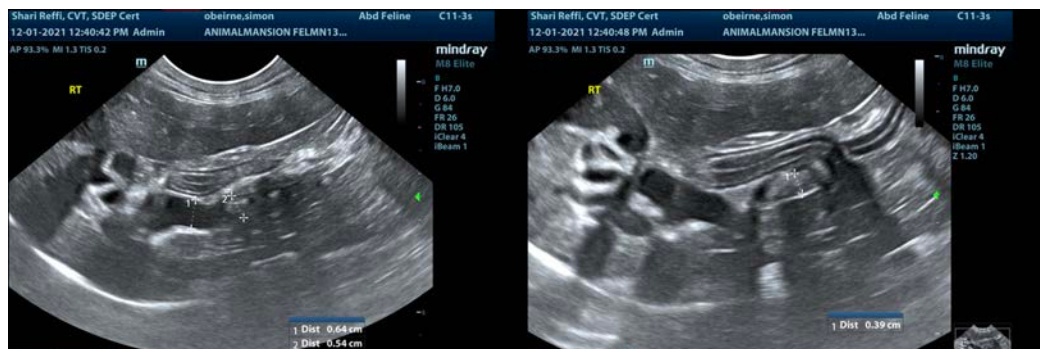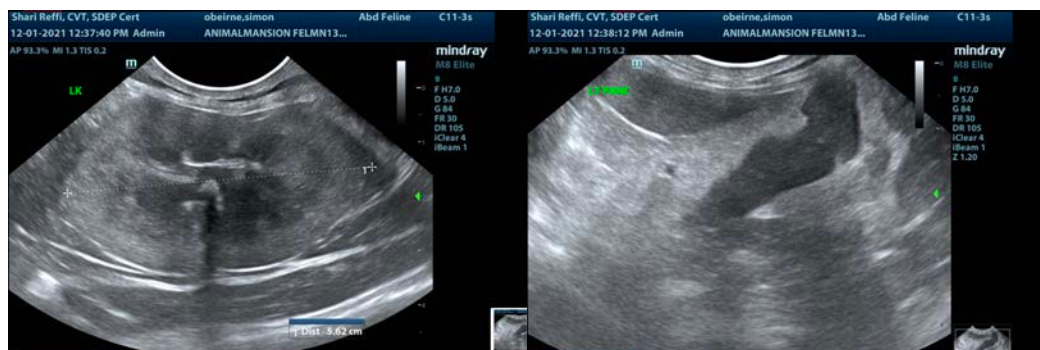
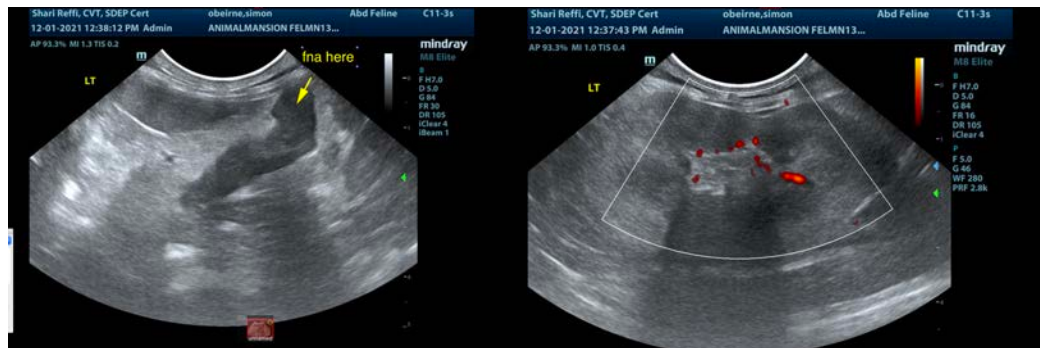
Dr. Parker

INVOICE

33138

DATE

12/1/21





PATIENT

Simon O'Beirne

SPECIES

Feline

BREED

DSH

SEX

Neutered Male

AGE

13 Years

WEIGHT

11 Pounds

INTERPRETED BY

Eric Lindquist, DMV
DABVP, Cert. IVUSS

IMAGING PERFORMED BY

Shari Reffi, CVT

HOSPITAL NAME

Animal Mansion

REFERRING VET

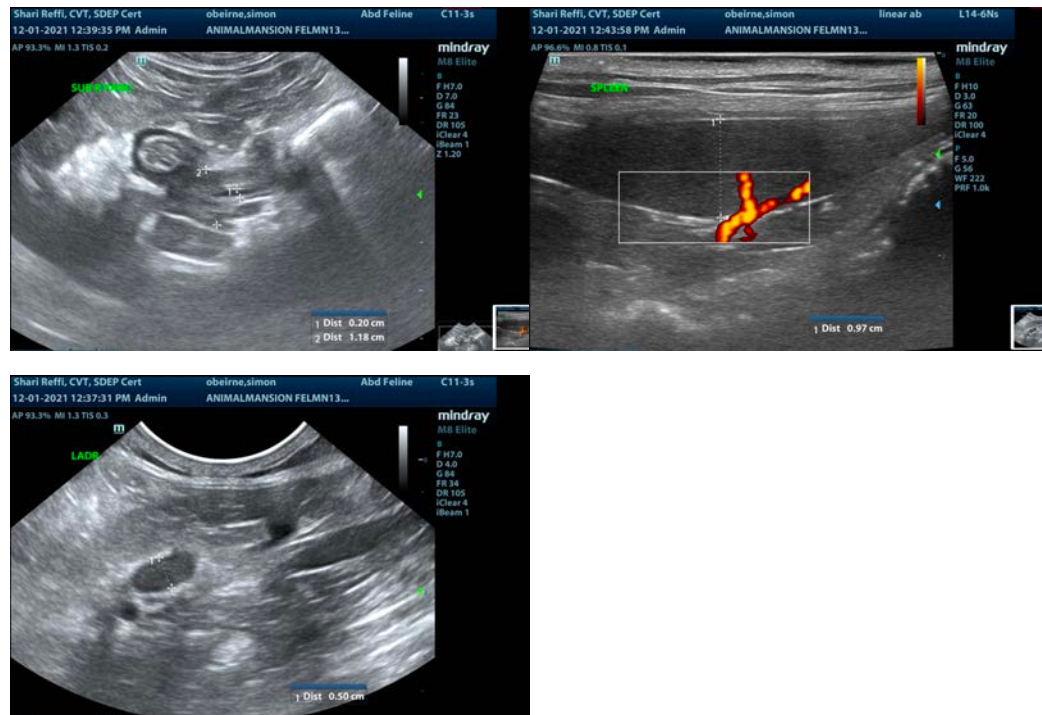
Dr. Parker

INVOICE

33138

DATE

12/1/21



The information and recommendations provided are based on the images presented by the referring veterinarian. No evaluation can be communicated regarding pathology that was not visible in the image/video clips provided.

Thank you for this referral. If the clinical or image interpretation does not parallel your findings or if I can be of any further assistance please contact me.

Eric Lindquist, DMV, DABVP, Cert. IVUSS, CEO of SonoPath.com
info@SonoPath.com