

PATIENT

Loki Garg

SPECIES

Canine

BREED

Husky

SEX

Neutered male

AGE

12 years

WEIGHT

61 lbs

PRESENTING CLINICAL SIGNS

History: Follow up cervical ultrasound after abdominal scan last week.

Abnormal PE/Chem/CBC/UA Results: Please see attached malignancy panel results. Previous aus read last week by Beth Johnson, DVM, DACVIM

ULTRASONOGRAPHIC EXAMINATION

Both thyroid regions were imaged in this patient. The left thyroid lobe revealed a 0.71 cm cyst at the mid body with minor, heterogenous changes noted in the thyroid lobe itself. This is consistent with remodeling. The right thyroid lobe revealed a 0.62 x 0.8 cm nodule at the mid body. This is consistent with parathyroid adenoma. The normal appearing parathyroids in the cranial aspect of the right lobe measured 0.3 cm and 0.2 cm. The left thyroid lobe structure is cystic owing to lack of color flow uptake on Doppler assessment. Normal parathyroids are evident at approximately 0.2-0.3 cm each. The right parathyroid presumed adenoma can be confirmed with ultrasound-guided FNA, 25-gauge recommended. At the same time the left thyroid cyst can be drained with cytology analysis and culture.

ULTRASONOGRAPHIC FINDINGS

Left thyroid cyst, likely benign.

Mild bilateral thyroid remodeling.

Right medial parathyroid adenoma type lesion.

INTERPRETED BY

Eric Lindquist, DMV
DABVP, Cert. IVUSS

INTERPRETATION OF THE FINDINGS & FURTHER RECOMMENDATIONS

Further definition with ultrasound-guidance of both lesions or direct surgical intervention upon the right parathyroid is recommended.

IMAGING PERFORMED BY

Amy Mayhew LVT

HOSPITAL NAME

SVS Imaging Michigan

REFERRING VET

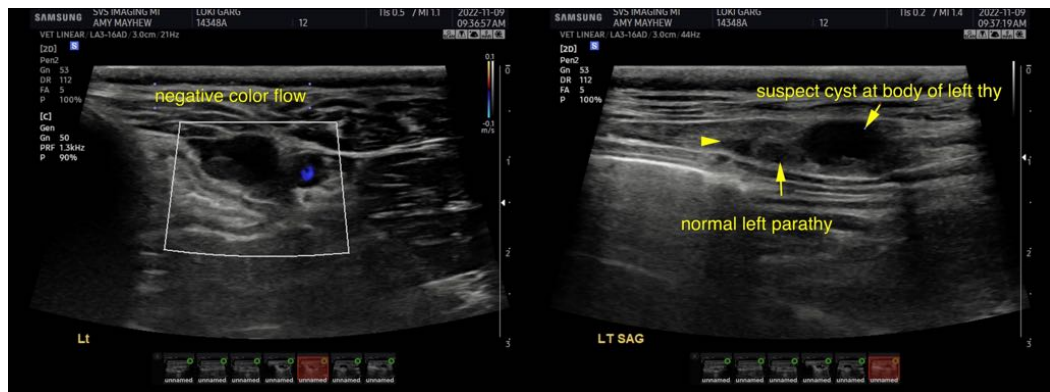
Wixom Family Pet Practice

INVOICE

42407

DATE

10/9/22



IMAGING PERFORMED BY

SVS Mobile Imaging MI 734-637-7711
svsimagingmi@gmail.com



PATIENT

Loki Garg

SPECIES

Canine

BREED

Husky

SEX

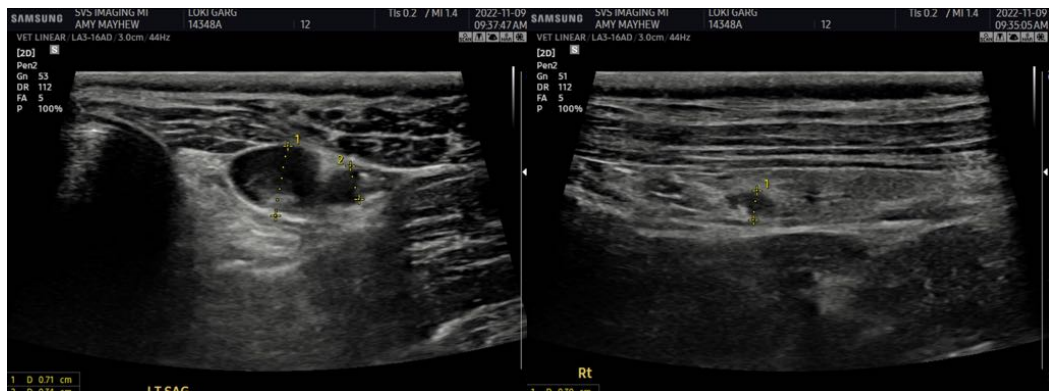
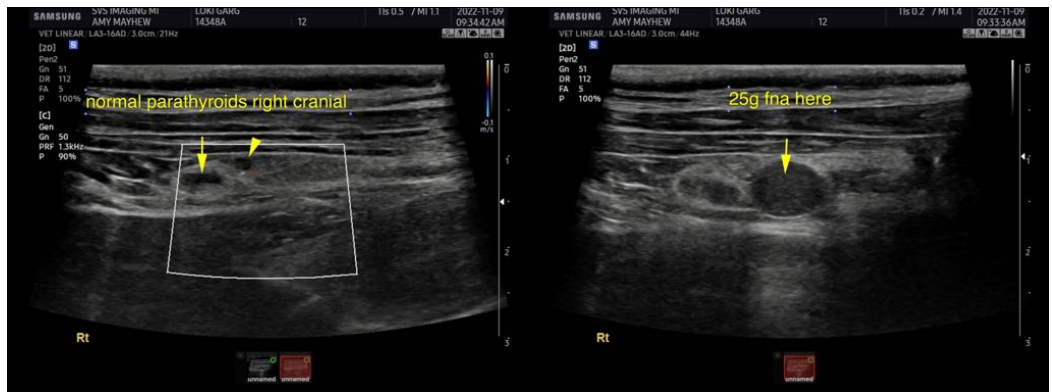
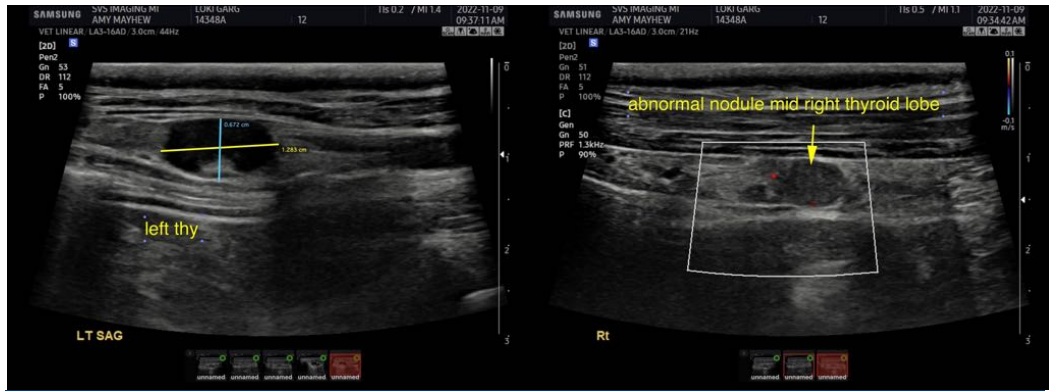
Neutered male

AGE

12 years

WEIGHT

61 lbs



INTERPRETED BY

Eric Lindquist, DMV
DABVP, Cert. IVUSS

IMAGING PERFORMED BY

Amy Mayhew LVT

HOSPITAL NAME

SVS Imaging Michigan

REFERRING VET

Wixom Family Pet
Practice

INVOICE

42407

DATE

10/9/22

The information and recommendations provided are based on the images presented by the referring veterinarian/sonographer. No evaluation can be communicated regarding pathology that was not visible in the image/video clips provided.

Thank you for this referral. If the clinical or image interpretation does not parallel your findings or if I can be of any further assistance please contact me.

Eric Lindquist, DMV, DABVP, Cert. IVUSS, CEO of SonoPath.com
Eric.Lindquist@SonoPath.com