

PATIENT

Mylo Deuesus

SPECIES

Canine

BREED

Jack Russell Terrier

SEX

Neutered Male

AGE

20

WEIGHT

18

INTERPRETED BY

Eric Lindquist, DMV
DABVP, Cert. IVUSS

IMAGING PERFORMED BY

Jenn

HOSPITAL NAME

Rockaway AH

REFERRING VET

Dr. Panchal

INVOICE

17920

DATE

11/8/22

PRESENTING CLINICAL SIGNS

History: hematuria, inappropriate urination

Abnormal PE/Chem/CBC/UA Results: proteinuria bacteriuria struvites SG 1.020

ULTRASONOGRAPHIC EXAMINATION OF THE ABDOMEN

Urinary System

The **urinary bladder** presented a relatively uniform thickening of the cranioventral and craniodorsal mucosae with micropolypoid mucosal changes without involvement of the submucosae. A minimal amount of urine was present. The urine presented some echogenicity consistent with suspended debris. No evidence of urethral pathology was present. This presentation is most consistent with chronic cystitis. Technically transitional cell carcinoma cannot be ruled out without histopathological review but is not overtly suspected based on this pattern. Cystocentesis and urine culture +/- pathological review of urine cytology would be warranted. No overt calculi were present at this time.

The **kidneys** revealed largely normal size and structure, corticomedullary definition and ratio (cortex 1/3 of medulla) were essentially maintained with some age-related loss of curvilinear patterns regarding the capsule and C/M junction. The cortices presented largely uniform texture with some increased echogenicity expected for his age patient. Medullary structure differed distinctly from that of the cortex and no evidence of pelvic dilation was present. The right kidney measured 4.6 cm. The left kidney measured 3.65 cm.

Adrenal Glands

The **left adrenal gland** comprised a mass. The left adrenal gland measured 3.5 cm x 1.8 cm at the caudal pole and 1.7 cm at the cranial pole. The left adrenal mass deviated the left kidney dorsally. Capsular expansion was noted without capsular escape or vascular invasion.

The **right adrenal gland** was visualized and recognized as having normal shape, size, position and echogenicity for this breed. The phrenic vasculature, glandular echogenicity and detail were unremarkable. Capsule, cortex, and medullary definition were normal for this age patient. The right adrenal gland measured 3.13 cm x 1.14 cm at the caudal pole and 1.1 cm at the cranial pole.

Spleen

The **spleen** presented a smooth homogeneous parenchyma hyperechoic to liver and renal cortical parenchyma. The capsule was smooth without noticeable expansion or deviation from within the spleen or adjacent pathology. The splenic vasculature demonstrated normal volume without signs of congestion or thrombosis. No sonographic evidence of acute or chronic inflammatory, neoplastic, or infarctual changes were noted.

Liver

The **liver** images from right and left intercostal as well as subcostal views revealed subjectively normal liver size, contour, and structure. Some moderate age-related parenchymal remodeling was noted but likely not clinically significant at this time. Vascular and biliary tracts were of normal volume and no evidence of congestion was noted. The gallbladder presented some dependent debris with essentially normal contour. The cystic and common bile ducts were normal. No overt evidence of active inflammatory, infiltrative or regenerative pathology was noted but should be paired with current or



PATIENT

Mylo Deuesus

past LE elevations regarding any clinical significance to this presentation. The hepatic lymph nodes were unremarkable. Occasional parenchymal cysts were noted, not pathological, expected changes for this age patient.

SPECIES

Canine

Gastrointestinal

Examination of the **gastrointestinal tract** revealed a stomach and intestine free of stasis, of normal wall thickness, acceptable curvilinear mural detail, and peristaltic activity. Small and large intestine demonstrated normal luminal chyme and stool consistency respectively. No obstructive or overt infiltrative disease was noted. No associated abnormal lymphatic activity was noted.

BREED

Jack Russell Terrier

SEX

Neutered Male

Pancreas

The base and limbs of the **pancreas** were observed to be largely isoechoic to surrounding omental fat. Pancreatic duct and capsular contour were acceptably normal and parenchyma respected normal curvilinear patterns. No overt evidence of active inflammatory or neoplastic disease was noted.

AGE

20

ULTRASONOGRAPHIC FINDINGS

- Left adrenal mass. Pheochromocytoma versus carcinoma
- Chronic cystitis bladder pattern, minor potential for bladder neoplasia
- Moderate degenerative renal changes
- Mild to moderate degenerative hepatic changes with occasional parenchyma cysts

WEIGHT

18

INTERPRETATION OF THE FINDINGS & FURTHER RECOMMENDATIONS

Blood pressure measurements are warranted. If hypertension is present, then urine catecholamine is indicated. Left adrenalectomy would be ideal with bladder biopsy. Urine culture and sensitivity is indicated. Empirical treatment for chronic cystitis is warranted.

INTERPRETED BY

Eric Lindquist, DMV
DABVP, Cert. IVUSS

IMAGING PERFORMED BY

Jenn

HOSPITAL NAME

Rockaway AH

REFERRING VET

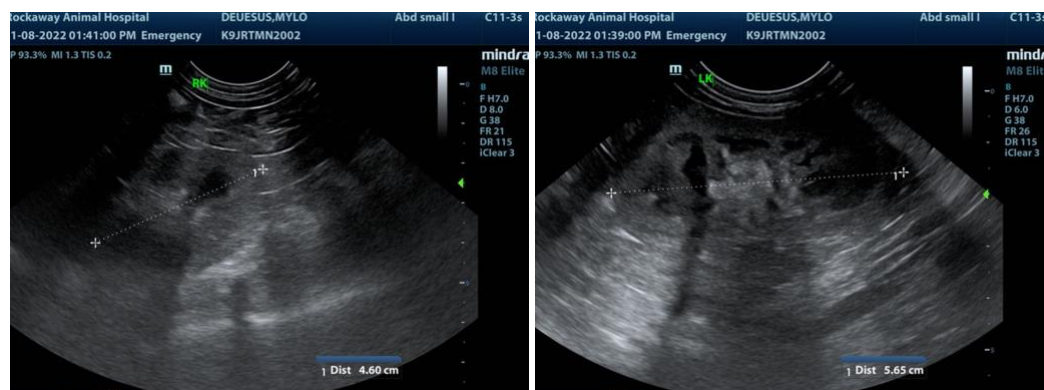
Dr. Panchal

INVOICE

17920

DATE

11/8/22





PATIENT

Mylo Deesus

SPECIES

Canine

BREED

Jack Russell Terrier

SEX

Neutered Male

AGE

20

WEIGHT

18

INTERPRETED BY

Eric Lindquist, DMV
DABVP, Cert. IVUSS

IMAGING PERFORMED BY

Jenn

HOSPITAL NAME

Rockaway AH

REFERRING VET

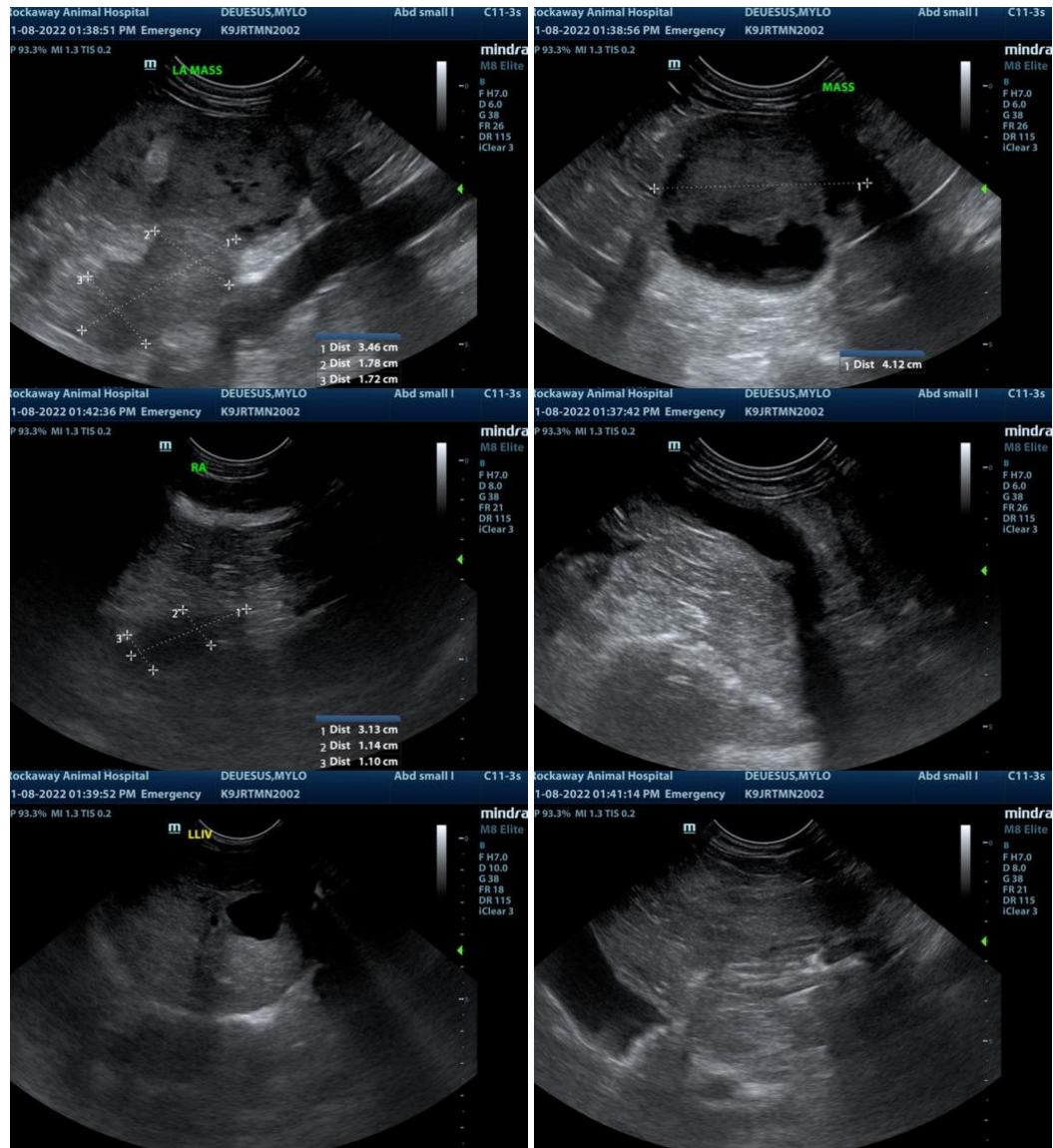
Dr. Panchal

INVOICE

17920

DATE

11/8/22



The information and recommendations provided are based on the images presented by the referring veterinarian. No evaluation can be communicated regarding pathology that was not visible in the image/video clips provided.

Thank you for this referral. If the clinical or image interpretation does not parallel your findings or if I can be of any further assistance please contact me.

Eric Lindquist, DMV, DABVP, Cert. IVUSS, CEO of SonoPath.com
info@SonoPath.com