



PATIENT

Honey DiPasquale

SPECIES

Canine

BREED

Terrier Mix

SEX

Spayed female

AGE

9 years

WEIGHT

16 lbs

INTERPRETED BY

Eric Lindquist, DMV
DABVP, Cert. IVUSS

IMAGING PERFORMED BY

Jenn

HOSPITAL NAME

Rockaway AH

REFERRING VET

Dr. Maniar

INVOICE

42381

DATE

11/8/22

PRESENTING CLINICAL SIGNS

History: Hx of diabetes not eating shaking hiding in the corner

ULTRASONOGRAPHIC EXAMINATION OF THE ABDOMEN

Urinary System

The **urinary bladder**, trigone, and pelvic urethra presented normal thicknesses and normal tone. The ureters were not visible which is normal. No uroliths or sediment were visualized and anechoic urine was present. No evidence of inflammatory or neoplastic changes was noted. Ureteral papillae were normal.

The **kidneys** were normal in size and contour; however, a minor hyperechoic ring was noted at the corticomedullary junction. This is consistent with diabetic nephropathy. This is likely from glucosuria. However, assessment for proteinuria is also warranted. This is an idiopathic finding, but an expected finding in diabetic patients. The right kidney measured 4.95 cm. The left kidney measured 4.64 cm with slight pyelectasia.

Adrenal Glands

Both **adrenal glands** were visualized and recognized as having normal shape, size, position and echogenicity for this breed. The phrenic vasculature, glandular echogenicity and detail were unremarkable. Capsule, cortex, and medullary definition were normal for this age patient.

Spleen

The **spleen** presented a smooth homogeneous parenchyma hyperechoic to liver and renal cortical parenchyma. The capsule was smooth without noticeable expansion or deviation from within the spleen or adjacent pathology. The splenic vasculature demonstrated normal volume without signs of congestion or thrombosis. No sonographic evidence of acute or chronic inflammatory, neoplastic, or infarctual changes was noted.

Liver

The **liver** in this patient was mildly enlarged and uniform with hyperechoic parenchymal changes. There were subtle, hypoechoic heterogenous nodular changes. The gallbladder and common bile duct were unremarkable other than a minor amount of gallbladder sludge/debris.

Gastrointestinal

Examination of the **gastrointestinal tract** revealed a stomach and intestine free of stasis, of normal wall thickness, acceptable curvilinear mural detail, and peristaltic activity. Small and large intestine demonstrated normal luminal chyme and stool consistency respectively. No obstructive or overt infiltrative disease was noted. No associated abnormal lymphatic activity was noted.



PATIENT

Honey DiPasquale

SPECIES

Canine

BREED

Terrier Mix

SEX

Spayed female

AGE

9 years

WEIGHT

16 lbs

INTERPRETED BY

Eric Lindquist, DMV
DABVP, Cert. IVUSS

IMAGING PERFORMED BY

Jenn

HOSPITAL NAME

Rockaway AH

REFERRING VET

Dr. Maniar

INVOICE

42381

DATE

11/8/22

Pancreas

The base and limbs of the **pancreas** were observed to be largely isoechoic to surrounding omental fat. Pancreatic duct and capsular contour were acceptably normal and parenchyma respected normal curvilinear patterns. No overt evidence of active inflammatory or neoplastic disease was noted.

ULTRASONOGRAPHIC FINDINGS

Diabetic hepatopathy.

Diabetic nephropathy.

Otherwise, unremarkable abdomen.

INTERPRETATION OF THE FINDINGS & FURTHER RECOMMENDATIONS

Potential Causes of Diabetic Dysregulation

This is a suggestive checkoff list when faced with an unregulated diabetic patient:

- UTI
- Dietary indiscretion/intolerance
- Pancreatitis
- Hyperthyroidism/hypothyroidism
- Exogenous steroids (including topical eye meds)
- Cushing's
- Acromegaly
- Owner compliance
- Insulin quality issues
- Antibodies to insulin
- Underlying Neoplasia
- Diffuse liver disease



PATIENT

Honey DiPasquale

SPECIES

Canine

BREED

Terrier Mix

SEX

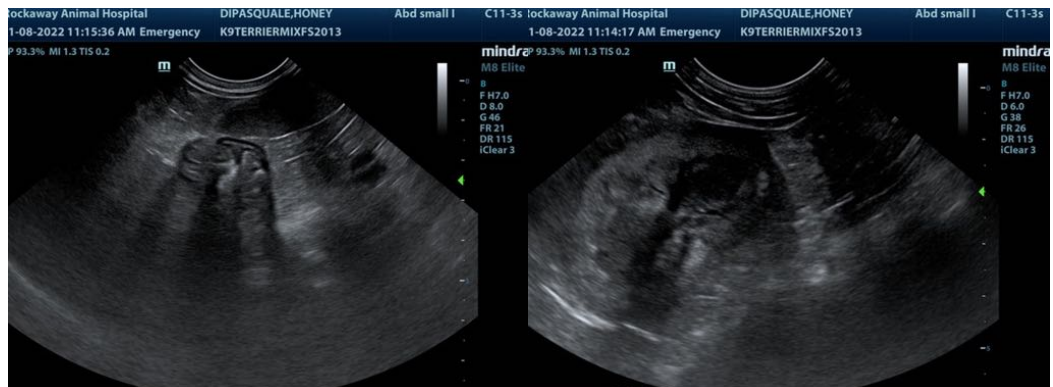
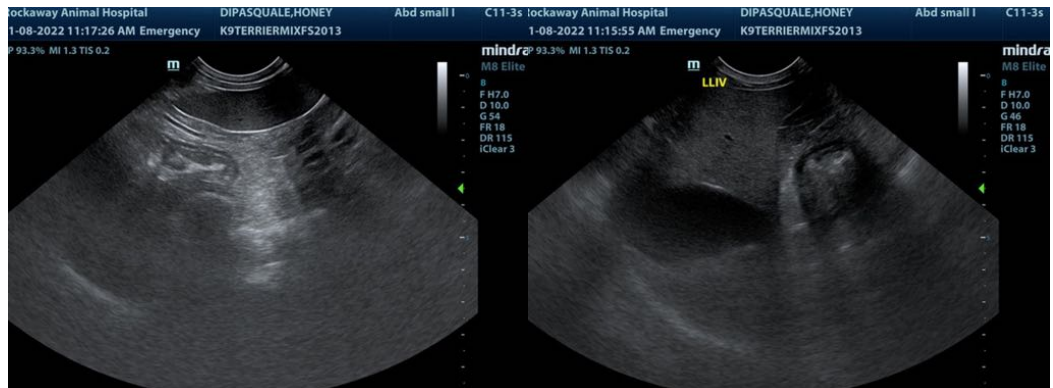
Spayed female

AGE

9 years

WEIGHT

16 lbs



INTERPRETED BY

Eric Lindquist, DMV
DABVP, Cert. IVUSS

IMAGING PERFORMED BY

Jenn

HOSPITAL NAME

Rockaway AH

REFERRING VET

Dr. Maniar

INVOICE

42381

DATE

11/8/22

The information and recommendations provided are based on the images presented by the referring veterinarian/sonographer. No evaluation can be communicated regarding pathology that was not visible in the image/video clips provided.

Thank you for this referral. If the clinical or image interpretation does not parallel your findings or if I can be of any further assistance please contact me.

Eric Lindquist, DMV, DABVP, Cert. IVUSS, CEO of SonoPath.com
info@SonoPath.com