



PATIENT

Balto Wright

SPECIES

Canine

BREED

Miniature Schnauzer

SEX

Neutered male

AGE

12 years

WEIGHT

9.6 lbs

INTERPRETED BY

Eric Lindquist, DMV
DABVP, Cert. IVUSS

**IMAGING
PERFORMED BY**

Dr. Cerf

HOSPITAL NAME

Veterinary Center of
Hardyston

REFERRING VET

Dr. Cerf

INVOICE

42402

DATE

11/8/22

PRESENTING CLINICAL SIGNS

History: Previous ultrasound by Dr. Cali on 8/19/22: 1. Benign mineralization of both kidneys 2. GB sludge 3. 2.8 x 4.4 cm isoechoic "rounding" at the periphery of the left middle liver lobe - most likely a mass.

Bloodwork on 8/19/22 CBC: wnl CHEM: Elevated ALT (155); ALP > 2000

ULTRASONOGRAPHIC EXAMINATION OF THE ABDOMEN

Urinary System

The **urinary bladder**, trigone, and pelvic urethra presented normal thicknesses and normal tone. The ureters were not visible which is normal. No uroliths or sediment were visualized and anechoic urine was present. No evidence of inflammatory or neoplastic changes was noted. Ureteral papillae were normal.

The **kidneys** revealed largely normal size and structure, corticomedullary definition and ratio (cortex 1/3 of medulla) were essentially maintained with some age-related loss of curvilinear patterns regarding the capsule and C/M junction. The cortices presented largely uniform texture with some increased echogenicity expected for his age patient. Medullary structure differed distinctly from that of the cortex and no evidence of pelvic dilation was present. Slight pinpoint mineralization was noted and not clinically significant. The right kidney measured 4.0 cm. The left kidney measured 3.6 cm.

Adrenal Glands

The right **adrenal gland** was visualized and recognized as having normal shape, size, position and echogenicity for this breed. The phrenic vasculature, glandular echogenicity and detail were unremarkable. Capsule, cortex, and medullary definition were normal for this age patient. The right adrenal gland measured 1.06 cm at the cranial pole and 0.62 cm at the caudal pole. The left adrenal gland was subnormal in size and measured 0.3 cm.

Spleen

The **spleen** in this patient was mildly enlarged with uniform parenchyma and was folded upon itself caudally. This is a positional variant and is not pathological. There was no evidence of significant disease.

Liver

The **liver** in this patient revealed a lobar swelling that was deriving from the left medial liver and measured 5.78 x 2.8 cm with minor deviation from normal curvilinear patterns. This is pedunculated and appears resectable. This is most consistent with hepatoma and should be removed as it is at risk for torsion. However, this is likely benign from a histopathological standpoint. Bridge from normal liver to the lobar swelling/mass measured approximately 2.0 cm with significant vascularity. Lobar torsion was noted. The remainder of the liver revealed uniform, vacuolar hepatopathy pattern with minor gallbladder debris.



PATIENT

Gastrointestinal

Balto Wright

The **stomach** presented a large amount of granular material in the gastric fundus. The small intestines and colon were unremarkable.

SPECIES

Canine

Pancreas

BREED

Miniature Schnauzer

The base and limbs of the **pancreas** were observed to be largely isoechoic to surrounding omental fat. Pancreatic duct and capsular contour were acceptably normal and parenchyma respected normal curvilinear patterns. No overt evidence of active inflammatory or neoplastic disease was noted.

SEX

Neutered male

ULTRASONOGRAPHIC FINDINGS

Lobar liver mass, likely hepatoma. This is pedunculated and at risk for torsion.

Over distended stomach with gastric fundic material.

AGE

12 years

INTERPRETATION OF THE FINDINGS & FURTHER RECOMMENDATIONS

FNA of the liver can be considered for further definition or direct removal. CT evaluation would be ideal for surgical planning is recommended. There is no overt contraindication to anesthetic procedure; however, the liver mass and potential gastric material should be addressed surgically.

WEIGHT

9.6 lbs

INTERPRETED BY

Eric Lindquist, DMV
DABVP, Cert. IVUSS

IMAGING PERFORMED BY

Dr. Cerf

HOSPITAL NAME

Veterinary Center of Hardyston

REFERRING VET

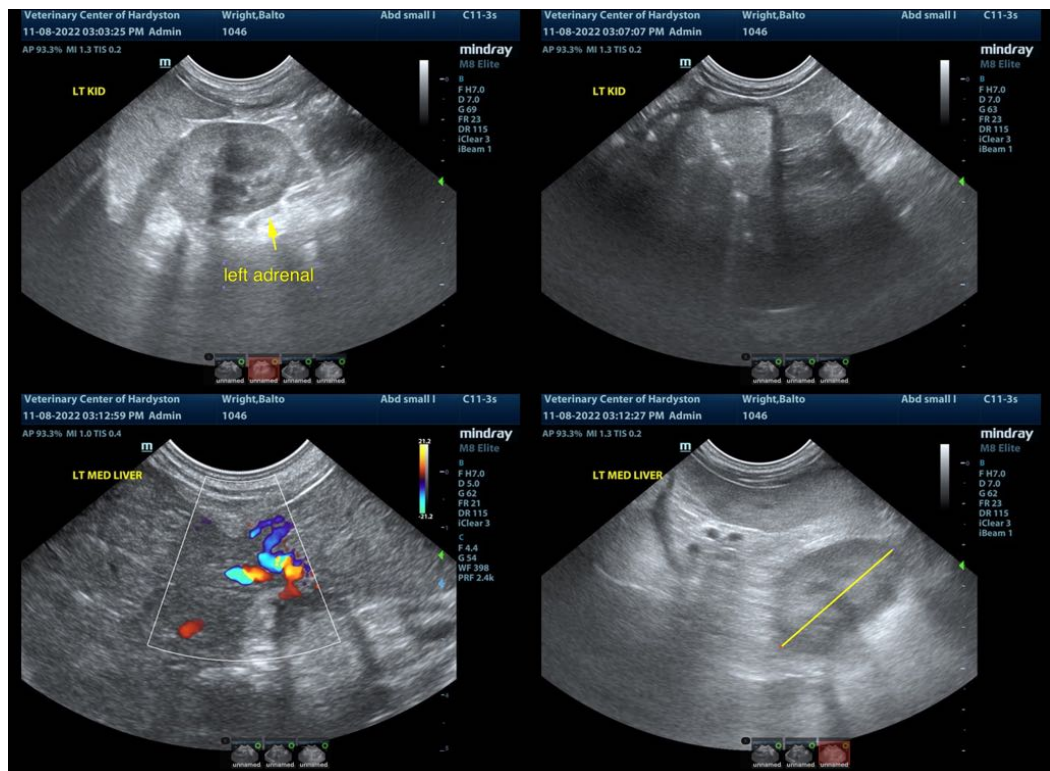
Dr. Cerf

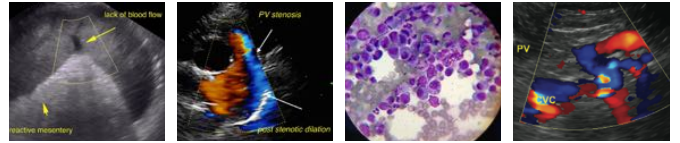
INVOICE

42402

DATE

11/8/22





PATIENT

Balto Wright

SPECIES

Canine

BREED

Miniature Schnauzer

SEX

Neutered male

AGE

12 years

WEIGHT

9.6 lbs

INTERPRETED BY

Eric Lindquist, DMV
DABVP, Cert. IVUSS

IMAGING PERFORMED BY

Dr. Cerf

HOSPITAL NAME

Veterinary Center of Hardyston
Hardyston

REFERRING VET

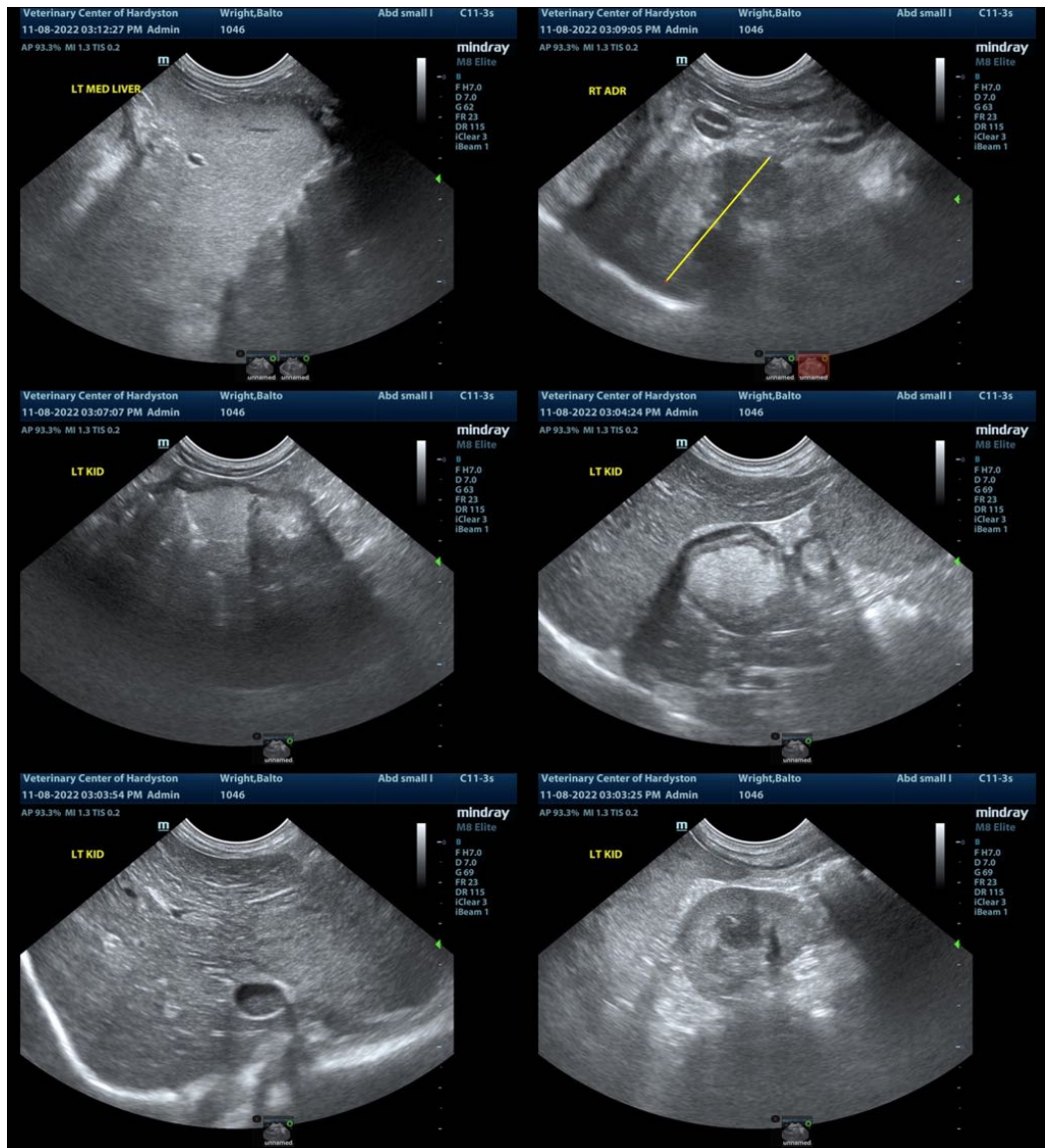
Dr. Cerf

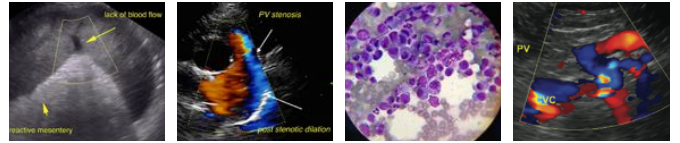
INVOICE

42402

DATE

11/8/22





PATIENT

Balto Wright

SPECIES

Canine

BREED

Miniature Schnauzer

SEX

Neutered male

AGE

12 years

WEIGHT

9.6 lbs

INTERPRETED BY

Eric Lindquist, DMV
DABVP, Cert. IVUSS

IMAGING PERFORMED BY

Dr. Cerf

HOSPITAL NAME

Veterinary Center of
Hardyston

REFERRING VET

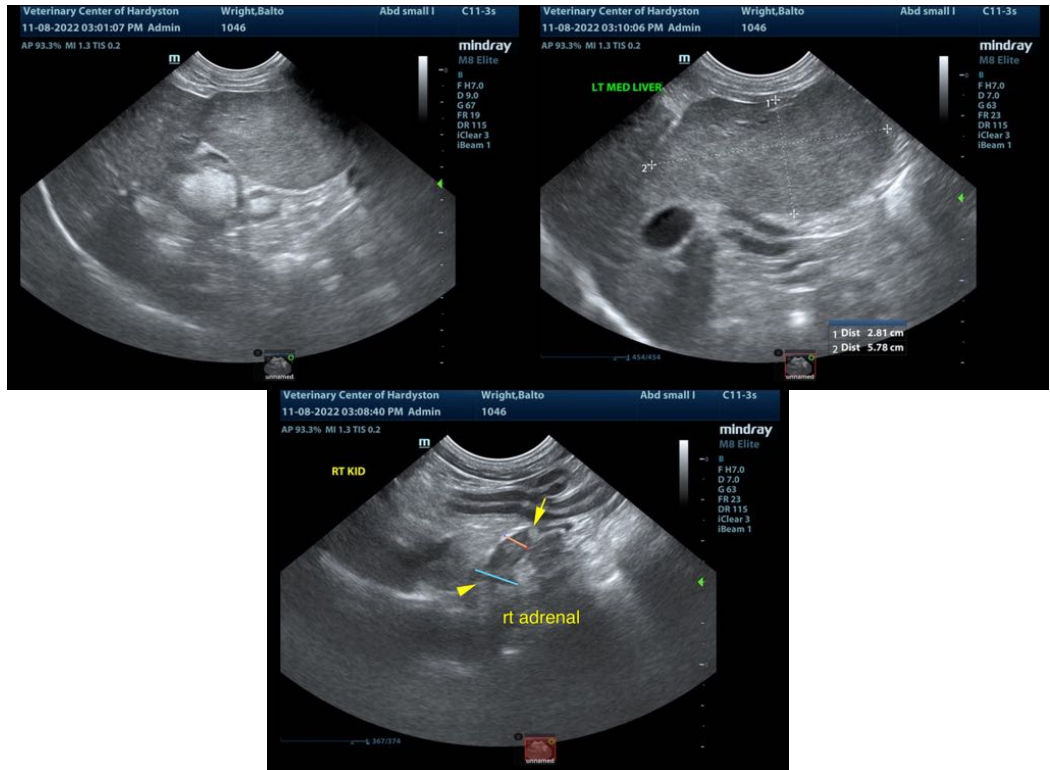
Dr. Cerf

INVOICE

42402

DATE

11/8/22



The information and recommendations provided are based on the images presented by the referring veterinarian/sonographer. No evaluation can be communicated regarding pathology that was not visible in the image/video clips provided.

Thank you for this referral. If the clinical or image interpretation does not parallel your findings or if I can be of any further assistance please contact me.

Eric Lindquist, DMV, DABVP, Cert. IVUSS, CEO of SonoPath.com
info@SonoPath.com