



PATIENT

Sven Farringer

SPECIES

Feline

BREED

DSH

SEX

Neutered Male

AGE

8

WEIGHT

5.94

INTERPRETED BY

Eric Lindquist, DMV,
DABVP (CFM), Cert.
IVUS

IMAGING PERFORMED BY

Masha Axenoff, DVM

HOSPITAL NAME

Wilvet South

REFERRING VET

Masha Axenoff, DVM

INVOICE

71660

DATE

11/7/25

PRESENTING CLINICAL SIGNS

Hx of kidney issues 5+ years ago; unk specifics per O. O out of town for 1 week, pt started inappropriate urination and lethargy. Abnormal behavior changes including increased affection. During a belly rub, which pt never does, O noticed abdomen felt tense and when it was touched, pt hissed and attempted to bite O.

LIMITED ULTRASONOGRAPHIC EXAMINATION

Urinary System

The urinary bladder was unremarkable.

The left kidney presented a 2.0 cm anechoic cyst with adjacent calculi of 0.58 cm and 0.44 cm, non-obstructive. The left kidney measured 3.8 cm in length. Mild to moderate degenerative cortical changes noted with infarcts. The cortical cyst may be secondary to calculi movement.

The right kidney presented dystrophic mineralization, infarcts, and pyelectasia. Regional pelvic inflammation noted. The right kidney measured 4.3 cm. The largest calculus measured 0.47 cm.

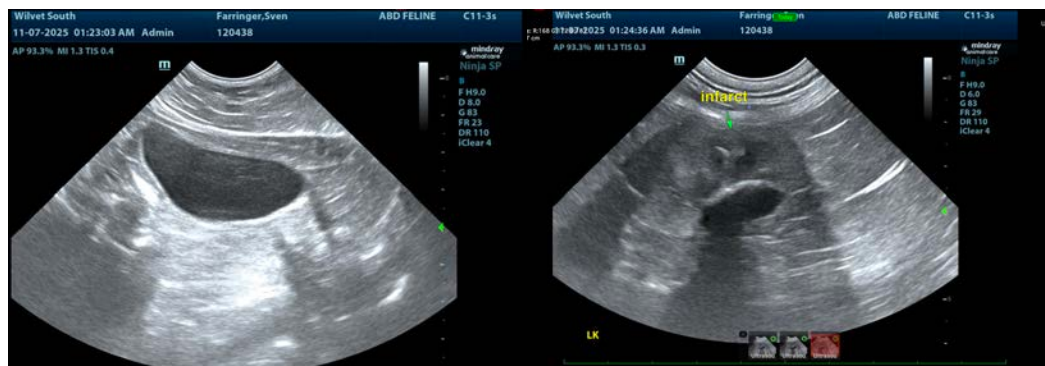
Color flow assessment of the kidneys appeared mildly subnormal.

ULTRASONOGRAPHIC FINDINGS

- Nephrolithiasis, infarcts, pyelectasia, and potential infection of the right kidney with moderate degenerative changes.
- Left kidney calculi and infarcts with secondary cortical cyst.

INTERPRETATION OF THE FINDINGS & FURTHER RECOMMENDATIONS

Full urinary workup warranted. 72-hour IV fluid protocol indicated. The patient may be passing calculi periodically. Palpation of the kidneys warranted to assess particularly any pain in the region of the right kidney.





PATIENT

Sven Farringer

SPECIES

Feline

BREED

DSH

SEX

Neutered Male

AGE

8

WEIGHT

5.94

INTERPRETED BY

Eric Lindquist, DMV,
DABVP (CFM), Cert.
IVUSS

**IMAGING
PERFORMED BY**

Masha Axenoff, DVM

HOSPITAL NAME

Wilvet South

REFERRING VET

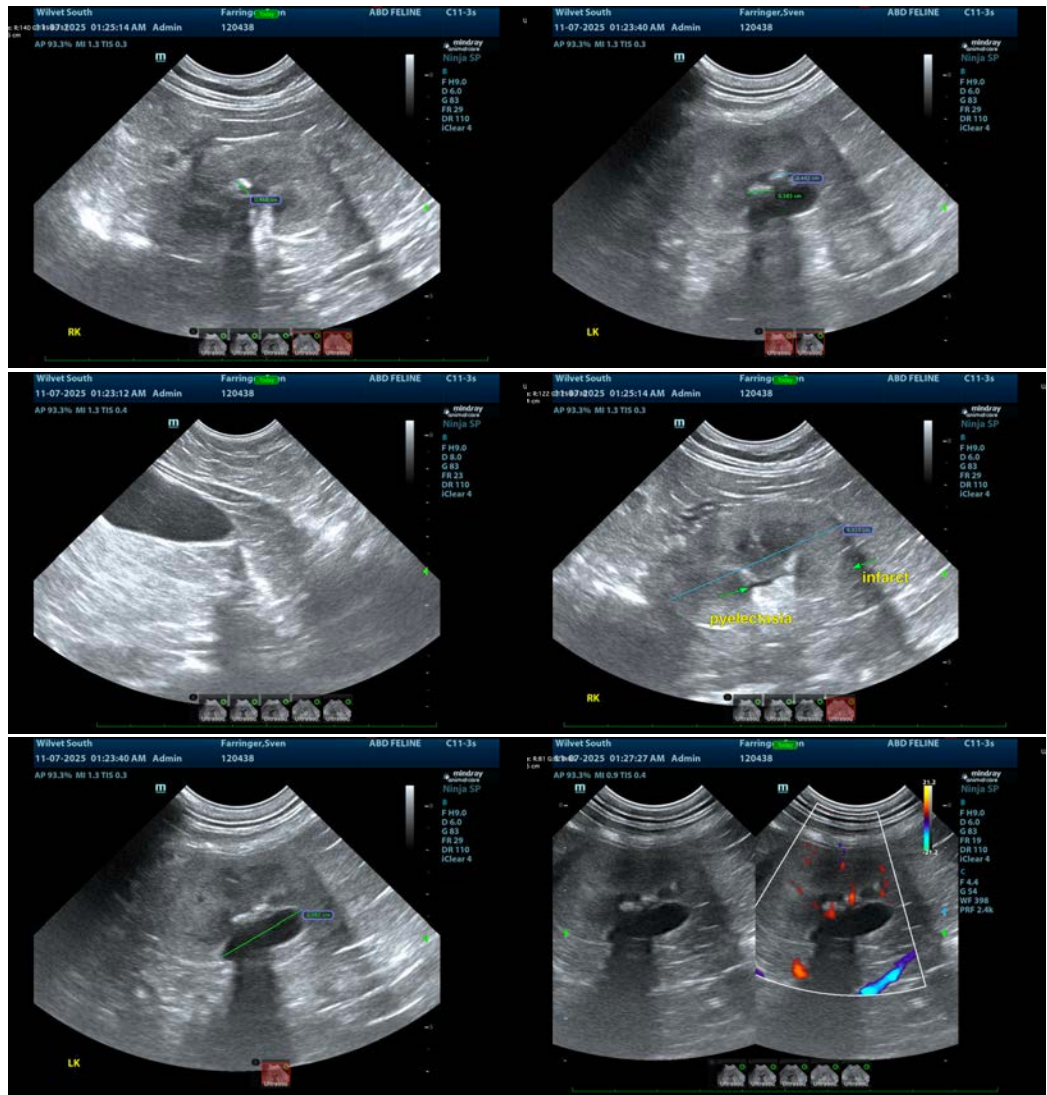
Masha Axenoff, DVM

INVOICE

71660

DATE

11/7/25



The information and recommendations provided are based on the images presented by the referring veterinarian/sonographer. No evaluation can be communicated regarding pathology that was not visible in the image/video clips provided.

Thank you for this referral. If the clinical or image interpretation does not parallel your findings or if I can be of any further assistance please contact me.

Eric Lindquist, DMV, DABVP(CFM), Cert. IVUSS,
CEO, Owner, Founder -- SonoPath.com
info@SonoPath.com