



PATIENT

Sedna Ewing

SPECIES

Canine

BREED

Basset Hound/Beagle
Mix

SEX

Spayed Female

AGE

4 Years 8 Months

WEIGHT

55 pounds

INTERPRETED BY

Eric Lindquist, DMV,
DABVP(CFM), Cert.
IVUSS

IMAGING PERFORMED BY

Dr. Jenni Tudini,
MRCVS, SDEP Cert
(abdo)

HOSPITAL NAME

East Aurora Veterinary
Hospital

REFERRING VET

Dr. Sara Huckabone

INVOICE

12155

DATE

11/07/25

PRESENTING CLINICAL SIGNS

Patient has had recurrent LUTI and further investigation was advised. There was concern over an intra-luminal mass noted by rDVM

Abnormal PE/Chem/CBC/UA Results: Exam unremarkable - U/a: confirmed LUTI with rods and inflammatory response present. - Visible uroliths within bladder lumen noted on scan and confirmed via right lateral radiograph.

LIMITED ULTRASONOGRAPHIC EXAMINATION

Urinary System

The **urinary bladder** revealed multiple calculi with acoustic shadowing measuring up to 0.77 cm. Minor bladder wall thickening was noted consistent with cystitis. The cystourethral junction and urethra (to a depth of 2.0 cm) were unremarkable.

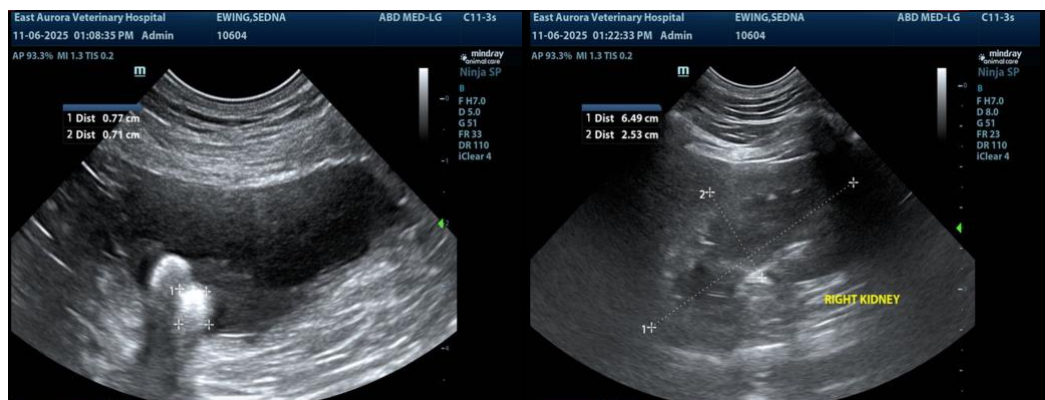
The **kidneys** revealed normal size and structure, corticomedullary definition and ratio for this age. The cortices presented largely uniform texture with normal echogenic relationship to liver and spleen. Medullary structure differed distinctly from the cortex and no evidence of pelvic dilation was present. The capsules were acceptably uniform without significant irregularities. The left kidney measured 6.6 cm in length. The right kidney measured 6.5 cm in length.

ULTRASONOGRAPHIC FINDINGS

- Bladder calculi.
- Minor cystitis pattern.

INTERPRETATION OF THE FINDINGS & FURTHER RECOMMENDATIONS

Cystotomy, stone analysis, apical bladder wall biopsy and culture are all indicated.





PATIENT

Sedna Ewing

SPECIES

Canine

BREED

Basset Hound/Beagle
Mix

SEX

Spayed Female

AGE

4 Years 8 Months

WEIGHT

55 pounds

INTERPRETED BY

Eric Lindquist, DMV,
DABVP(CFM), Cert.
IVUSS

IMAGING PERFORMED BY

Dr. Jenni Tudini,
MRCVS, SDEP Cert
(abdo)

HOSPITAL NAME

East Aurora Veterinary
Hospital

REFERRING VET

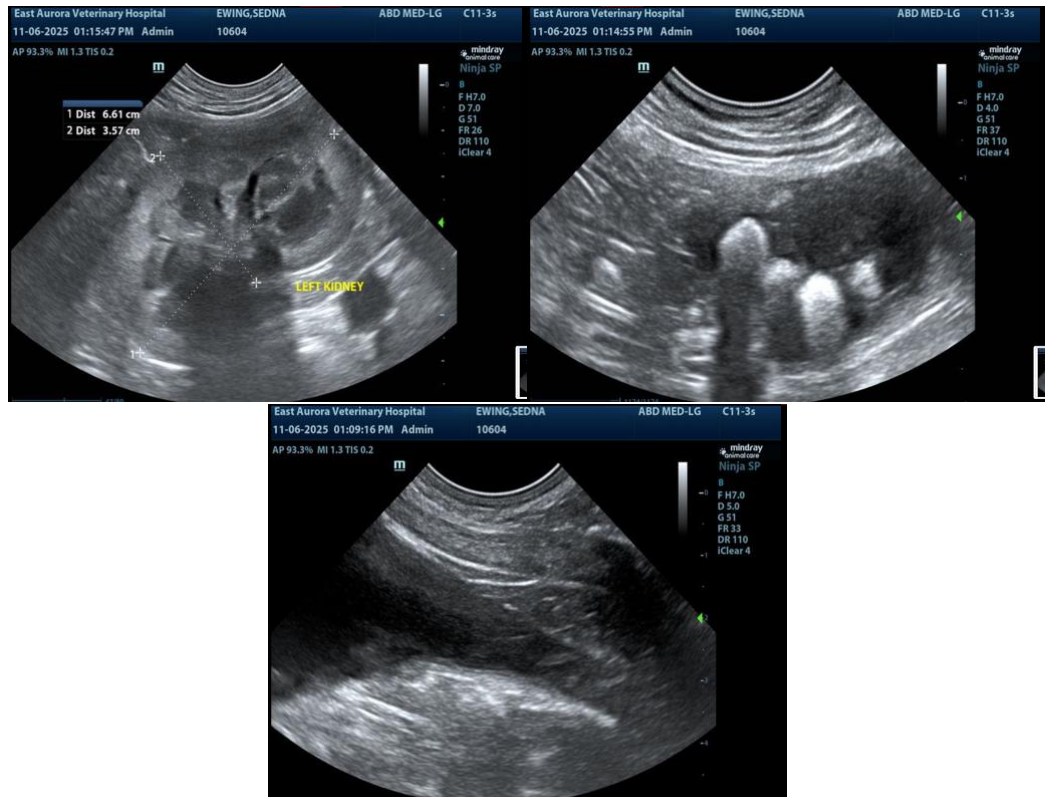Dr. Sara Huckabone

INVOICE

12155

DATE

11/07/25



The information and recommendations provided are based on the images presented by the referring veterinarian/sonographer. No evaluation can be communicated regarding pathology that was not visible in the image/video clips provided.

Thank you for this referral. If the clinical or image interpretation does not parallel your findings or if I can be of any further assistance, please contact me.

Eric Lindquist, DMV, DABVP(CFM), Cert. IVUSS,

CEO, Owner, Founder -- SonoPath.com

info@SonoPath.com