



PATIENT

Mister Banks Gerwig

SPECIES

Canine

BREED

Labrador Retriever

SEX

Intact male

AGE

11 years

WEIGHT

94 lbs

INTERPRETED BY

Eric Lindquist, DMV
DABVP, Cert. IVUSS

IMAGING PERFORMED BY

Dr. Wolfe

HOSPITAL NAME

HomeVets

REFERRING VET

Dr. Wolfe

INVOICE

68493

DATE

11/7/25

PRESENTING CLINICAL SIGNS

History: P presents for focal prostate US due to scooting, decreased BM frequency, and decreased tail wagging.

Abnormal PE/Chem/CBC/UA Results: Prostate palpates enlarged, smooth, symmetrical

ULTRASONOGRAPHIC EXAMINATION OF THE ABDOMEN

Urinary System

The **urinary bladder**, trigone, and pelvic urethra presented normal thicknesses and normal tone. The ureters were not visible which is normal. No uroliths or sediment were visualized and anechoic urine was present. No evidence of inflammatory or neoplastic changes was noted. Ureteral papillae were normal.

The **prostate** was uniformly enlarged with lobar swelling appeared to impinge upon the urethra and mildly deviate the descending colon. The prostatic tissue was hyperechoic containing focal areas of decreased echogenicity. These changes are suggestive of either chronic inflammatory episodes, benign cystic pathology or both. Underlying neoplasia cannot be completely ruled-out but is lower on the differential list. This presentation is most consistent with benign prostatic hyperplasia with possible active prostatitis. Neutering or off-label Finasteride (Propecia) (0.1-0.5 mg/kg Sid) treatment is indicated +/- FNA or prostatic wash cytology and culture. The prostate measured 3.5 cm.

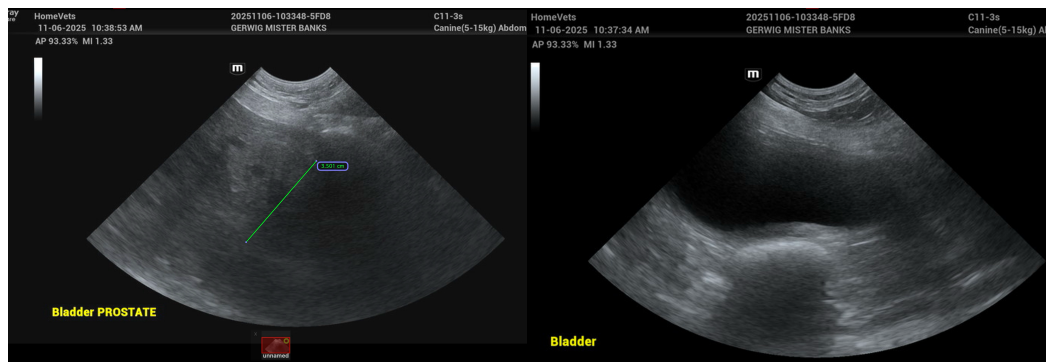
The iliac trifurcation was unremarkable.

ULTRASONOGRAPHIC FINDINGS

- BPH prostate presentation, appears stable.

INTERPRETATION OF THE FINDINGS & FURTHER RECOMMENDATIONS

Neutering should prove effective in this patient. There was no evidence of active inflammation. Management would be based on clinical signs.





PATIENT

Mister Banks Gerwig

SPECIES

Canine

BREED

Labrador Retriever

SEX

Intact male

AGE

11 years

WEIGHT

94 lbs

INTERPRETED BY

Eric Lindquist, DMV
DABVP, Cert. IVUSS

IMAGING PERFORMED BY

Dr. Wolfe

HOSPITAL NAME

HomeVets

REFERRING VET

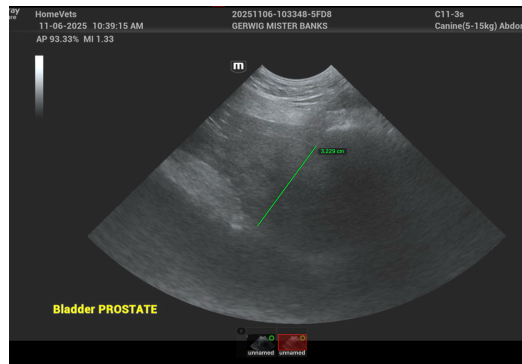
Dr. Wolfe

INVOICE

68493

DATE

11/7/25



The information and recommendations provided are based on the images presented by the referring veterinarian/sonographer. No evaluation can be communicated regarding pathology that was not visible in the image/video clips provided.

Thank you for this referral. If the clinical or image interpretation does not parallel your findings or if I can be of any further assistance please contact me.

Eric Lindquist, DMV, DABVP (CFM), Cert. IVUSS, CEO of SonoPath.com

info@SonoPath.com