



PATIENT

Zoey Hickey

SPECIES

Canine

BREED

Boxer Mix

SEX

Spayed female

AGE

8 ½ years

WEIGHT

33.7 kg

INTERPRETED BY

Eric Lindquist, DMV
DABVP, Cert. IVUSS

IMAGING PERFORMED BY

Dr. Trudeau

HOSPITAL NAME

Petworks VH

REFERRING VET

Dr. Trudeau

INVOICE

42365

DATE

11/7/22

PRESENTING CLINICAL SIGNS

History: follow up u/s on the GB and liver from inv # 31358 FNA of the spleen was performed today
 Abnormal PE/Chem/CBC/UA Results: ALB = 38 g/L 22 - 39 ALKP = 401 U/L H 23 - 212 ALT = 146 U/L H 10 - 125 BUN/UREA = 12.8 mmol/L H 2.5 - 9.6 CREA = 87 umol/L 44 - 159 GLU = 6.91 mmol/L 3.89 - 7.95 TP = 74 g/L 52 - 82 GLOB = 36 g/L 25 - 45 ALB/GLOB = 1.1 BUN/CREA = 36

ULTRASONOGRAPHIC EXAMINATION OF THE ABDOMEN

Liver

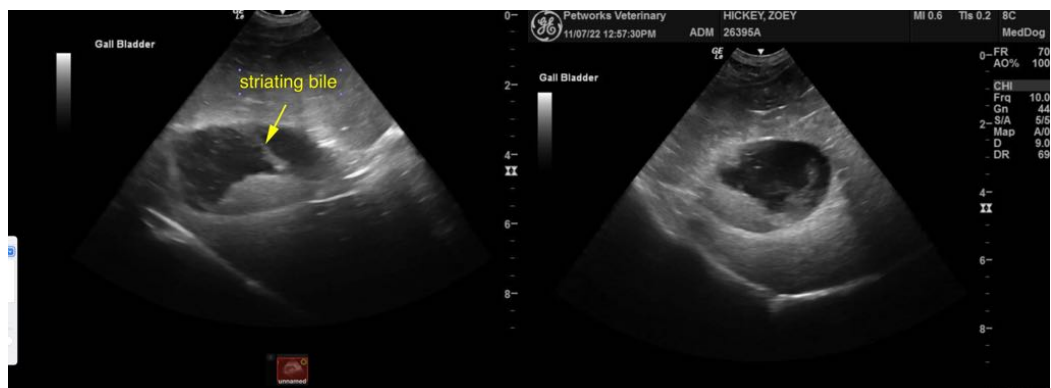
The **liver** was uniformly swollen. The liver presented coarse architecture with mildly increased portal markings and subtle, mixed echogenic changes. This is consistent with vacuolar hepatopathy and some level of remodeling and history of inflammatory component. There was no overt suspicion of neoplasia. The gallbladder revealed fairly normal teardrop appearance with minor suspended, striating bile and dependent bile. Gallbladder in long axis measured 4.0 x 2.3 cm.

ULTRASONOGRAPHIC FINDINGS

Subjectively benign hepatopathy with minor excessive gallbladder debris.

INTERPRETATION OF THE FINDINGS & FURTHER RECOMMENDATIONS

FNA of the liver can be considered for further definition; however, subjectively appears benign. Continuation of Ursodiol therapy is likely in this patient's best interest long term. Mucocele criteria is not present, however, minor excessive debris is evident with striation and immobility.





PATIENT

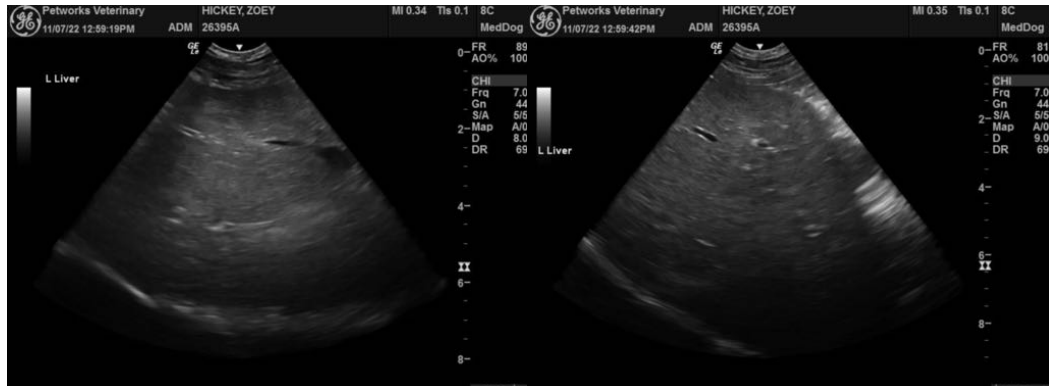Zoey Hickey

SPECIES

Canine

BREED

Boxer Mix



SEX

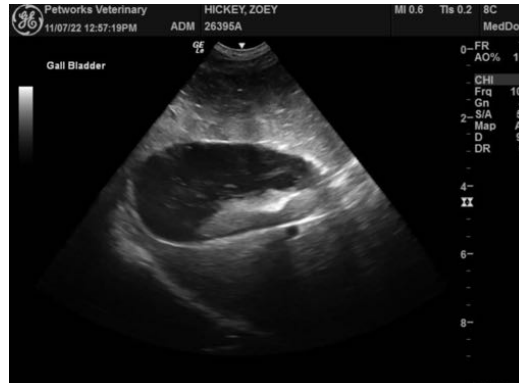Spayed female

AGE

8 ½ years

WEIGHT

33.7 kg



INTERPRETED BY

Eric Lindquist, DMV
DABVP, Cert. IVUSS

IMAGING PERFORMED BY

Dr. Trudeau

HOSPITAL NAME

Petworks VH

REFERRING VET

Dr. Trudeau

INVOICE

42365

DATE

11/7/22

The information and recommendations provided are based on the images presented by the referring veterinarian/sonographer. No evaluation can be communicated regarding pathology that was not visible in the image/video clips provided.

Thank you for this referral. If the clinical or image interpretation does not parallel your findings or if I can be of any further assistance please contact me.

Eric Lindquist, DMV, DABVP, Cert. IVUSS, CEO of SonoPath.com
info@SonoPath.com