



**PATIENT**

Pretty Girl Capo

**PRESENTING CLINICAL SIGNS**

re check prev u/s showed reactive mesentery and enteritis pattern, pancreatitis, splenic enlargement, patient is still having diarrhea

**SPECIES**

Feline

**ULTRASONOGRAPHIC EXAMINATION OF THE ABDOMEN**

**Urinary System**

**BREED**

DSH

The **urinary bladder**, trigone, and pelvic urethra presented normal thicknesses and normal tone. The ureters were not visible which is normal. No uroliths or sediment were visualized and anechoic urine was present. No evidence of inflammatory or neoplastic changes were noted. Ureteral papillae were normal.

**SEX**

Spayed Female

The **kidneys** revealed normal size and structure, corticomedullary definition and ratio for this age. The cortices presented largely uniform texture with normal echogenic relationship to liver and spleen. Medullary structure differed distinctly from the cortex and no evidence of pelvic dilation was present. The capsules were acceptably uniform without significant irregularities. The left kidney measured 4.0 cm. The right kidney measured 4.0 cm.

**AGE**

8 Years

**Adrenal Glands**

The regions of the **adrenal glands** were unremarkable.

**WEIGHT**

8.6 Pounds

**Spleen**

The **spleen** presented a smooth homogeneous parenchyma hyperechoic to liver and renal cortical parenchyma. The capsule was smooth without noticeable expansion or deviation from within the spleen or adjacent pathology. The splenic vasculature demonstrated normal volume without signs of congestion or thrombosis. No sonographic evidence of acute or chronic inflammatory, neoplastic, or infarctual changes were noted.

**INTERPRETED BY**

Eric Lindquist, DMV

**Liver**

The **liver** images submitted revealed subjectively normal liver size, contour, and structure. Parenchymal echogenicity was naturally coarse and hypoechoic to the spleen. Vascular and biliary tracts were of normal volume with no evidence of congestion. The gallbladder presented acceptably thin walls with primarily anechoic content. The cystic and common bile ducts were normal. No pathological hepatic lymphadenopathy was evident. No overt structural evidence of inflammatory, infiltrative or regenerative pathology was evident.

DABVP, Cert. IVUSS

**IMAGING PERFORMED BY**

Jenn

**HOSPITAL NAME**

Rockaway AH

**Gastrointestinal**

Examination of the **gastrointestinal tract** revealed a stomach and intestine free of stasis, of normal wall thickness, acceptable curvilinear mural detail, and peristaltic activity. Small and large intestine demonstrated normal luminal chyme and stool consistency respectively. No obstructive or overt infiltrative disease was noted. No associated abnormal lymphatic activity was noted.

**REFERRING VET**

Dr. Maniar

**Pancreas**

The base and limbs of the **pancreas** were observed to be largely isoechoic to surrounding omental fat. Pancreatic duct and capsular contour were acceptably normal and parenchyma respected normal curvilinear patterns. No overt evidence of active inflammatory or neoplastic disease was noted.

**INVOICE**

42600

**DATE**

11/7/22

**ULTRASONOGRAPHIC FINDINGS**

- Unremarkable abdomen



**PATIENT**

Pretty Girl Capo

**SPECIES**

Feline

**BREED**

DSH

**SEX**

Spayed Female

**AGE**

8 Years

**WEIGHT**

8.6 Pounds

**INTERPRETED BY**

Eric Lindquist, DMV  
DABVP, Cert. IVUSS

**IMAGING PERFORMED BY**

Jenn

**HOSPITAL NAME**

Rockaway AH

**REFERRING VET**

Dr. Maniar

**INVOICE**

42600

**DATE**

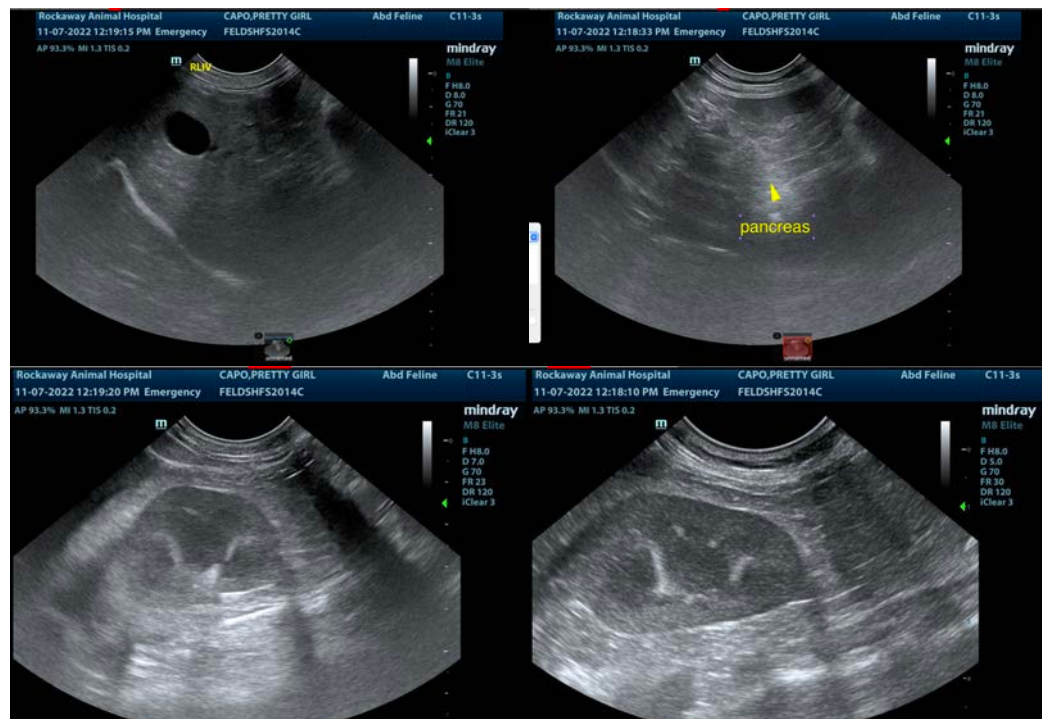
11/7/22

**INTERPRETATION OF THE FINDINGS & FURTHER RECOMMENDATIONS**

The intestinal tract has largely resolved in this patient. No further reactive mesentery present. Rotation of different diets should be considered in this patient. Structurally the abdomen appears unremarkable with resolved splenic presentation as well. Environmental stressors should also be considered as well as occult parasitism.

For an additional charge an internal medicine consult can be utilized through [SonoPath.com](http://sonopath.com). You can select the internal medicine drop down at <http://spa.sonopath.com/>.

One of the world's top internists & SonoPath associate Dr. Remo Lobetti BVSc, MMedVet, PhD, DECVIM can evaluate your case through SonoPath. <https://sonopath.com/resources/sonopath-services/internal-medicine-teleconsultation-services>



The information and recommendations provided are based on the images presented by the referring veterinarian/sonographer. No evaluation can be communicated regarding pathology that was not visible in the image/video clips provided.

Thank you for this referral. If the clinical or image interpretation does not parallel your findings or if I can be of any further assistance please contact me.

**Eric Lindquist, DMV, DABVP, Cert. IVUSS, CEO of SonoPath.com**

[info@SonoPath.com](mailto:info@SonoPath.com)