

**DATE**

11/7/22

PATIENT

Lexi Engstrom

SPECIES

Canine

BREED

Cairn Terrier

SEX

Spayed Female

AGE

7/23/10

WEIGHT

20.7 Pounds

INTERPRETED BYEric Lindquist, DMV
DABVP, Cert. IVUSS**IMAGING PERFORMED BY**Stephanie Warga
RDCS, RVT**HOSPITAL NAME**

Bayside AMC

REFERRING VET

Dr. Sims

INVOICE

42583

PRESENTING CLINICAL SIGNS

Lethargy, decreased appetite. Bloodwork revealed anemia and mild elevation in alk phos. Pt did have an engorged tick on skin we removed at exam. Slide agglutination was negative. Abd rads revealed probable enlarged spleen.

Current Medications: Yaunnan Bai Yao, Gabapentin, Doxycycline.

Lab Results: See attached.

Radiographs: Spleen appears enlarged in the lower left quadrant on VD.

Date of Previous IntraPet Ultrasound: No previous.

Sedation: Not required to complete full diagnostic ultrasound.

Stat Report: Requested.

ULTRASONOGRAPHIC EXAMINATION OF THE ABDOMEN**Urinary System**

The **urinary bladder**, trigone, and pelvic urethra presented normal thicknesses and normal tone. The ureters were not visible which is normal. No uroliths or sediment were visualized and anechoic urine was present. No evidence of inflammatory or neoplastic changes were noted. Ureteral papillae were normal.

The **kidneys** revealed largely normal size and structure, corticomedullary definition and ratio (cortex 1/3 of medulla) were essentially maintained with some age-related loss of curvilinear patterns regarding the capsule and C/M junction. The cortices presented largely uniform texture with some increased echogenicity expected for his age patient. Medullary structure differed distinctly from that of the cortex. The right kidney measured 4.55 cm. The left kidney measured 4.42 with pyelectasia of 0.35 cm.

Adrenal Glands

Both **adrenal glands** were visualized and recognized as having normal shape, size, position and echogenicity for this breed. The phrenic vasculature, glandular echogenicity and detail were unremarkable. Capsule, cortex, and medullary definition were normal for this age patient. The right adrenal gland measured 1.56 cm x 0.60 cm at the caudal pole and 0.50 cm at the cranial pole. The left adrenal gland measured 1.7 cm x 0.57 cm at the caudal pole and 0.51 cm at the cranial pole.

Spleen

The **spleen** was enlarged, uniform, with scalloping contour. No overt masses. However, I cannot rule out an early infiltrative event.

Liver

The **liver** was mildly swollen and slightly irregular with subtle remodeling. The gallbladder and common bile duct were unremarkable.

Gastrointestinal

Examination of the **gastrointestinal tract** revealed a stomach and intestine free of stasis, of normal wall thickness, acceptable curvilinear mural detail, and peristaltic activity. Small and large intestine demonstrated normal luminal chyme and stool consistency respectively. No obstructive or overt infiltrative disease was noted. No associated abnormal lymphatic activity was noted.

Pancreas

The base and limbs of the **pancreas** were observed to be largely isoechoic to surrounding omental fat. Pancreatic duct and capsular contour were acceptably normal and parenchyma respected normal curvilinear patterns. No overt evidence of active inflammatory or neoplastic disease was noted.

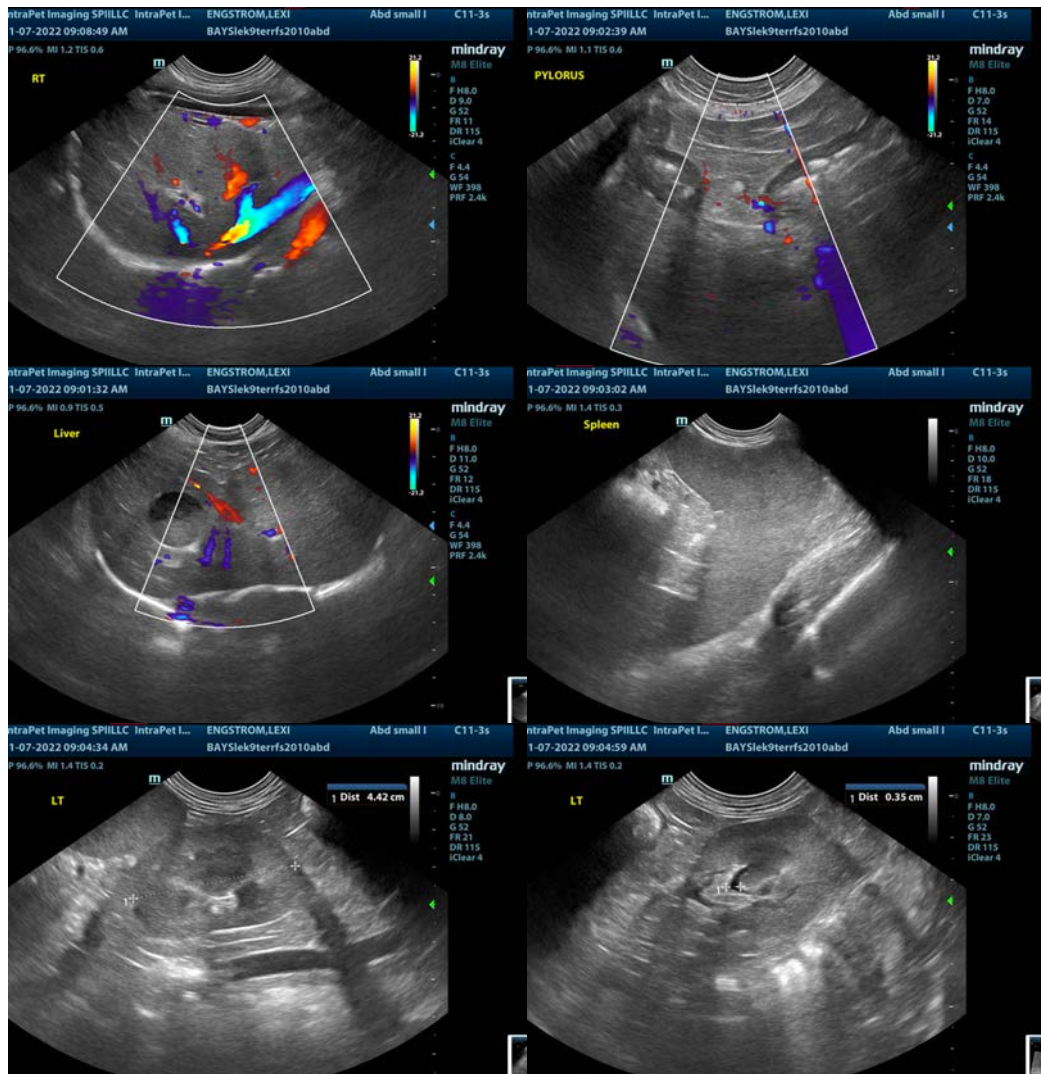
ULTRASONOGRAPHIC FINDINGS

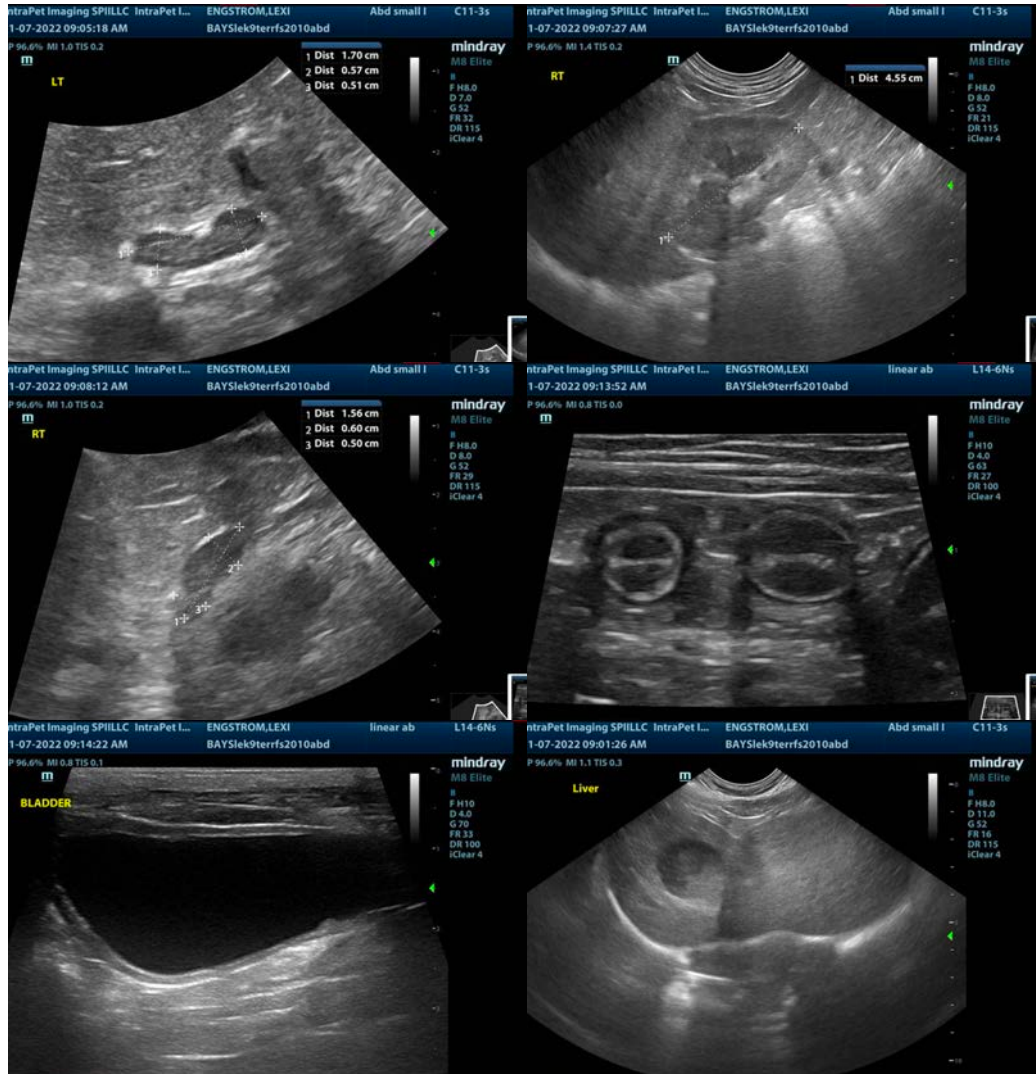
- Mild to moderate splenic enlargement – reactive spleen versus emerging round cell neoplasia.
- Undefined mild hepatic enlargement, uniform
- Age related renal changes

INTERPRETATION OF THE FINDINGS & FURTHER RECOMMENDATIONS

Splenic and hepatic FNAs indicated to assess for early round cell neoplasia, or reactive spleen and benign liver. If infiltrative disease is present, it would be quite early. Other causes of the clinical signs such as orthopedic/back pain, CNS, or thoracic disease should also be considered if aspirates are benign in both the spleen and liver.

Radiographs: Irregular spleen and liver, intestinal deviation.





The information and recommendations provided are based on the images presented by the referring veterinarian/sonographer. No evaluation can be communicated regarding pathology that was not visible in the image/video clips provided.

Thank you for this referral. If the clinical or image interpretation does not parallel your findings or if I can be of any further assistance please contact me.

Eric Lindquist, DMV, DABVP, Cert. IVUSS, CEO of SonoPath.com
info@SonoPath.com