



PATIENT

Little Fox Camp

SPECIES

Canine

BREED

Husky Cross

SEX

AGE

7 years

WEIGHT

23.6 lbs

INTERPRETED BY

Eric Lindquist, DMV
DABVP, Cert. IVUSS

IMAGING PERFORMED BY

Shannah DUffy

HOSPITAL NAME

Portland Veterinary
Wellness Center

REFERRING VET

Dr. Schwartz

INVOICE

68413

DATE

11/6/25

PRESENTING CLINICAL SIGNS

History: ~1 mo hx of hyporexia, increased anxiety. Hx ear issues, otitis and vasculitis. Hx LH limb amputation. On Cosequin, Simparica Trio, hydroxyzine PRN, gabapentin 100-200 mg PO BID.
Abnormal PE/Chem/CBC/UA Results: HCT 39%, WBC 4.6, slight eosinopenia, CHEM wnl, USG 1.017

ULTRASONOGRAPHIC EXAMINATION

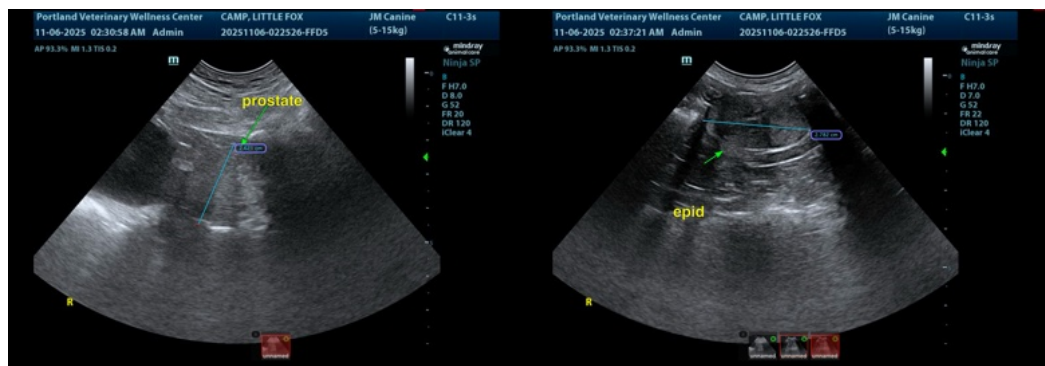
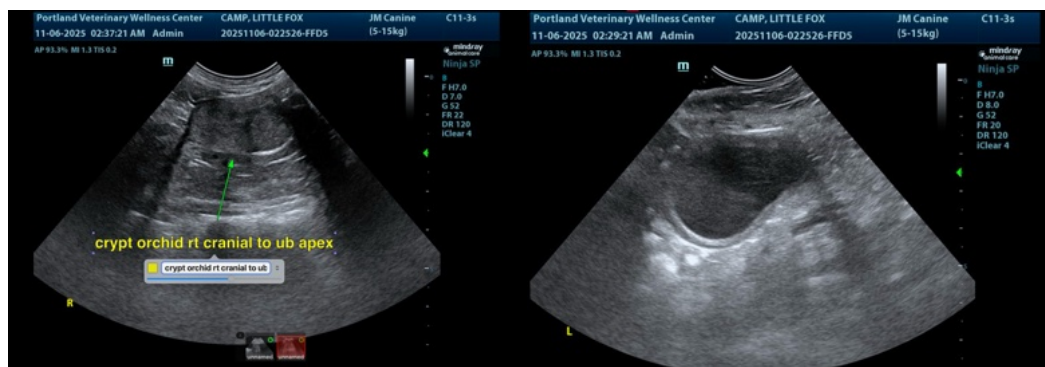
Limited exam of the urinary bladder and prostate revealed a mildly enlarged prostate. The prostate was slightly heterogenous with no evidence of inflammation. Right cranial to the urinary bladder a 2.8 cm retained intraabdominal cryptorchid was noted adjacent to the body wall. The epididymis was identified to differentiate from the lymph node.

ULTRASONOGRAPHIC FINDINGS

- Right cranial cryptorchid

INTERPRETATION OF THE FINDINGS & FURTHER RECOMMENDATIONS

Intraabdominal surgical removal is recommended.





PATIENT

Little Fox Camp

The information and recommendations provided are based on the images presented by the referring veterinarian/sonographer. No evaluation can be communicated regarding pathology that was not visible in the image/video clips provided.

SPECIES

Canine

Thank you for this referral. If the clinical or image interpretation does not parallel your findings or if I can be of any further assistance please contact me.

BREED

Husky Cross

Eric Lindquist, DMV, DABVP (CFM), Cert. IVUSS, CEO of SonoPath.com

info@SonoPath.com

SEX

AGE

7 years

WEIGHT

23.6 lbs

INTERPRETED BY

Eric Lindquist, DMV
DABVP, Cert. IVUSS

IMAGING PERFORMED BY

Shannah DUFFY

HOSPITAL NAME

Portland Veterinary
Wellness Center

REFERRING VET

Dr. Schwartz

INVOICE

68413

DATE

11/6/25