



PATIENT

Heather Babson

SPECIES

Canine

BREED

Golden Doodle

SEX

Spayed female

AGE

8 years

WEIGHT

60.3 lbs

INTERPRETED BY

Eric Lindquist, DMV
DABVP, Cert. IVUSS

IMAGING PERFORMED BY

Dr. Shonk

HOSPITAL NAME

Court Street VH

REFERRING VET

Dr. Shonk

INVOICE

68412

DATE

11/6/25

PRESENTING CLINICAL SIGNS

History: Hx of collapse, unexplained hypoglycemia on BW, and elevated lipase; high normal cardio proBNP - echo WNL O wished to pursue cutaneous lateral chest/abdominal mass removal today and elected to pursue US to rule out pancreatic mass/abnormality while sedated
Abnormal PE/Chem/CBC/UA Results: Hx of various cutaneous/SQ masses - O monitoring most, lateral chest/abdominal mass surgical excision today Hx of collapsing episodes at groomer's in Jan 2025, mildly elevated proBNP , echo WNL 10/17/25 unexplained hypoglycemia, elevated lipase

ULTRASONOGRAPHIC EXAMINATION OF THE ABDOMEN

Urinary System

The **urinary bladder** revealed minor micropolypoid changes. The changes are likely age related.

The **kidneys** revealed normal size and structure, corticomedullary definition and ratio for this age. The cortices presented largely uniform texture with normal echogenic relationship to liver and spleen. Medullary structure differed distinctly from the cortex and no evidence of pelvic dilation was present. The capsules were acceptably uniform without significant irregularities. The left kidney measured 6.7 cm and the right kidney measured 7.2 cm.

Adrenal Glands

The **adrenal glands** appear somewhat flattened, yet measurably normal. The left adrenal gland measured 0.4 cm. The right adrenal gland measured 1.5 cm at the cranial pole and 0.9 cm at the caudal pole.

Spleen

The **spleen** revealed a hypoechoic parenchymal mass that measured 3.35 cm. The mass appears isolated and parenchymal. The remainder of the spleen appeared unremarkable.

Liver

The **liver** images submitted revealed subjectively normal liver size, contour, and structure. Parenchymal echogenicity was naturally coarse and hypoechoic to the spleen. Vascular and biliary tracts were of normal volume with no evidence of congestion. The gallbladder presented acceptably thin walls with primarily anechoic content. The cystic and common bile ducts were normal. No pathological hepatic lymphadenopathy was evident. No overt structural evidence of inflammatory, infiltrative or regenerative pathology was evident.



PATIENT

Heather Babson

SPECIES

Canine

BREED

Golden Doodle

SEX

Spayed female

AGE

8 years

WEIGHT

60.3 lbs

INTERPRETED BY

Eric Lindquist, DMV
DABVP, Cert. IVUSS

IMAGING PERFORMED BY

Dr. Shonk

HOSPITAL NAME

Court Street VH

REFERRING VET

Dr. Shonk

INVOICE

68412

DATE

11/6/25

Gastrointestinal

Examination of the **gastrointestinal tract** revealed a stomach and intestine free of stasis, of normal wall thickness, acceptable curvilinear mural detail, and peristaltic activity. Small and large intestine demonstrated normal luminal chyme and stool consistency respectively. No obstructive or overt infiltrative disease was noted. No associated abnormal lymphatic activity was noted.

Pancreas

The base and limbs of the **pancreas** were observed to be largely isoechoic to surrounding omental fat. Pancreatic duct and capsular contour were acceptably normal and parenchyma respected normal curvilinear patterns. No overt evidence of active inflammatory or neoplastic disease was noted.

Heart

Rapid view of the heart revealed hypocontractility, mild volume overload and bradycardia.

ULTRASONOGRAPHIC FINDINGS

- Minor micropolypoid bladder changes.
- Splenic mass. Differentials include round cell neoplasia, hemangiosarcoma, necrosis and less likely abscessation.
- Hypocontractility and mild volume overload.

INTERPRETATION OF THE FINDINGS & FURTHER RECOMMENDATIONS

Full echocardiogram is warranted. If the patient was sedated with Dexdomitor or similar this would be normal; however, contractility was poor. If the patient was not sedated at the time of the sonogram then full echocardiogram is indicated.

Eventual splenectomy is indicated. Ultrasound-guided FNA of the spleen is indicated. Screening for Addison's is indicated with ACTH stimulation. Insulin glucose profile is also indicated.

Assessment for any ingestion of xylitol is also indicated.



PATIENT

Heather Babson

SPECIES

Canine

BREED

Golden Doodle

SEX

Spayed female

AGE

8 years

WEIGHT

60.3 lbs

INTERPRETED BY

Eric Lindquist, DMV
DABVP, Cert. IUUS

IMAGING PERFORMED BY

Dr. Shonk

HOSPITAL NAME

Court Street VH

REFERRING VET

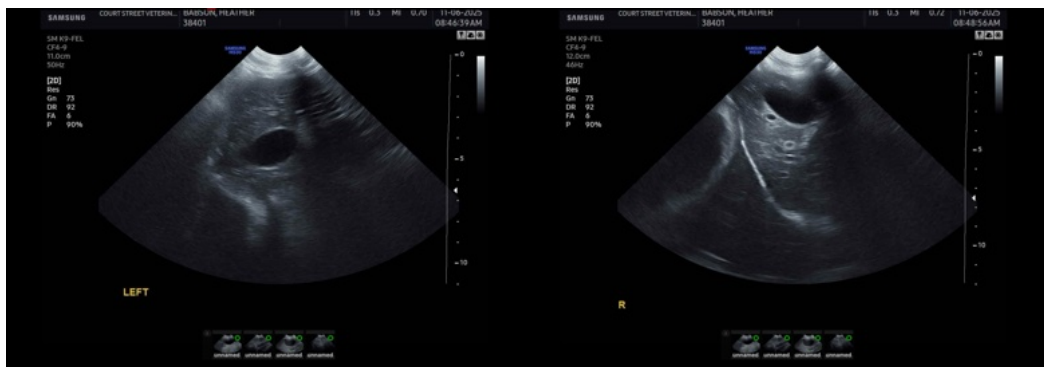
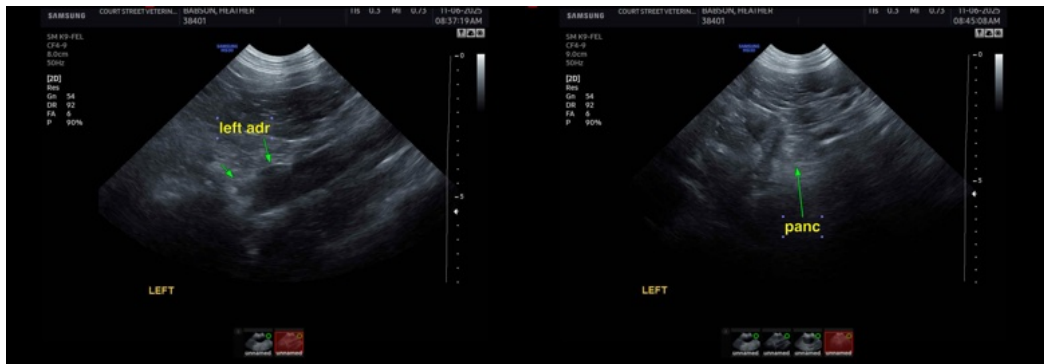
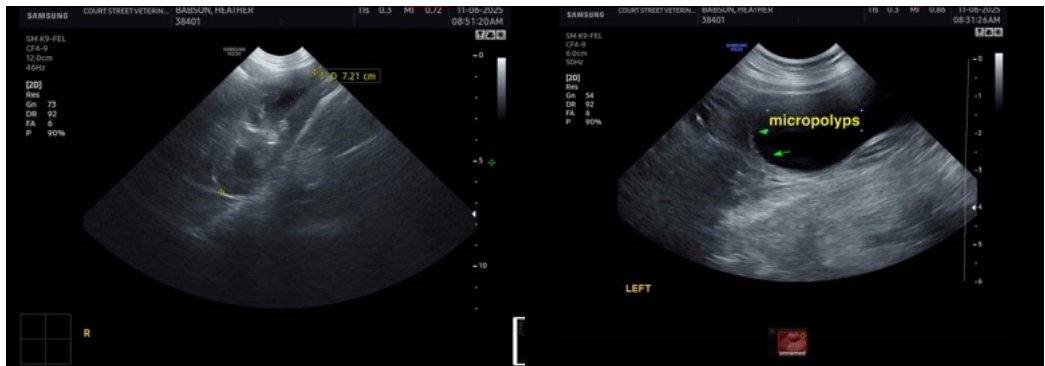
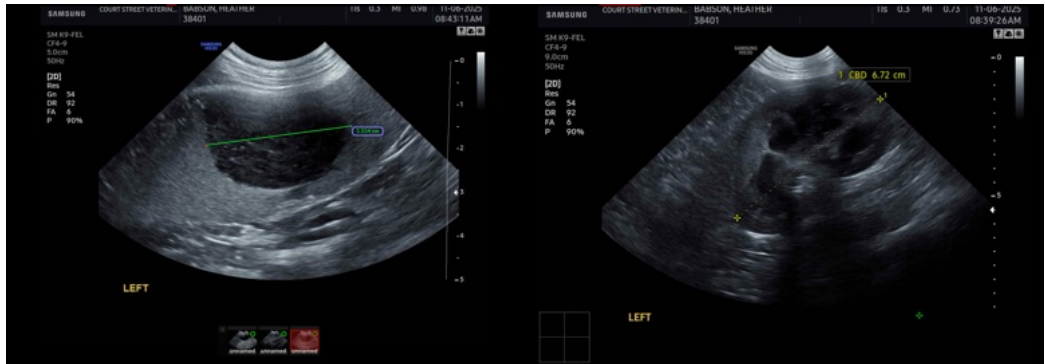
Dr. Shonk

INVOICE

68412

DATE

11/6/25





PATIENT

Heather Babson

SPECIES

Canine

BREED

Golden Doodle

SEX

Spayed female

AGE

8 years

WEIGHT

60.3 lbs

INTERPRETED BY

Eric Lindquist, DMV
DABVP, Cert. IVUSS

IMAGING PERFORMED BY

Dr. Shonk

HOSPITAL NAME

Court Street VH

REFERRING VET

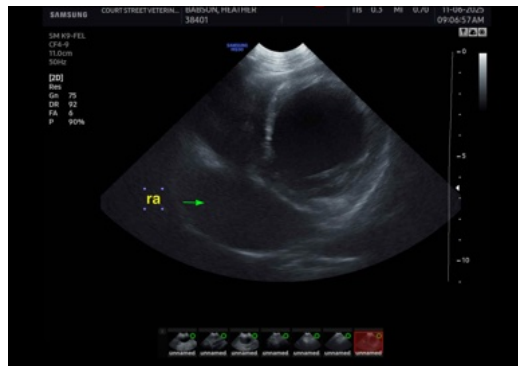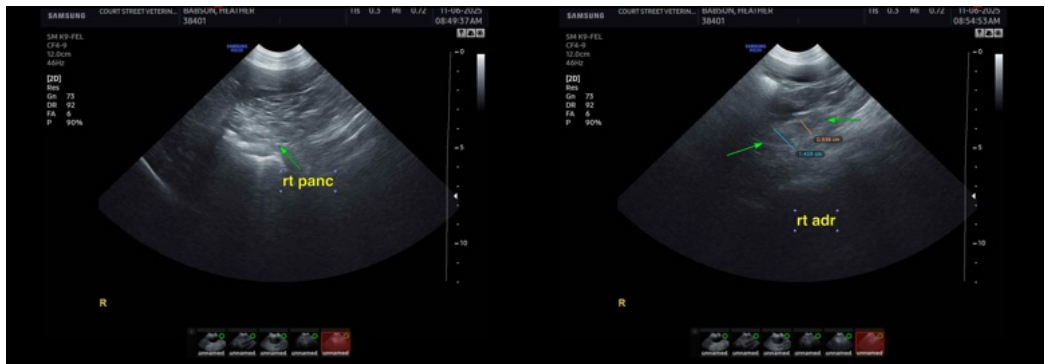
Dr. Shonk

INVOICE

68412

DATE

11/6/25




The information and recommendations provided are based on the images presented by the referring veterinarian/sonographer. No evaluation can be communicated regarding pathology that was not visible in the image/video clips provided.

Thank you for this referral. If the clinical or image interpretation does not parallel your findings or if I can be of any further assistance please contact me.

Eric Lindquist, DMV, DABVP (CFM), Cert. IVUSS, CEO of SonoPath.com

info@SonoPath.com



The following is an applicable excerpt from the *Curbside Guide to Diagnosis & Treatment of Sonographic Disease* offered by SonoPath.com Lindquist, Frank, Lobetti, and Modler.

An essential quick guide for every general practitioner and sonographer.

<https://sonopath.com/products/curbside-guide-editing-due-release-12012015>



PATIENT

Heather Babson

SPECIES

Canine

BREED

Golden Doodle

SEX

Spayed female

AGE

8 years

WEIGHT

60.3 lbs

INTERPRETED BY

Eric Lindquist, DMV
DABVP, Cert. IVUSS

IMAGING PERFORMED BY

Dr. Shonk

HOSPITAL NAME

Court Street VH

REFERRING VET

Dr. Shonk

INVOICE

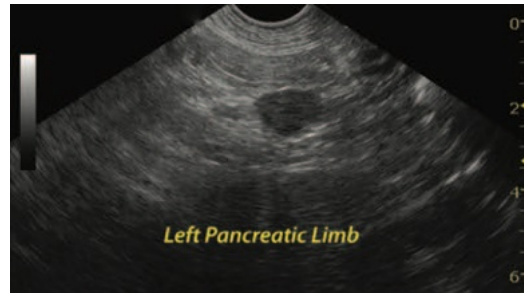68412

DATE

11/6/25

Hypoglycemic Syndrome: Insulinoma and Other

<http://www.sonopath.com/Hypoglycemia>



Short axis of the left pancreatic limb in a dog with an insulinoma seen as an ovoid hypoechoic mass lesion expanding the pancreatic capsule.

Description: Hypoglycemia can be found incidentally or associated with non-specific clinical signs, such as listlessness and weakness. It is essential to consider the multiple differentials for hypoglycemia in order to avoid a potential hypoglycemic crisis. One must perform a rapid and efficient workup to arrive at a diagnosis and prescribe the proper therapy.

Differentials for hypoglycemia include: laboratory or handling error; sepsis; toxins (e.g. xylitol, ethylene glycol); hunting dog hypoglycemia; Addison's disease; polycythemia; liver failure; poorly regulated diabetes mellitus; and neoplasia (e.g. leiomyosarcoma, hepatic, lymphoma, and insulinoma).

Once other causes of hypoglycemia have been ruled out, one may initiate an investigation into the possibility of insulinoma. Insulinoma is a tumor of the pancreas that originates in the beta cells and leads to the unregulated secretion of insulin and hypoglycemic syndrome. The tumor can be a malignant carcinoma or a more benign form of adenoma. There is, however, controversy regarding the exact histopathology associated with insulinoma types.

Insulinoma patients are usually middle-aged dogs. Half of all cases present with metastasis to the lymph nodes, liver, and mesentery at the time of diagnosis. There are 3 stages of insulinoma:

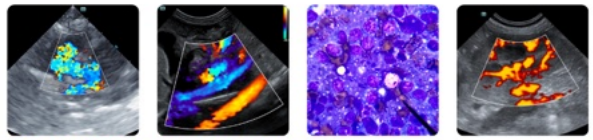
Stage 1: Pancreatic localization

Stage 2: Pancreas and lymph nodes with a median survival time (MST) of 1.5 years

Stage 3: Organ metastasis with an MST of 6 months.

Clinical Signs: Neuroglycopenia syndrome results in lethargy, ataxia, collapse, and seizures. Catecholamine release from hypoglycemia leads to hunger, behavior changes, and muscle tremors. Postprandial exacerbation of clinical signs can occur.

Diagnostics: When investigating for insulinoma, one should use a fluoride-containing tube (i.e., a grey top tube) to obtain an accurate glucose level. A fasting glucose level below 60 mg/dl is diagnostic for hypoglycemia. Insulinoma is indicated when one observes the Whipple's triad of hypoglycemia, clinical signs consistent are with hypoglycemia, and the latter resolve with the administration of dextrose.



PATIENT

Heather Babson

SPECIES

Canine

BREED

Golden Doodle

SEX

Spayed female

AGE

8 years

WEIGHT

60.3 lbs

INTERPRETED BY

Eric Lindquist, DMV
DABVP, Cert. IVUSS

IMAGING PERFORMED BY

Dr. Shonk

HOSPITAL NAME

Court Street VH

REFERRING VET

Dr. Shonk

INVOICE

68412

DATE

11/6/25

Fasting insulin and glucose ratio: A high normal to elevated insulin level with glucose < 60 mg/dl is diagnostic for insulinoma.

Imaging: Localizing the lesion with staging is best approached by ultrasound. The ability to localize the lesion may be highly operator- and/or machine-dependent given the often small or even microscopic nature of insulinoma, especially early on in the disease. Primary or secondary lesions associated with insulinoma can often be identified with higher resolution sonography. Appropriate ultrasound-guided sampling (FNA or core biopsy) can be performed of any enlarged lymph node or hepatic nodule if a primary pancreatic lesion is not seen.

Computed tomography (CT) with contrast is likely more sensitive than the average sonographer when it comes to assessing insulinoma.

Tumor staging and histopathological characterization in conjunction with the Ki67 biomarker index will yield solid criteria for the prognostic evaluation of insulinoma.

Treatment:

In cases of emergency hypoglycemic crisis, apply corn syrup to the gums. Administer a dextrose bolus (0.5g/kg IV) and maintain 2.5-10% dextrose solution. If cerebral edema occurs, one should administer dexamethasone (2 mg/kg IV) and give mannitol (0.5 mg/kg IV) over a 20-minute period.

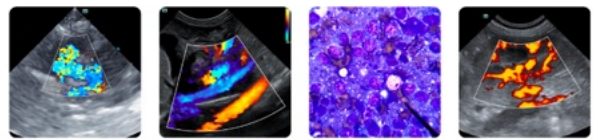
One should perform a surgical pancreatectomy if the tumor is localized (i.e., stage 1 insulinoma). Given that the lesion may be difficult to locate with the naked surgical eye or via palpation, the surgical procedure can be enhanced by intraoperative ultrasound.

In cases of stage 2 and 3 insulinoma, administer prednisolone (0.25 mg/kg PO BID). A glucagon IV infusion has also been suggested; it should be infused with saline at 5 mg/kg/min for refractory cases. If prednisone is not adequate, one can supplement with benzothiadiazide diazoxide (5 mg/kg PO BID).

Patients should be fed small, frequent portions of a diet high in fat, complex carbohydrates, and protein.

Chemotherapy: In some cases, the use of alloxan (65 mg/ kg IV) has been shown to be helpful.

Conclusion: The largest study of insulinoma patients identified a general MST of 547 days; however, the MST was 785 days for those undergoing pancreatectomy and 1316 days for those that relapsed after surgery and received treatment with prednisone. Other studies have reported an MST of 258 days with pancreatectomy. All of these results indicate that insulinoma is treatable. Using ultrasonography for staging and histopathological characterization is essential in order to determine whether the appropriate treatment should be surgical, medical, or both.



PATIENT

Heather Babson

SPECIES

Canine

BREED

Golden Doodle

SEX

Spayed female

AGE

8 years

WEIGHT

60.3 lbs

INTERPRETED BY

Eric Lindquist, DMV
DABVP, Cert. IVUSS

IMAGING PERFORMED BY

Dr. Shonk

HOSPITAL NAME

Court Street VH

REFERRING VET

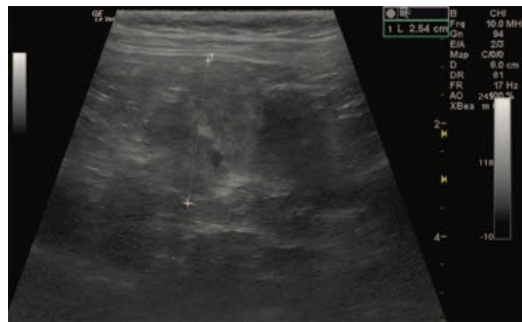
Dr. Shonk

INVOICE

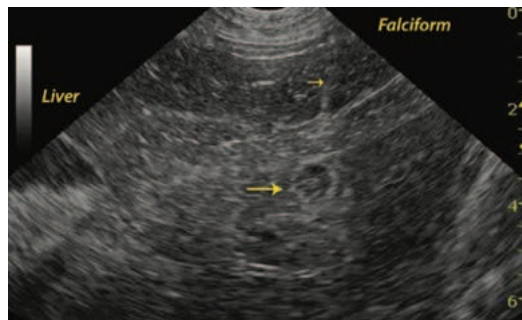
68412

DATE

11/6/25

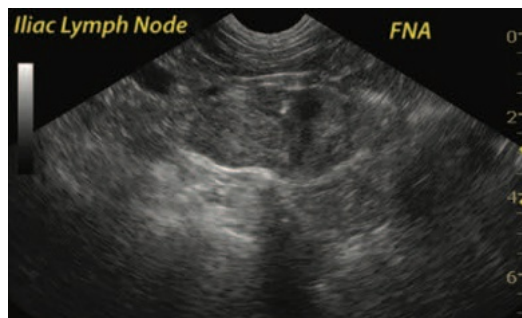


Short axis of the left pancreatic limb in a cat with an insulinoma seen as a complex heterogenous mass lesion expanding the pancreatic capsule (between calipers). Note the mass effect of the tumor displacing the transverse colon caudally.



Subxiphoidal short axis of the liver in a dog with an insulinoma during ultrasound guided sampling of a suspected metastatic lesion.

The needle trajectory is seen as a hyperechoic line (small arrow) approaching the hypoechoic nodule (large arrow) within the liver parenchyma.



Long axis of the medial iliac lymph node during needle aspiration in a dog with multifocal metastatic spread of an insulinoma. The echogenic needle tip is seen within the lymph node. The metastatic lymph node is enlarged, rounded, hypoechoic and heterogenous. The primary metastatic loci in insulinoma are the regional lymph nodes (hepatic, pancreaticoduodenal, gastric) and the liver. Hence, metastatic insulinoma lesions in the iliac lymph node in this case was not a typical occurrence.

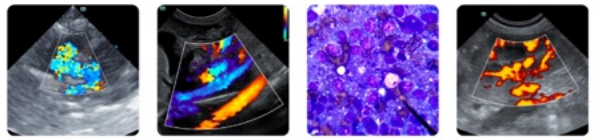
References:

Buishand FO, Kik M, Kirpensteijn J. Evaluation of clinico-pathological criteria and the Ki67 index as prognostic indicators in canine insulinoma. *Vet J* 2010;185:62-67.

Fischer JR, Smith SA, Harkin KR: Glucagon constant-rate infusion: A novel strategy for management of hyperinsulinemic-hypoglycemia crisis in the dog. *J Am Anim Hosp Assoc* 2000;36:27-32.

1.1.Polton GA, White RN, Brearley MJ, et al. Improved survival in a retrospective cohort of 28 dogs with insulinoma. *J Small Anim Pract* 2000;48:151-56.

Steiner JM, Bruyette DS: Canine insulinoma. *Compend Contin Educ Pract Vet* 1996;18:31-36.



PATIENT

Heather Babson

Tobin RL, Nelson RW, Lucroy MD, et al. Outcome of surgical versus medical treatment of dogs with beta cell neoplasia: 39 cases (1990-1997). *JAVMA* 1999;215:226-30.

SPECIES

Canine

BREED

Golden Doodle

SEX

Spayed female

AGE

8 years

WEIGHT

60.3 lbs

INTERPRETED BY

Eric Lindquist, DMV
DABVP, Cert. IVUSS

IMAGING PERFORMED BY

Dr. Shonk

HOSPITAL NAME

Court Street VH

REFERRING VET

Dr. Shonk

INVOICE

68412

DATE

11/6/25