



**PATIENT PRESENTING CLINICAL SIGNS**

Swayze Frick History: Chronic excessive panting.

**SPECIES ULTRASONOGRAPHIC EXAMINATION OF THE HEART**

Canine The echocardiogram in this patient demonstrated normal **left atrial** size based on 3 separate methods of LA evaluation. The cranial and caudal **mitral** valve leaflets presented normal linear structure, extension in systole, and union in diastole with normal kinesis. The **left ventricle** presented thicknesses with linear contour and was not dilated nor restricted. The **myocardium** presented normal echogenicity without subjective evidence of significant fibrotic or ischemic disease. **Contractility** of the ventricular walls was adequate and in normal range for this patient evidenced by the fractional shortening measurement and subjective evaluation of the different regions of the myocardium. The **left ventricular outflow** tract demonstrated normal laminar flow and subjective structural integrity. The **right atrium** and auricle revealed normal size, structure and content. No evidence of masses was noted. **Tricuspid** valvular assessment demonstrated adequate linear morphology and kinesis. The **right ventricle** was of normal size (1/3 diameter of LV), chordae structure, myocardial echogenicity and thickness. **Pulmonary outflow** tract assessment revealed normal valve structure, laminar flow, and diameter (approx.1:1 pa/ao ratio). No visible **pericardial** or free pleura fluid was noted. The cranial **mediastinum and pericardial and extra-cardiac regions** were free of masses in the visible window.

Neutered male

AGE

2 years

**WEIGHT**

65 lbs

**INTERPRETED BY**

Eric Lindquist, DMV  
DABVP, Cert. IVUSS

**IMAGING PERFORMED BY**

Shari Reffi, CVT

**HOSPITAL NAME**

Rockaway AH

**REFERRING VET**

Dr. Maniar

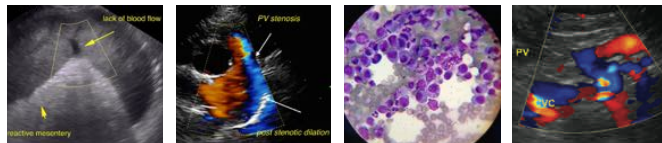
**INVOICE**

92904

**DATE**

11/5/21

CANINE CARDIAC PARAMETERS	MR VMAX (m/s)	TR VMAX (m/s)	LA/AO (Boon method)	LA/AO (Heart Base; Swe)	FS (%)	EF (%)	EPSS (cm)
NORMAL PARAMETER	4.5-5.5	<2.7	1.3	<1.6	28-40	40-100	<0.6
PATIENT			1.3	1.38	34	62	0.25
CANINE CARDIAC PARAMETERS	HR (BPM)	AV VMAX (m/s)	PV MAX (m/s)	BODY WEIGHT	LA (2D short axis Base view) (cm)	LVIDd (Avg; 2D and m-mode short axis) (cm)	LVIDs (Avg; 2D and m-mode short axis) (cm)
NORMAL PARAMETER	50-100	0.7-1.7	0.7-1.6				
PATIENT	99	1.21	0.9	65 lbs	3.13	4.9	


**PATIENT** **ULTRASONOGRAPHIC EXAMINATION OF THE ABDOMEN**

Swayze Frick

**Urinary System**
**SPECIES**

Canine

The **urinary bladder**, trigone, and pelvic urethra presented normal thicknesses and normal tone. The pelvic urethra was imaged 3.0 cm beyond the cystourethral junction. The ureters were not visible which is normal. No uroliths or sediment were visualized and anechoic urine was present. No evidence of inflammatory or neoplastic changes was noted. Ureteral papillae were normal.

**BREED**

Mix

The residual prostate measured 0.5 cm.

**SEX**

Neutered male

The **kidneys** revealed normal size and structure, corticomedullary definition and ratio for this age. The cortices presented largely uniform texture with normal echogenic relationship to liver and spleen. Medullary structure differed distinctly from the cortex and no evidence of pelvic dilation was present. The capsules were acceptably uniform without significant irregularities. The right kidney measured 7.15 cm. The left kidney measured 7.14 cm.

**AGE**

2 years

**Adrenal Glands**

Both **adrenal glands** were visualized and recognized as having normal shape, size, position and echogenicity for this breed. The phrenic vasculature, glandular echogenicity and detail were unremarkable. Capsule, cortex, and medullary definition were normal for this age patient. The left adrenal gland measured 2.89 x 0.45 cm at the cranial pole and 0.48 cm at the caudal pole.

**WEIGHT**

65 lbs

**Spleen**
**INTERPRETED BY**

 Eric Lindquist, DMV  
DABVP, Cert. IVUSS

The **spleen** presented slight, micronodular changes with minor enlargement.

**IMAGING PERFORMED BY**

Shari Reffi, CVT

**Liver**

The **liver** images submitted revealed subjectively normal liver size, contour, and structure. Parenchymal echogenicity was naturally coarse and hypoechoic to the spleen. Vascular and biliary tracts were of normal volume with no evidence of congestion. The gallbladder presented acceptably thin walls with primarily anechoic content. The cystic and common bile ducts were normal. No pathological hepatic lymphadenopathy was evident. No overt structural evidence of inflammatory, infiltrative or regenerative pathology was evident.

**HOSPITAL NAME**

Rockaway AH

**REFERRING VET**

Dr. Maniar

**Gastrointestinal**

Examination of the **gastrointestinal tract** revealed a stomach and intestine free of stasis, of normal wall thickness, acceptable curvilinear mural detail, and peristaltic activity. Small and large intestine demonstrated normal luminal chyme and stool consistency respectively. The mesenteric lymph nodes were reactive and measured up to 1.0 cm in width.

**INVOICE**

92904

**DATE**

11/5/21



**PATIENT**

**Pancreas**

Swayze Frick

The base and limbs of the **pancreas** were observed to be largely isoechoic to surrounding omental fat. Pancreatic duct and capsular contour were acceptably normal and parenchyma respected normal curvilinear patterns. No overt evidence of active inflammatory or neoplastic disease was noted.

**SPECIES**

Canine

**ULTRASONOGRAPHIC FINDINGS**

**BREED**

Normal echocardiogram.

Mix

Minor, micronodular splenic changes and slight mesenteric lymphadenopathy, likely reactive.

**SEX**

**INTERPRETATION OF THE FINDINGS & FURTHER RECOMMENDATIONS**

Neutered male

Splenic FNA is warranted for further definition to ensure that these changes are benign. There is a potential for low-grade splenitis, reactive hyperplasia and round cell neoplasia are all possible. However, the changes were subtle and fairly minor.

**AGE**

2 years

**WEIGHT**

65 lbs

**INTERPRETED BY**

Eric Lindquist, DMV  
DABVP, Cert. IVUSS

**IMAGING PERFORMED BY**

Shari Reffi, CVT

**HOSPITAL NAME**

Rockaway AH

**REFERRING VET**

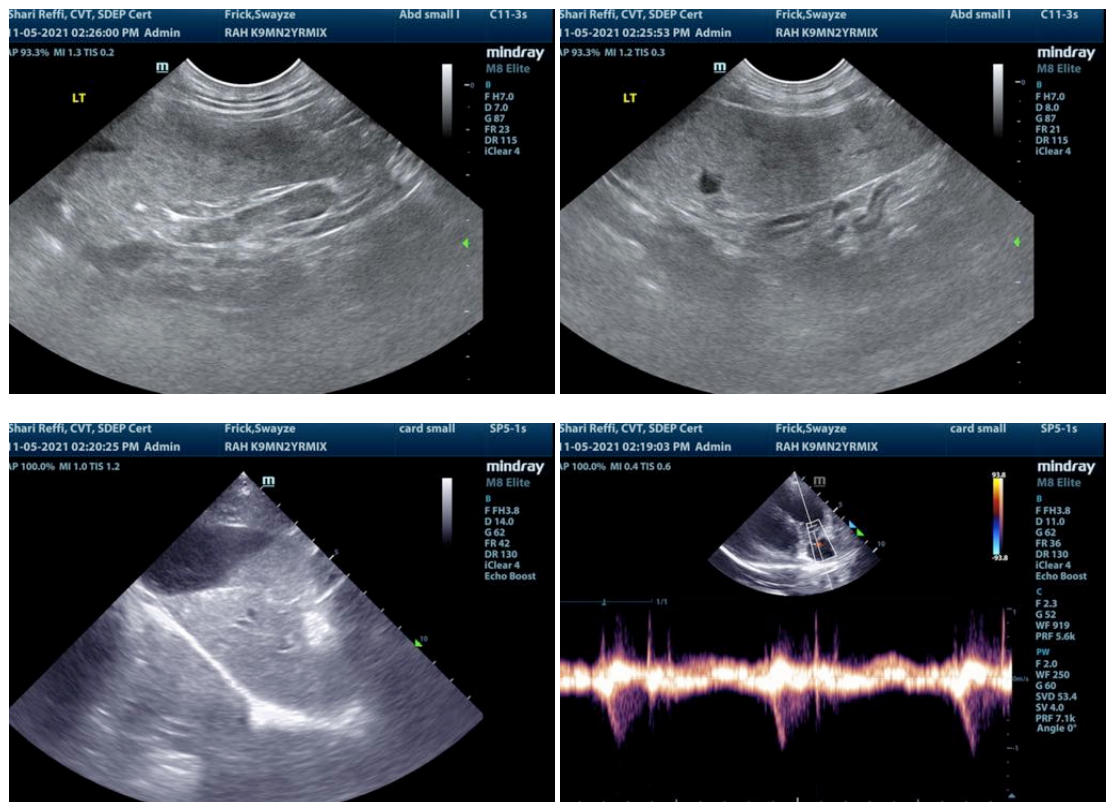
Dr. Maniar

**INVOICE**

92904

**DATE**

11/5/21





**PATIENT**

Swayze Frick

**SPECIES**

Canine

**BREED**

Mix

**SEX**

Neutered male

**AGE**

2 years

**WEIGHT**

65 lbs

**INTERPRETED BY**

Eric Lindquist, DMV  
DABVP, Cert. IVUSS

**IMAGING PERFORMED BY**

Shari Reffi, CVT

**HOSPITAL NAME**

Rockaway AH

**REFERRING VET**

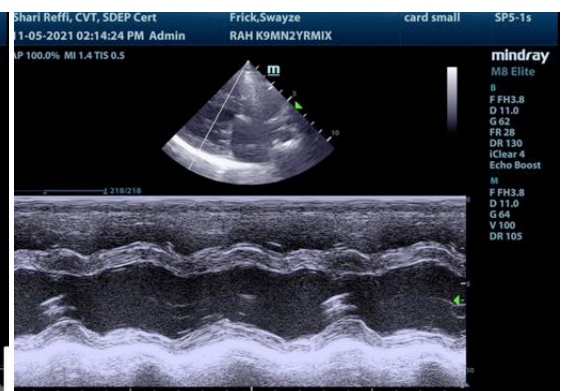
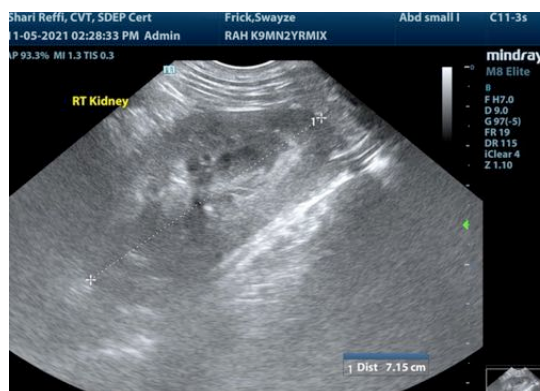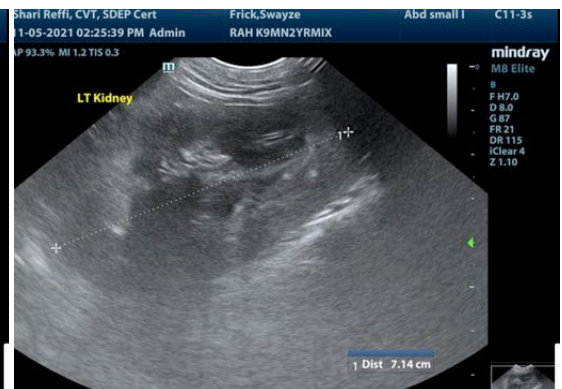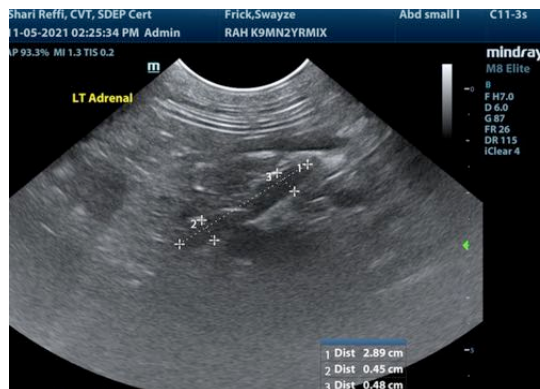
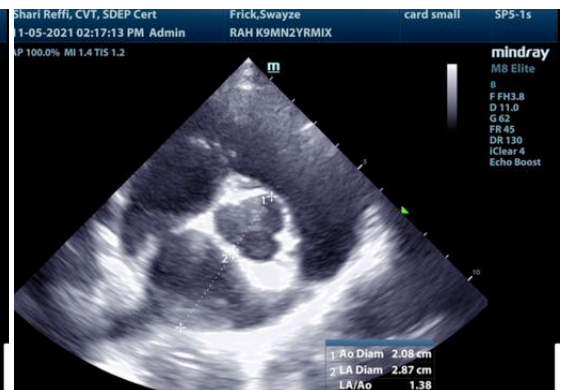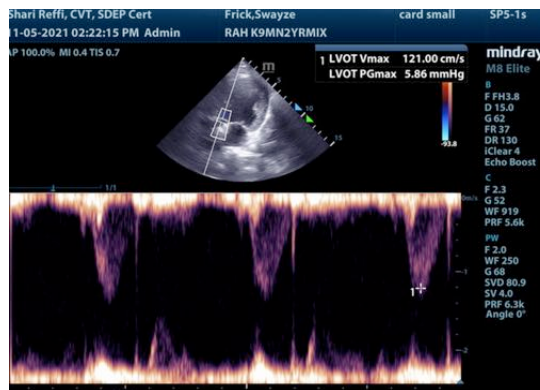
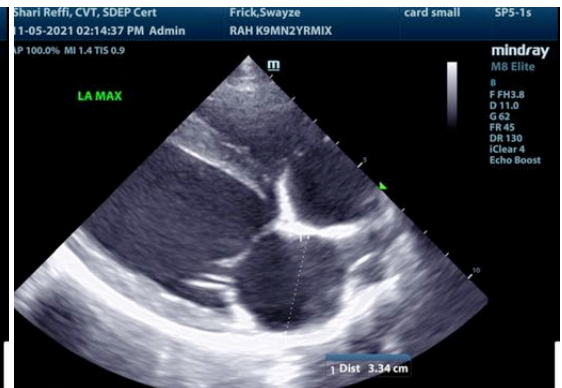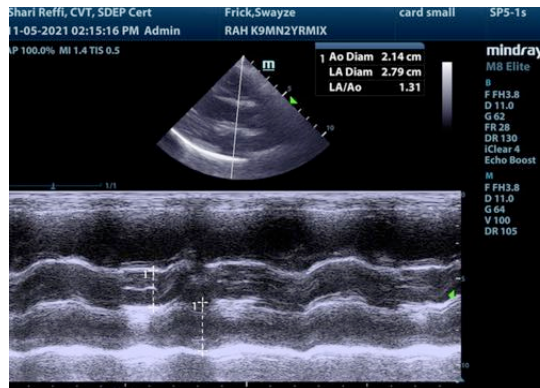
Dr. Maniar

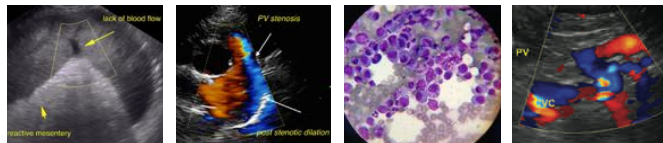
**INVOICE**

92904

**DATE**

11/5/21





**PATIENT**

Swayze Frick

veterinarian. No evaluation can be communicated regarding pathology that was not visible in the image/video clips provided.

Thank you for this referral. If the clinical or image interpretation does not parallel your findings or if I can be of any further assistance please contact me.

**SPECIES**

Canine

**Eric Lindquist, DMV, DABVP, Cert. IVUSS, CEO of SonoPath.com**  
Info@SonoPath.com

**BREED**

Mix

**SEX**

Neutered male

**AGE**

2 years

**WEIGHT**

65 lbs

**INTERPRETED BY**

Eric Lindquist, DMV  
DABVP, Cert. IVUSS

**IMAGING  
PERFORMED BY**

Shari Reffi, CVT

**HOSPITAL NAME**

Rockaway AH

**REFERRING VET**

Dr. Maniar

**INVOICE**

92904

**DATE**

11/5/21