



DATE PRESENTING CLINICAL SIGNS

11/4/25

Patient History: New mass in the neck - owner would like to find out organ of origin. Has history of a thyroid mass from hyperthyroidism - has radiocat and thyroid levels stable for years but mass never resolved. This appears to be a different mass on palpation.

PATIENT

Wessley Boegner

Current Medications: Calcitriol 200ng/ml 0.4 cc every 3.5 days
Labwork Results: Labwork not attached, reported as: Stage II renal disease
Date of Previous IntraPet Ultrasound: 6/2/22 AUS - attached.

SPECIES

Feline

Sedation: Declined.
Stat Report: Not requested.
Imaging Performed by: Rachel Brillhart, RDMS.

BREED

DSH

LIMITED ULTRASONOGRAPHIC EXAMINATION OF THE NECK

SEX

Neutered Male

The right thyroid lobe revealed cystic and nodular changes. The thyroid measured 2.24 cm x 0.80 cm with adjacent cystic structures that appear to potentially be lymph nodes. A cystic structure adjacent to the right thyroid lobe measured 1.3 cm x 1.2 cm.

AGE

3/21/09

The left thyroid lobe was unremarkable and uniform.

WEIGHT

19.84 lbs

- Nodular right thyroid lobe with adjacent thyroid tissue or possible lymph node involvement.

INTERPRETED BY

Eric Lindquist, DMV, DABVP, Cert. IVUSS

INTERPRETATION OF THE FINDINGS & FURTHER RECOMMENDATIONS

Surgical removal of all structures in the right thyroid region recommended, as they appear encapsulated and non-invasive. Ultrasound guided cytology and drainage of the lesions could also be considered for further definition. Thyroid carcinoma versus thyroid cyst and thyroiditis.

HOSPITAL NAME

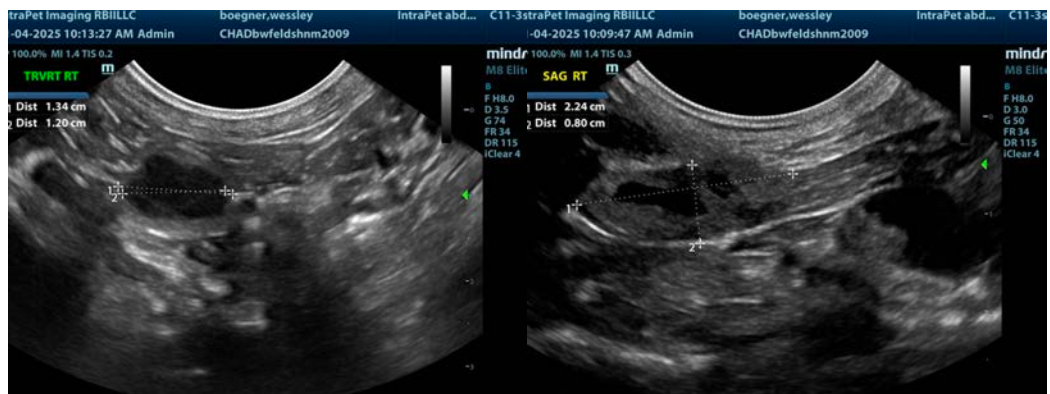
Chadwell Animal Hospital

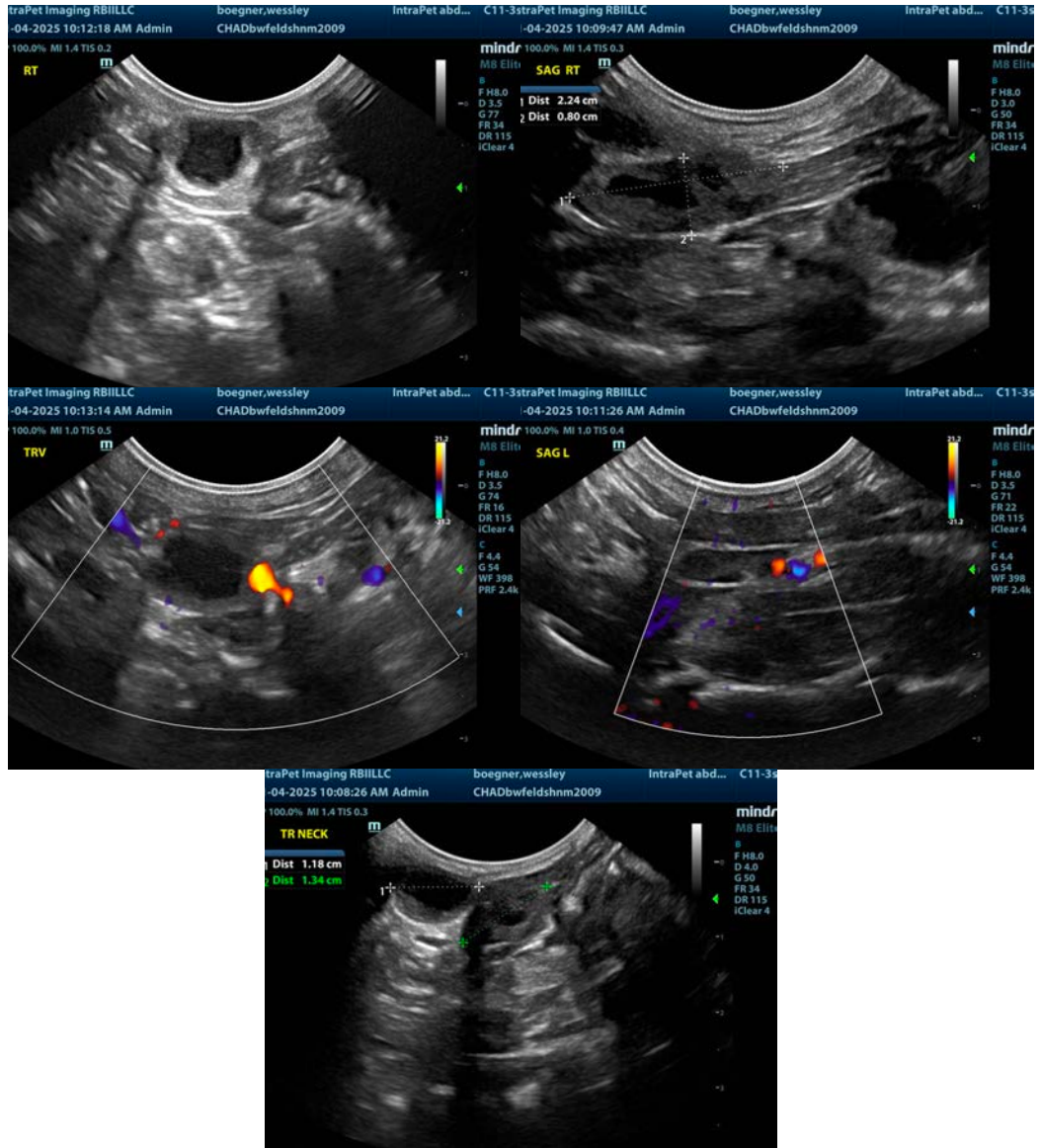
REFERRING VET

Dr. Weeks

INVOICE

71569





The information and recommendations provided are based on the images presented by the referring veterinarian/sonographer. No evaluation can be communicated regarding pathology that was not visible in the image/video clips provided.

Thank you for this referral. If the clinical or image interpretation does not parallel your findings or if I can be of any further assistance please contact me.

Eric Lindquist, DMV, DABVP(CFM), Cert. IVUSS,
CEO, Owner, Founder -- SonoPath.com
info@SonoPath.com