


**DATE PRESENTING CLINICAL SIGNS**

11/4/25

**Patient History:** P presented for presurgical examination for spay and deciduous teeth removal. P had a previous ultrasound last december at Bel Air Veterinary Hospital and diagnosed with suspected congenital renal dysplasia. P has been on Hill's k/d. On exam, p was BAR MM - pink, moist CRT < 2sec; CV/Resp - WNL; Abd - NSF; Musc- bilateral MPL; Skin/coat- WNL; oral -retained deciduous 104 and 204

**PATIENT**

Sophia Rozzi

**Current Medications:** Hill;s K/D.

**SPECIES**

Canine

**Labwork Results:** Labwork attached, reported as: Bloodwork: WNL (BUN 21, Cre 1.0, SDMA 11)

Fecal: Negative

**Date of Previous IntraPet Ultrasound:** 12/27/24. See attached.

**Sedation:** Not required to complete full diagnostic ultrasound.

**Stat Report:** Not requested.

**BREED**

Yorkshire Terrier

**Imaging Performed by:** Rachel Brilhart, RDMS.

**ULTRASONOGRAPHIC EXAMINATION OF THE ABDOMEN**
**SEX**

Intact Female

**Urinary System**

The **urinary bladder**, trigone, and pelvic urethra presented normal thicknesses and normal tone. The ureters were not visible which is normal. No uroliths or sediment were visualized and anechoic urine was present. No evidence of inflammatory or neoplastic changes were noted. Ureteral papillae were normal.

**AGE**

5/31/24

The **left kidney** pelvis revealed calculi up to 0.68 cm, with pyelectasia of 0.61 cm. Dystrophic changes and infarcts also noted.

**WEIGHT**

6 lbs

The **right kidney** revealed pinpoint mineralization and corticomedullary calculi. A pelvic calculus measured 0.60 cm. The right kidney measured 2.9 cm.

**INTERPRETED BY**

 Eric Lindquist, DMV,  
 DABVP, Cert. IVUSS

**Adrenal Glands**

Both **adrenal glands** were visualized and recognized as having normal shape, size, position and echogenicity for this breed. The phrenic vasculature, glandular echogenicity and detail were unremarkable. Capsule, cortex, and medullary definition were normal for this age patient. The left adrenal gland measured 1.83 cm x 0.44 cm at the caudal pole and 0.37 cm at the cranial pole. The right adrenal gland measured 1.67 cm x 0.43 cm at the caudal pole and 0.37 cm at the cranial pole.

**HOSPITAL NAME**

 Chadwell Animal  
 Hospital

**Spleen**

The **spleen** presented a smooth homogeneous parenchyma hyperechoic to liver and renal cortical parenchyma. The capsule was smooth without noticeable expansion or deviation from within the spleen or adjacent pathology. The splenic vasculature demonstrated normal volume without signs of congestion or thrombosis. No sonographic evidence of acute or chronic inflammatory, neoplastic, or infarctual changes were noted.

**REFERRING VET**

Dr. Heydt

**INVOICE**

71566

**Liver**

The **liver** images submitted revealed subjectively normal liver size, contour, and structure. Parenchymal echogenicity was naturally coarse and hypoechoic to the spleen. Vascular and biliary tracts were of normal volume with no evidence of congestion. The gallbladder presented acceptably thin walls with primarily anechoic content. The cystic and common bile ducts were normal. No pathological hepatic lymphadenopathy was evident. No overt structural evidence of inflammatory, infiltrative or regenerative pathology was evident.

### ***Gastrointestinal***

Examination of the **gastrointestinal tract** revealed a stomach and intestine free of stasis, of normal wall thickness, acceptable curvilinear mural detail, and peristaltic activity. Small and large intestine demonstrated normal luminal chyme and stool consistency respectively. No obstructive or overt infiltrative disease was noted. No associated abnormal lymphatic activity was noted.

### ***Pancreas***

The base and limbs of the **pancreas** were observed to be largely isoechoic to surrounding omental fat. Pancreatic duct and capsular contour were acceptably normal and parenchyma respected normal curvilinear patterns. No overt evidence of active inflammatory or neoplastic disease was noted.

### ***Other***

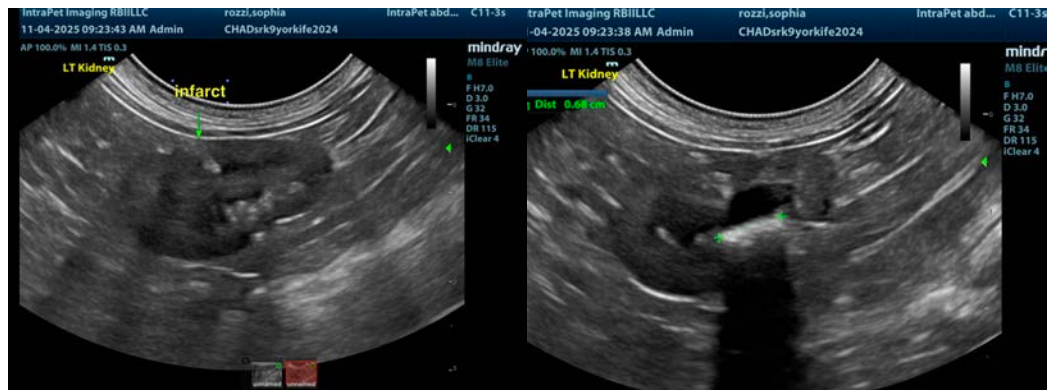
The uterus and ovaries were unremarkable.

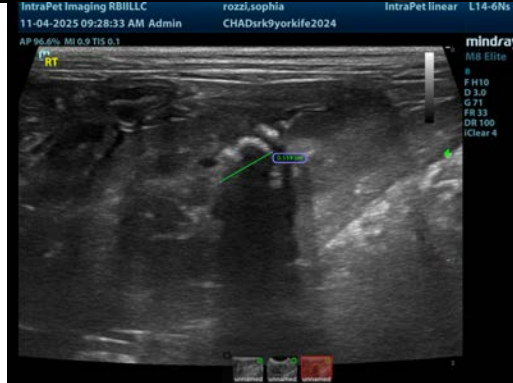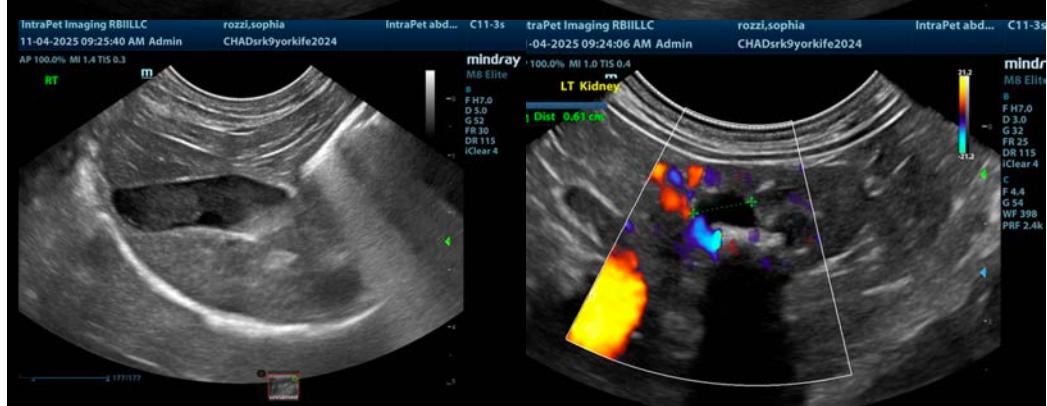
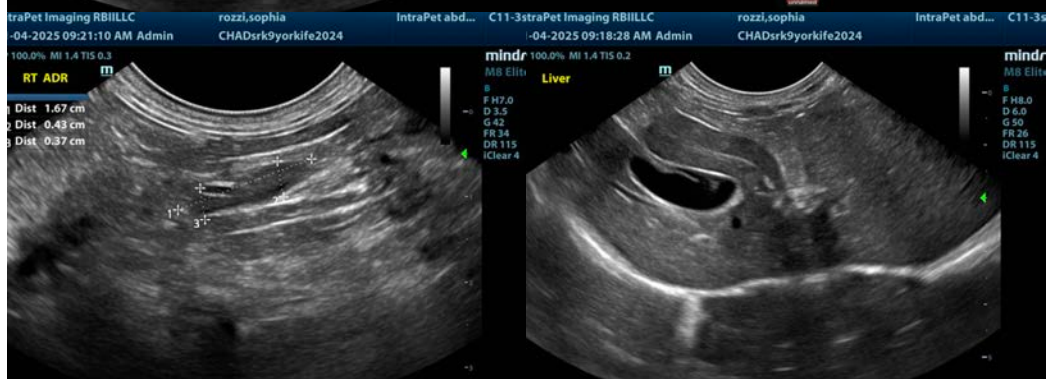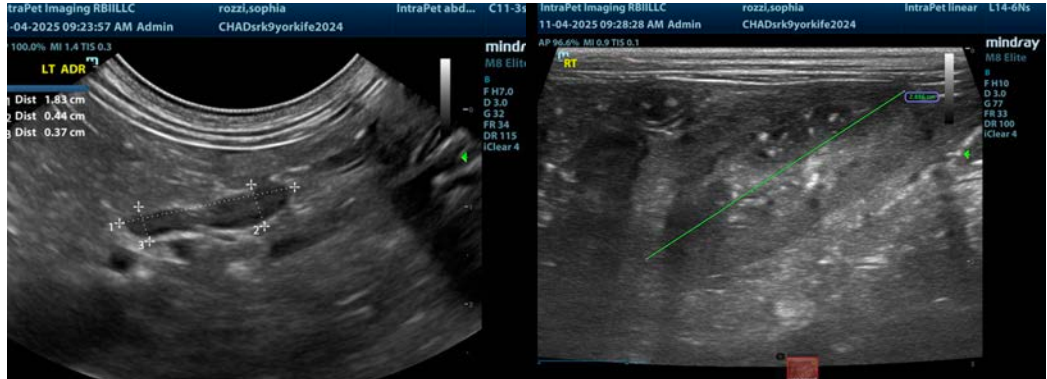
## **ULTRASONOGRAPHIC FINDINGS**

- Dystrophic left kidney changes with nephrolithiasis and secondary infarcts.
- Minor nephrolithiasis of the right kidney.

## **INTERPRETATION OF THE FINDINGS & FURTHER RECOMMENDATIONS**

Given the necessity for ovariectomy, left renal biopsy is warranted for further definition. Nephrotomy could also be considered, given the pelvic calculus that is partially obstruction in the left kidney and the mild pyelectasia. Some level of congenital dysplasia is possible in this patient but would necessitate renal biopsy for further definition. Full urinary workup and blood pressure indicated if not already performed to assess for inflammatory sediment and potential underlying related hypertension.





**The information and recommendations provided are based on the images presented by the referring veterinarian/sonographer. No evaluation can be communicated regarding pathology that was not visible in the image/video clips provided.**

Thank you for this referral. If the clinical or image interpretation does not parallel your findings or if I can be of any further assistance please contact me.

**Eric Lindquist**, DMV, DABVP(CFM), Cert. IVUSS,  
CEO, Owner, Founder -- SonoPath.com  
[info@SonoPath.com](mailto:info@SonoPath.com)