


DATE PRESENTING CLINICAL SIGNS

11/4/25

Patient History: Initially presented 10/28/25 for lethargy, vomiting. BW = severe azotemia, low plt estimate, hyperphosphatemia, hypoalbuminemia. Tx: Cerenia, IVF, mirtaz, Azodyl, Naraquin, metro. No significant improvement to azotemia with 3d hospitalization. Discharged 11/1. Some dribbling of urine, normal stream resumed 11/2. Clinically improved appetite, stop V+. Recheck 11/3: azotemia, slight e-lyte abnormalities; possible bacteriuria; suspected R anal gland mass; irregular sub-lumbar area on rads

PATIENT

Sabre Baroch

SPECIES

Canine

Current Medications: Cerenia SID starting 10/28

Azodyl, Naraquin, mirtaz, metro started 11/1

Labwork Results: Labwork attached, reported as: 10/29: plt 58k with some clumping (est 50,000-100,000)

Creat 6.0, BUN 121, SDMA 53, phos 8.9, alb 2.6, glob 2.9, T4 0.8. 10/31: istat only, creat 6.5, BUN 109

11/1: istat only, creat 6.3, BUN 126. 11/3: pending cbc with path review, creat 6.3, BUN > 140, Na 136, K 5.7, iCa 0.7

BREED

GSD

Date of Previous IntraPet Ultrasound: No previous.

Sedation: Not required to complete full diagnostic ultrasound.

SEX

Stat Report: Not requested.

Imaging Performed by: Rachel Brillhart, RDMS.

Neutered Male

ULTRASONOGRAPHIC EXAMINATION OF THE ABDOMEN
AGE

11/28/14

Urinary System

The **urinary bladder**, trigone, and pelvic urethra presented normal thicknesses and normal tone. The ureters were not visible which is normal. No uroliths or sediment were visualized and anechoic urine was present. No evidence of inflammatory or neoplastic changes were noted. Ureteral papillae were normal.

WEIGHT

96 lbs

The **kidneys** revealed largely normal size and structure, corticomedullary definition and ratio (cortex 1/3 of medulla) were essentially maintained with some age-related loss of curvilinear patterns regarding the capsule and C/M junction. The cortices presented largely uniform texture with some increased echogenicity expected for his age patient. Medullary structure differed distinctly from that of the cortex and no evidence. The kidneys do not appear end stage. The left kidney measured 8.6 cm with trace pyelectasia. The right kidney measured 8.16 cm.

INTERPRETED BY

 Eric Lindquist, DMV,
 DABVP, Cert. IVUSS

HOSPITAL NAME

 Chadwell Animal
 Hospital

REFERRING VET

Dr. Jones

Adrenal Glands

Both **adrenal glands** were visualized and recognized as having largely normal shape, size, position and acceptable echogenicity for this age group and breed. Some heterogeneity was noted within the adrenal parenchyma without concerning capsular distortion. These changes are likely age related but should be monitored by sonogram should the patient be suspected of having adrenal disease. Left measured 3.36 cm x 1.0 cm at the caudal pole and 0.74 cm at the cranial pole, with a hyperechoic 0.48 cm x 0.60 cm nodule at the caudal pole, likely benign. The right adrenal gland measured 3.93 cm x 0.96 cm at the caudal pole and 1.3 cm at the cranial pole.

INVOICE

71567

Spleen

The **spleen** presented mild uniform enlargement with folded contour, typical for the breed. This is typical for a German Shepherd.

Liver

The **liver** images submitted revealed subjectively normal liver size, contour, and structure. Parenchymal echogenicity was naturally coarse and hypoechoic to the spleen. Vascular and biliary tracts were of normal volume with no evidence of congestion. The gallbladder presented acceptably thin walls with primarily

anechoic content. The cystic and common bile ducts were normal. No pathological hepatic lymphadenopathy was evident. No overt structural evidence of inflammatory, infiltrative or regenerative pathology was evident.

Gastrointestinal

Examination of the **gastrointestinal tract** revealed a stomach and intestine free of stasis, of normal wall thickness, acceptable curvilinear mural detail, and peristaltic activity. Small and large intestine demonstrated normal luminal chyme and stool consistency respectively. No obstructive or overt infiltrative disease was noted. No associated abnormal lymphatic activity was noted.

Pancreas

The base and limbs of the **pancreas** were observed to be largely isoechoic to surrounding omental fat. Pancreatic duct and capsular contour were acceptably normal and parenchyma respected normal curvilinear patterns. No overt evidence of active inflammatory or neoplastic disease was noted.

Other

A sublumbar lymph node mass is noted in this patient, measuring approximately 5.0 cm. A separate medial iliac lymph node was enlarged, measuring 3.0 cm x 1.9 cm.

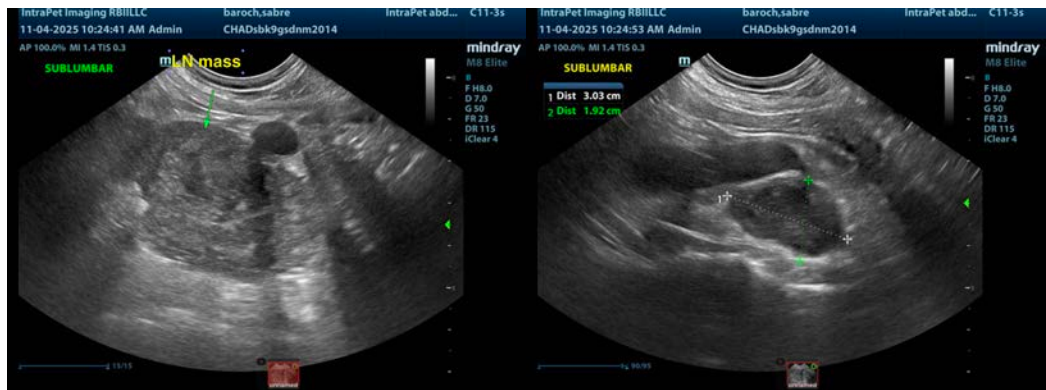
The right anal gland revealed a mineralizing irregular, nodular mass measuring 2.0 cm.

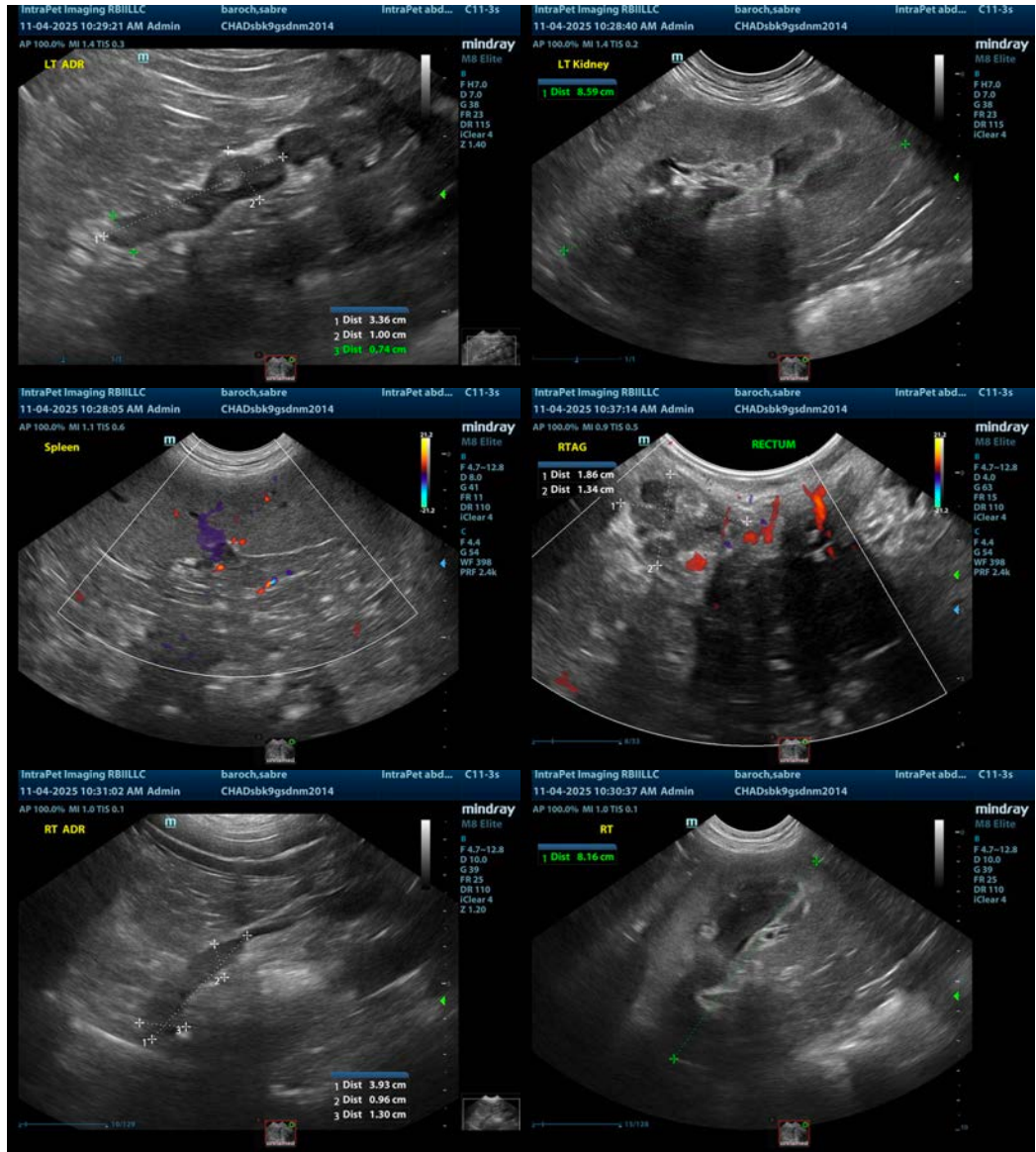
ULTRASONOGRAPHIC FINDINGS

- Right anal gland mass with metastatic pattern to the iliac and sublumbar lymph nodes.
- Mild splenic enlargement – typical for this breed.
- Unremarkable kidneys with age related changes.
- Age related hepatic changes.

INTERPRETATION OF THE FINDINGS & FURTHER RECOMMENDATIONS

The cause of azotemia is unclear in this patient. Acute insult suspected. However, metastatic anal gland carcinoma likely. FNA of the right anal gland and iliac/sublumbar lymph nodes recommended for confirmation.





The information and recommendations provided are based on the images presented by the referring veterinarian/sonographer. No evaluation can be communicated regarding pathology that was not visible in the image/video clips provided.

Thank you for this referral. If the clinical or image interpretation does not parallel your findings or if I can be of any further assistance please contact me.

Eric Lindquist, DMV, DABVP(CFM), Cert. IVUSS,
 CEO, Owner, Founder -- SonoPath.com
info@SonoPath.com