



**PATIENT**

Patterson Viteri

**SPECIES**

Feline

**BREED**

DSH

**SEX**

Neutered Male

**AGE**

9 Years

**WEIGHT**

24 lbs

**INTERPRETED BY**

Eric Lindquist, DMV,  
DABVP (CFM), Cert.  
IVUSS

**IMAGING PERFORMED BY**

Ashley Whitesell

**HOSPITAL NAME**

Dickson Animal Clinic

**REFERRING VET**

Dr. Richard Hovis

**INVOICE**

71549

**DATE**

11/4/25

**PRESENTING CLINICAL SIGNS**

Vomiting has stopped but now having trouble eating dry food - Has to throw dry food to back of mouth to eat it - Maybe throat sore from vomiting - Dr. Hovis just worried we are missing something with heart and abdomen, O Wanting to do an exam first before the ultrasound to see how P is improving. has 1.2mL Bonqat on board Blood Pressure Measurement Cuff Size 3 Location left front, sternal Systolic 167 Diastolic 126 MAP 135 HR 198

**ULTRASONOGRAPHIC EXAMINATION OF THE HEART & ABDOMEN**

FELINE CARDIAC PARAMETERS	BODY WEIGHT (lbs)	HR (BPM)	IVSd (cm)	LVIDd (cm)	LVWd (cm)	FS (%)	EF (%)
NORMAL PARAMETER	-----	150-240	0.3-0.6	1.0-2.1	0.25-0.6	35-67	80-100
PATIENT	24	170	0.55	1.5	0.53	45	--
FELINE CARDIAC PARAMETERS	LA/AO (M-mode)	LA/AO HEART BASE (Sisson)	LAD LA MAX 4 Chamber		LVOT VEL. (m/s)	RVOT VEL. (m/s)	IVRT (m/)
NORMAL PARAMETER	<1.5	1.6	0.7-1.7		<1.6	<1.3	40-60
PATIENT	1.1	1.1	--		1.2	0.8	NM
Adapted from June Boon, Veterinary Echocardiography, 1998 Sisson D et al. JVIM 1991; 5: 232, Jacobs et al. Am J Vet Res 1985; 46:1705							

**Cardiac Presentation**

The echocardiogram in this patient demonstrated normal **left atrial** size based on 3 separate LA measurements. The cranial and caudal **mitral** valve leaflets presented normal linear structure and kinetics.. The **left ventricle** presented normal thicknesses with linear contour and was not dilated nor restricted. The **myocardium** presented normal echogenicity without subjective evidence of significant fibrotic or ischemic disease. **Contractility** of the ventricular walls was adequate and in normal range for this patient evidenced by the fractional shortening measurement and subjective evaluation of the different regions and angles of the myocardium. The **left ventricular outflow** tract demonstrated normal laminar flow and subjective structural integrity. The **right atrium** and auricle revealed normal size, structure and content. No evidence of masses was noted or chamber overload. **Tricuspid** valvular assessment demonstrated adequate linear morphology and kinetics. The **right ventricle** was of normal size (1/3 diameter of LV), chordae structure, myocardial echogenicity and thickness. **Pulmonic** tract assessment revealed normal valve structure, laminar flow, and diameter (approx.1:1 pa/ao ratio). No visible **pericardial** or free pleura fluid was noted or extra cardiac pathology in the visible planes. The cranial **mediastinum** and **pericardial** regions were free of masses in the visible window.



## PATIENT

Patterson Viteri

## SPECIES

Feline

## BREED

DSH

## SEX

Neutered Male

## AGE

9 Years

## WEIGHT

24 lbs

## INTERPRETED BY

Eric Lindquist, DMV,  
DABVP (CFM), Cert.  
IVUSS

## IMAGING PERFORMED BY

Ashley Whitesell

## HOSPITAL NAME

Dickson Animal Clinic

## REFERRING VET

Dr. Richard Hovis

## INVOICE

71549

## DATE

11/4/25

## Urinary System

The **urinary bladder**, trigone, and pelvic urethra presented normal thicknesses and normal tone. The ureters were not visible which is normal. No uroliths or sediment were visualized and anechoic urine was present. No evidence of inflammatory or neoplastic changes were noted. Ureteral papillae were normal.

The **kidneys** revealed largely normal size and structure, corticomedullary definition and ratio (cortex 1/3 of medulla) were essentially maintained with some age-related loss of curvilinear patterns regarding the capsule and C/M junction. The cortices presented largely uniform texture with some increased echogenicity expected for his age patient. Medullary structure differed distinctly from that of the cortex and no evidence of pelvic dilation was present. The right kidney measured 4.7 cm. The left kidney measured 4.5 cm.

## Adrenal Glands

The **left adrenal gland** was visualized and recognized as having normal shape, size, position and echogenicity for this breed. The phrenic vasculature, glandular echogenicity and detail were unremarkable. Capsule, cortex, and medullary definition were normal for this age patient. The left adrenal gland measured 0.30 cm.

The region of the **right adrenal gland** was unremarkable.

## Spleen

The **spleen** presented a smooth homogeneous parenchyma hyperechoic to liver and renal cortical parenchyma. The capsule was smooth without noticeable expansion or deviation from within the spleen or adjacent pathology. The splenic vasculature demonstrated normal volume without signs of congestion or thrombosis. No sonographic evidence of acute or chronic inflammatory, neoplastic, or infarctual changes were noted.

## Liver

The **liver** images submitted revealed subjectively normal liver size, contour, and structure. Parenchymal echogenicity was naturally coarse and hypoechoic to the spleen. Vascular and biliary tracts were of normal volume with no evidence of congestion. The gallbladder presented acceptably thin walls with primarily anechoic content. The cystic and common bile ducts were normal. No pathological hepatic lymphadenopathy was evident. No overt structural evidence of inflammatory, infiltrative or regenerative pathology was evident.

## Gastrointestinal

Slight density such as hairball accumulation noted in the **pylorus**. The small intestines and colon were unremarkable with normal curvilinear mural patterns and content.

## Pancreas

The base and limbs of the **pancreas** were observed to be largely isoechoic to surrounding omental fat. Pancreatic duct and capsular contour were acceptably normal and parenchyma respected normal curvilinear patterns. No overt evidence of active inflammatory or neoplastic disease was noted.



## PATIENT

Patterson Viteri

## SPECIES

Feline

## BREED

DSH

## SEX

Neutered Male

## AGE

9 Years

## WEIGHT

24 lbs

## INTERPRETED BY

Eric Lindquist, DMV,  
DABVP (CFM), Cert.  
IVUSS

## IMAGING PERFORMED BY

Ashley Whitesell

## HOSPITAL NAME

Dickson Animal Clinic

## REFERRING VET

Dr. Richard Hovis

## INVOICE

71549

## DATE

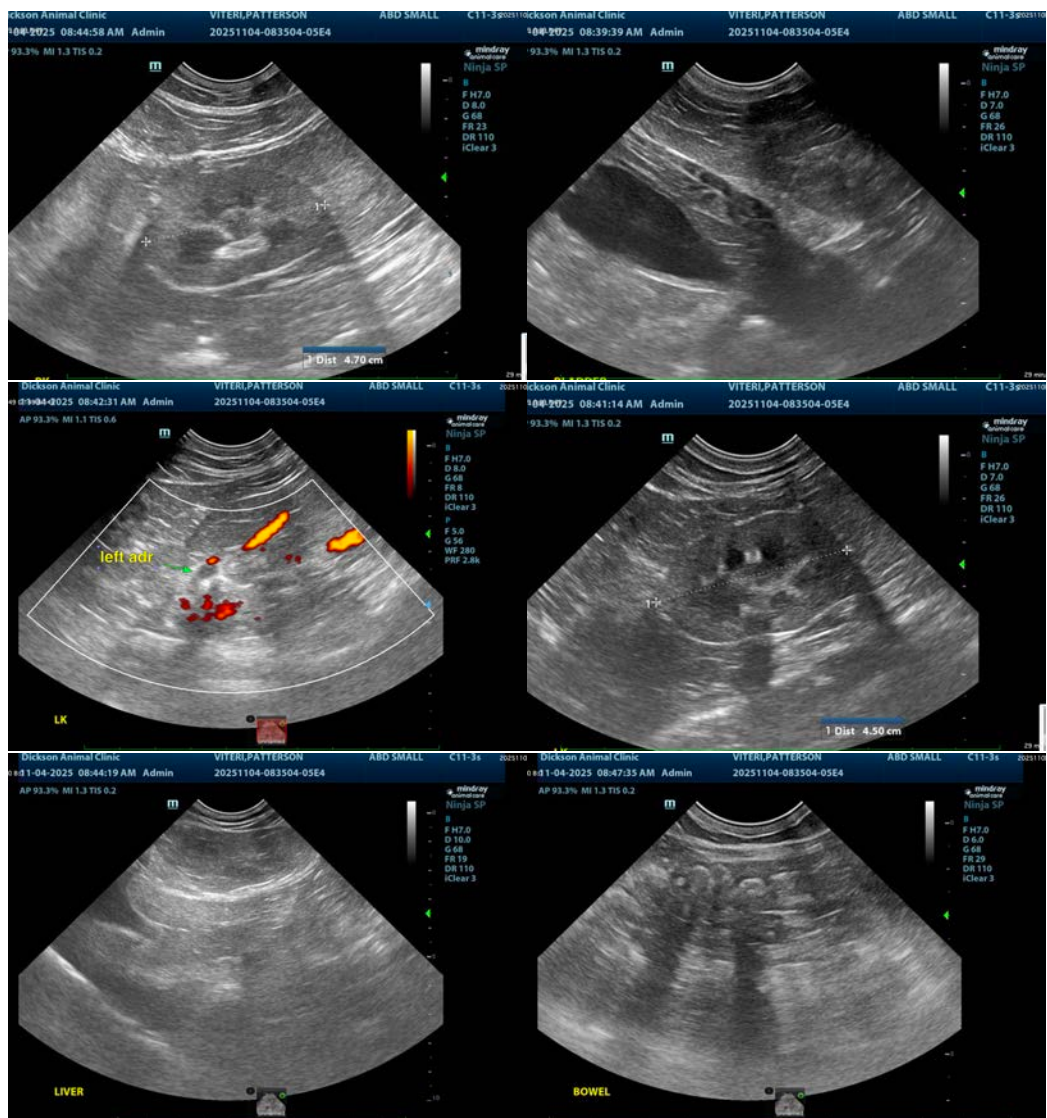
11/4/25

## ULTRASONOGRAPHIC FINDINGS

- Normal echocardiogram, no evidence of pathology.
- Age related renal changes.
- Possible hairball in the pylorus.

## INTERPRETATION OF THE FINDINGS & FURTHER RECOMMENDATIONS

The degenerative changes in the kidneys may be contributing to hypertension in this patient. Oral examination or endoscopy may be appropriate in this patient. If the patient was not excited at the time of blood pressures, then anti-hypertensives would be indicated. However, there is no structural evidence of GI or abdominal disease in this patient. I cannot rule out esophageal or oral inflammation or pathology. Hairball management and GI protectants indicated.





**PATIENT**

Patterson Viteri

**SPECIES**

Feline

**BREED**

DSH

**SEX**

Neutered Male

**AGE**

9 Years

**WEIGHT**

24 lbs

**INTERPRETED BY**

Eric Lindquist, DMV,  
DABVP (CFM), Cert.  
IVUSS

**IMAGING PERFORMED BY**

Ashley Whitesell

**HOSPITAL NAME**

Dickson Animal Clinic

**REFERRING VET**

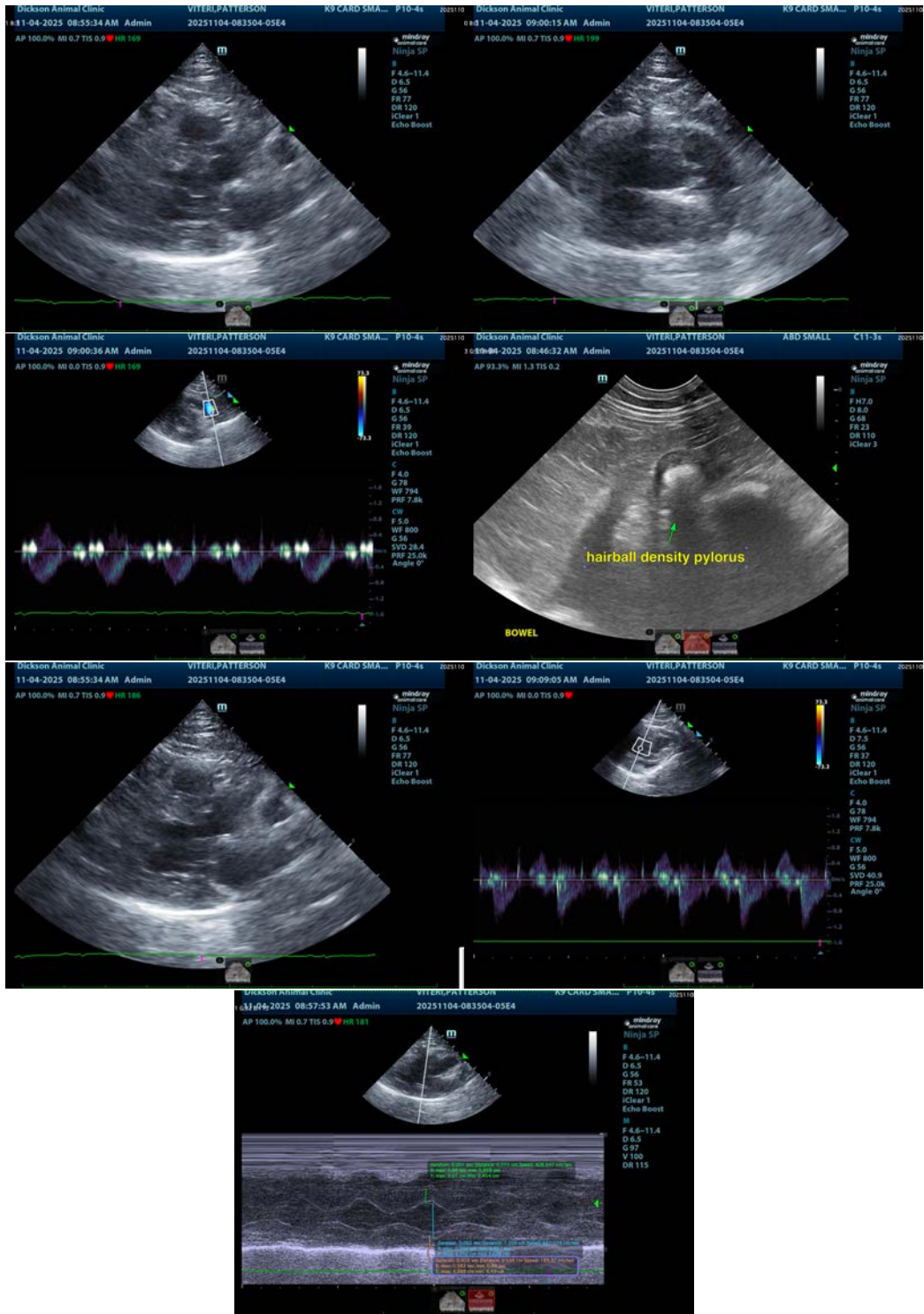
Dr. Richard Hovis

**INVOICE**

71549

**DATE**

11/4/25





## PATIENT

Patterson Viteri

## SPECIES

Feline

## BREED

DSH

## SEX

Neutered Male

## AGE

9 Years

## WEIGHT

24 lbs

## INTERPRETED BY

Eric Lindquist, DMV,  
DABVP (CFM), Cert.  
IVUSS

## IMAGING PERFORMED BY

Ashley Whitesell

## HOSPITAL NAME

Dickson Animal Clinic

## REFERRING VET

Dr. Richard Hovis

## INVOICE

71549

## DATE

11/4/25

The information and recommendations provided are based on the images presented by the referring veterinarian/sonographer. No evaluation can be communicated regarding pathology that was not visible in the image/video clips provided.

Thank you for this referral. If the clinical or image interpretation does not parallel your findings or if I can be of any further assistance please contact me.

**Eric Lindquist**, DMV, DABVP(CFM), Cert. IVUSS,  
CEO, Owner, Founder -- SonoPath.com  
[info@SonoPath.com](mailto:info@SonoPath.com)