



## PATIENT

Edward Langdon

## SPECIES

Canine

## BREED

Mix

## SEX

Neutered male

## AGE

7 years

## WEIGHT

55.2 lbs

## INTERPRETED BY

Eric Lindquist, DMV  
DABVP, Cert. IVUSS

## IMAGING PERFORMED BY

Dr. LaCroix

## HOSPITAL NAME

Inspire AH- Highlands  
Ranch

## REFERRING VET

Dr. Wolsky

## INVOICE

68316

## DATE

11/4/25

## PRESENTING CLINICAL SIGNS

History: Patient is on fluoxetine, did screening labs for NSAID, o gave one dose of NSAID in the month, liver values increased. No c/s of HAC noted by owner.

Abnormal PE/Chem/CBC/UA Results: 10/6- ALT 116, ALKP 353, Triglycerides 993, USG 1.008  
10/24- ALT 182, ALKP 421 (did not have urine on this sample)

## ULTRASONOGRAPHIC EXAMINATION OF THE ABDOMEN

### Urinary System

The **urinary bladder**, trigone, and pelvic urethra presented normal thicknesses and normal tone. The ureters were not visible which is normal. No uroliths or sediment were visualized and anechoic urine was present. No evidence of inflammatory or neoplastic changes was noted. Ureteral papillae were normal.

The **kidneys** revealed normal size and structure, corticomedullary definition and ratio for this age. The cortices presented largely uniform texture with normal echogenic relationship to liver and spleen. Medullary structure differed distinctly from the cortex and no evidence of pelvic dilation was present. The capsules were acceptably uniform without significant irregularities. The left kidney measured 5.9 cm. The right kidney measured 5.2 cm.

### Adrenal Glands

Both **adrenal glands** were visualized and recognized as having normal shape, size, position and echogenicity for this breed. The phrenic vasculature, glandular echogenicity and detail were unremarkable. Capsule, cortex, and medullary definition were normal for this age patient. The left adrenal gland measured 0.48 cm at the caudal pole and 0.53 cm at the cranial pole. The right adrenal gland measured 1.5 cm at the cranial pole and 0.7 cm at the caudal pole.

### Spleen

The **spleen** presented a smooth homogeneous parenchyma hyperechoic to liver and renal cortical parenchyma. The capsule was smooth without noticeable expansion or deviation from within the spleen or adjacent pathology. The splenic vasculature demonstrated normal volume without signs of congestion or thrombosis. No sonographic evidence of acute or chronic inflammatory, neoplastic, or infarctual changes was noted.

### Liver

The **liver** images from right and left intercostal as well as subcostal views revealed subjectively normal liver size, contour, and structure. Some age-related parenchymal remodeling was noted but likely not clinically significant at this time. Vascular and biliary tracts were of normal volume and no evidence of congestion was noted. The gallbladder presented some dependent debris with essentially normal contour. The cystic and common bile ducts were normal. No overt evidence of active inflammatory,



## PATIENT

Edward Langdon

## SPECIES

Canine

## BREED

Mix

## SEX

Neutered male

## AGE

7 years

## WEIGHT

55.2 lbs

## INTERPRETED BY

Eric Lindquist, DMV  
DABVP, Cert. IVUSS

## IMAGING PERFORMED BY

Dr. LaCroix

## HOSPITAL NAME

Inspire AH- Highlands  
Ranch

## REFERRING VET

Dr. Wolsky

## INVOICE

68316

## DATE

11/4/25

infiltrative or regenerative pathology was noted but should be paired with current or past LE elevations regarding any clinical significance to this presentation. The hepatic lymph nodes were unremarkable.

## *Gastrointestinal*

Examination of the **gastrointestinal tract** revealed a stomach and intestine free of stasis, of normal wall thickness, acceptable curvilinear mural detail, and peristaltic activity. Small and large intestine demonstrated normal luminal chyme and stool consistency respectively. No obstructive or overt infiltrative disease was noted. No associated abnormal lymphatic activity was noted.

## *Pancreas*

The base and limbs of the **pancreas** were observed to be largely isoechoic to surrounding omental fat. Pancreatic duct and capsular contour were acceptably normal and parenchyma respected normal curvilinear patterns. No overt evidence of active inflammatory or neoplastic disease was noted.

## ULTRASONOGRAPHIC FINDINGS

- Structurally unremarkable abdomen.
- Age related hepatic changes, likely reactive hepatopathy.

## INTERPRETATION OF THE FINDINGS & FURTHER RECOMMENDATIONS

FNA of the liver can be considered for further definition.

The hepatic clinical sonographic presentation is most consistent with Reactive Hepatopathy which is the most common cause of liver enzyme elevation in dogs and cats. The presumption is that gut and other organ antigen stimuli may be causing a low-grade immune response through portal system with which the liver is reacting to causing low-grade enzyme elevations. US-guided FNA could be performed to assess if low grade lymphoplasmacytic inflammation is present that would support this theory. If FNA is performed, please ask the cytologist to emphasize the primary inflammatory cell type. Empirical treatment measures to address this issue can include diet change to hydrolyzed diet, probiotics, deworming, nutraceuticals (SAME, Actigall...), dental exam and cleaning, and potentially antibiotics such as Clavamox. Metronidazole and Tylosin have traditionally been utilized for this purpose but new studies show that both these antibiotics can disrupt the normal intestinal bacterial flora (intestinal dysbiosis) for weeks and up to 4-6 months. Therefore, Metronidazole and Tylosin should be utilized as a last resort if other efforts have not been effective and sonographic organ appearance remains benign.



**PATIENT**

Edward Langdon

**SPECIES**

Canine

**BREED**

Mix

**SEX**

Neutered male

**AGE**

7 years

**WEIGHT**

55.2 lbs

**INTERPRETED BY**

Eric Lindquist, DMV  
DABVP, Cert. IVUSS

**IMAGING PERFORMED BY**

Dr. LaCroix

**HOSPITAL NAME**

Inspire AH- Highlands  
Ranch

**REFERRING VET**

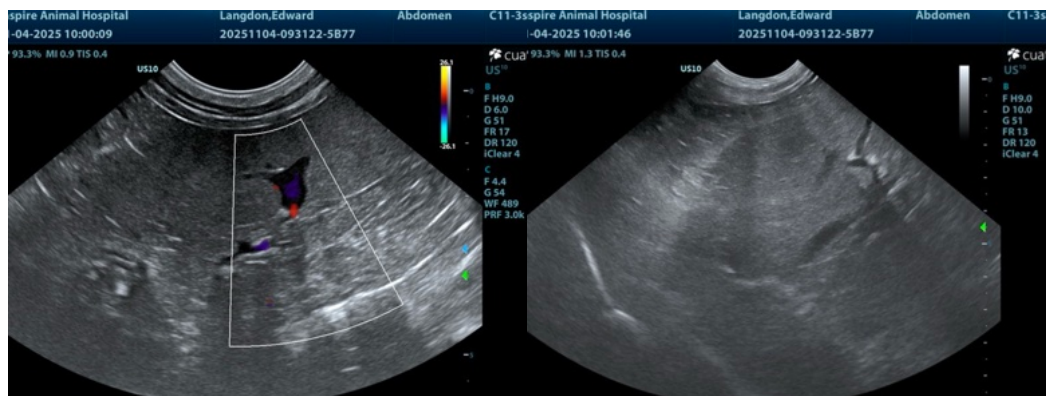
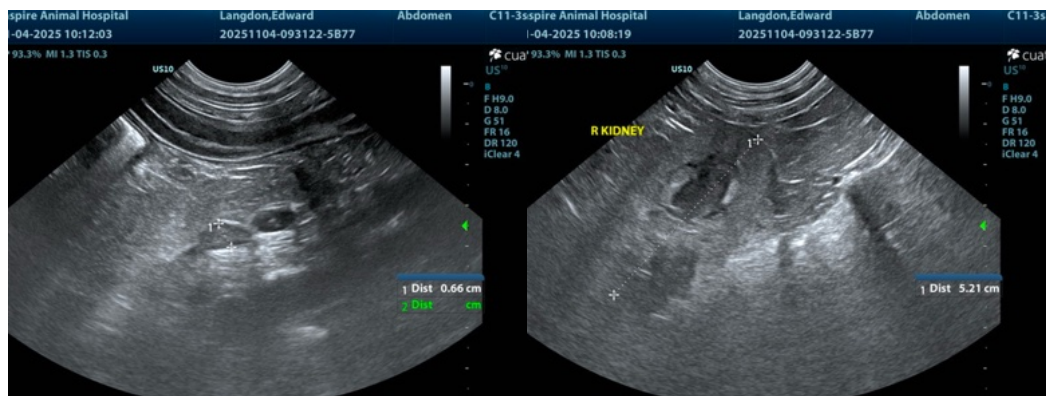
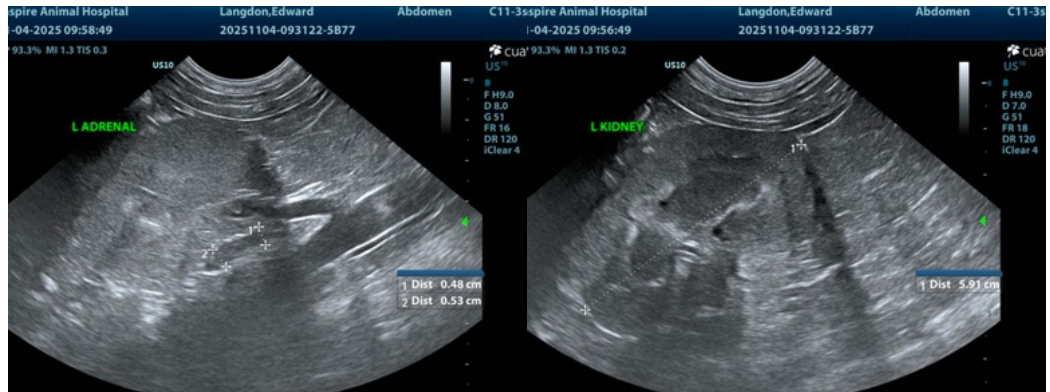
Dr. Wolsky

**INVOICE**

68316

**DATE**

11/4/25





## PATIENT

Edward Langdon

## SPECIES

Canine

## BREED

Mix

## SEX

Neutered male

## AGE

7 years

## WEIGHT

55.2 lbs

## INTERPRETED BY

Eric Lindquist, DMV  
DABVP, Cert. IVUSS

## IMAGING PERFORMED BY

Dr. LaCroix

## HOSPITAL NAME

Inspire AH- Highlands  
Ranch

## REFERRING VET

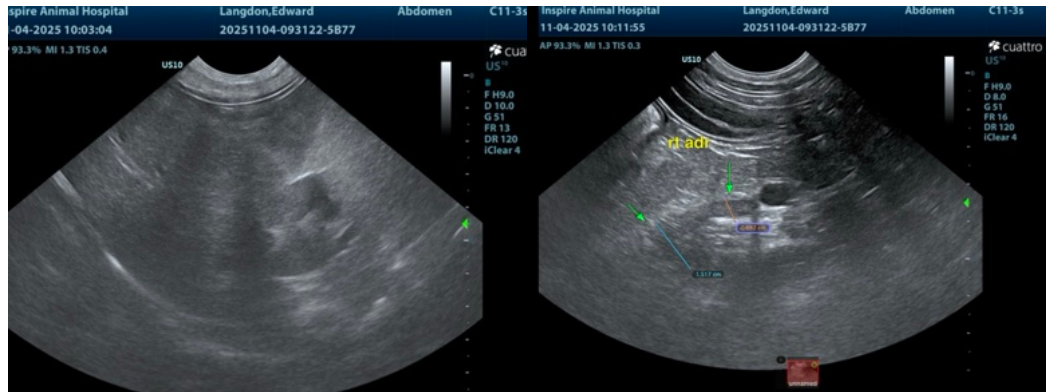
Dr. Wolsky

## INVOICE

68316

## DATE

11/4/25



The information and recommendations provided are based on the images presented by the referring veterinarian/sonographer. No evaluation can be communicated regarding pathology that was not visible in the image/video clips provided.

Thank you for this referral. If the clinical or image interpretation does not parallel your findings or if I can be of any further assistance please contact me.

Eric Lindquist, DMV, DABVP (CFM), Cert. IVUSS, CEO of SonoPath.com

[info@SonoPath.com](mailto:info@SonoPath.com)