



PATIENT

Sterline Schaaf

PRESENTING CLINICAL SIGNS

History: History of sensitive stomach. Had done well on ID for 2 years over the last three months started with chronic v/d. Bloodwork normal. Eating fine. Energy fine.

SPECIES

Feline

ULTRASONOGRAPHIC EXAMINATION OF THE ABDOMEN

Urinary System

BREED

Domestic Shorthair

The **urinary bladder**, trigone, and pelvic urethra presented normal thicknesses and normal tone. The ureters were not visible which is normal. No uroliths or sediment were visualized and anechoic urine was present. No evidence of inflammatory or neoplastic changes was noted. Ureteral papillae were normal.

SEX

Netuered male

The **kidneys** revealed normal size and structure, corticomedullary definition and ratio for this age. The cortices presented largely uniform texture with normal echogenic relationship to liver and spleen. Medullary structure differed distinctly from the cortex and no evidence of pelvic dilation was present. The capsules were acceptably uniform without significant irregularities. The left kidney measured 4.2 cm. The right kidney measured 4.0 cm.

AGE

6 years

WEIGHT

12.75 lbs

Adrenal Glands

Both **adrenal glands** were visualized and recognized as having normal shape, size, position and echogenicity for this breed. The phrenic vasculature, glandular echogenicity and detail were unremarkable. Capsule, cortex, and medullary definition were normal for this age patient.

INTERPRETED BY

Eric Lindquist, DMV
DABVP, Cert. IVUSS

Spleen

IMAGING PERFORMED BY

Dr. Buss

The **spleen** presented a smooth homogeneous parenchyma hyperechoic to liver and renal cortical parenchyma. The capsule was smooth without noticeable expansion or deviation from within the spleen or adjacent pathology. The splenic vasculature demonstrated normal volume without signs of congestion or thrombosis. No sonographic evidence of acute or chronic inflammatory, neoplastic, or infarctual changes was noted.

HOSPITAL NAME

Kings VH

Liver

REFERRING VET

Dr. Buss

The **liver** images submitted revealed subjectively normal liver size, contour, and structure. Parenchymal echogenicity was naturally coarse and hypoechoic to the spleen. Vascular and biliary tracts were of normal volume with no evidence of congestion. The gallbladder presented acceptably thin walls with primarily anechoic content. The cystic and common bile ducts were normal. No pathological hepatic lymphadenopathy was evident. No overt structural evidence of inflammatory, infiltrative or regenerative pathology was evident.

INVOICE

42339

Gastrointestinal

DATE

11/4/22

The **gastrointestinal** tract revealed hyperperistalsis, regional luminal dilation and excessive gas. Minor intestinal wall thickening was noted. The stomach was empty.



PATIENT

Sterline Schaaf

SPECIES

Feline

BREED

Domestic Shorthair

SEX

Netuered male

AGE

6 years

WEIGHT

12.75 lbs

INTERPRETED BY

Eric Lindquist, DMV
DABVP, Cert. IVUSS

IMAGING PERFORMED BY

Dr. Buss

HOSPITAL NAME

Kings VH

REFERRING VET

Dr. Buss

INVOICE

42339

DATE

11/4/22

Pancreas

The base and limbs of the **pancreas** were observed to be largely isoechoic to surrounding omental fat. Pancreatic duct and capsular contour were acceptably normal and parenchyma respected normal curvilinear patterns. No overt evidence of active inflammatory or neoplastic disease was noted.

Free Abdomen

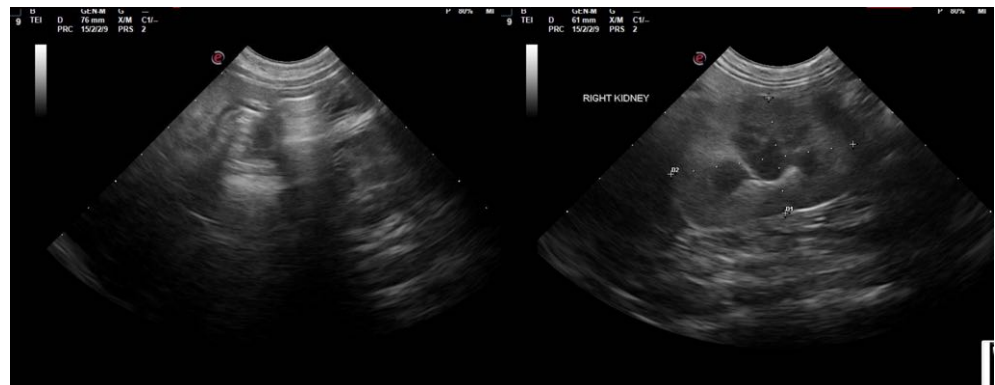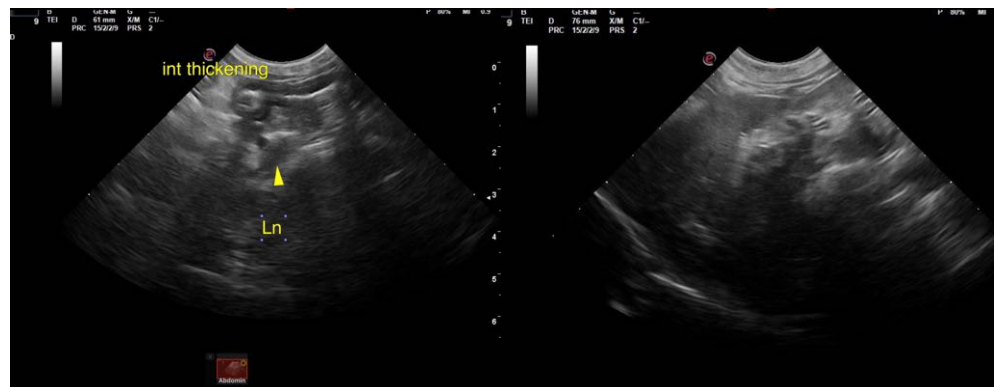
Regional lymph nodes are slightly enlarged and reactive.

ULTRASONOGRAPHIC FINDINGS

Variable, non-specific intestinal thickening with minor regional lymphadenopathy.

INTERPRETATION OF THE FINDINGS & FURTHER RECOMMENDATIONS

Inflammatory bowel is likely. I cannot rule out a pre-neoplastic state for potential emerging lymphoma. If weight loss and GI signs are a persistent issue then a recheck sonogram is recommended in a month.





PATIENT

Sterline Schaaf

SPECIES

Feline

BREED

Domestic Shorthair

SEX

Netuered male

AGE

6 years

WEIGHT

12.75 lbs

INTERPRETED BY

Eric Lindquist, DMV
DABVP, Cert. IVUSS

**IMAGING
PERFORMED BY**

Dr. Buss

HOSPITAL NAME

Kings VH

REFERRING VET

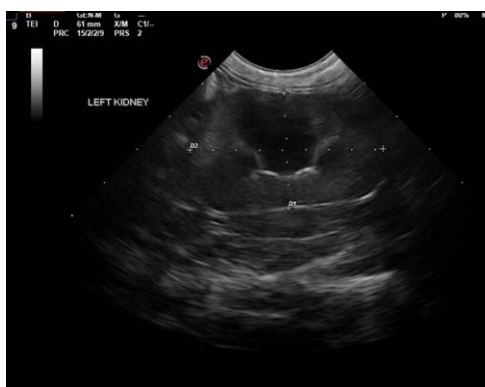
Dr. Buss

INVOICE

42339

DATE

11/4/22



The information and recommendations provided are based on the images presented by the referring veterinarian/sonographer. No evaluation can be communicated regarding pathology that was not visible in the image/video clips provided.

Thank you for this referral. If the clinical or image interpretation does not parallel your findings or if I can be of any further assistance please contact me.

Eric Lindquist, DMV, DABVP, Cert. IVUSS, CEO of SonoPath.com
info@SonoPath.com