



PATIENT

Cletus Eggleston

SPECIES

Canine

BREED

Bulldog

SEX

Neutered Male

AGE

8 Years

WEIGHT

58.96 Pounds

INTERPRETED BY

Eric Lindquist, DMV,
DABVP, Cert. IVUSS

IMAGING PERFORMED BY

Jenna Walsh, CVT

HOSPITAL NAME

Balanced Veterinary
Care

REFERRING VET

Dr. Wright

DATE

11/4/22

Invoice

17977

PRESENTING CLINICAL SIGNS

History: In July had a crisis episode - diarrhea, lethargic, panting excessively. BW returned normal Checked cortisol - it was low, treated for Addison's (percorton, oral steroids) Improved initially Oct - started urinating and drinking excessively (every hour) - changed steroid dose, re-ran blood panels (all wnl, except cortisol) Now - still drinking and urinating more than normal painful abdomen (groans when stretching and when palpated) Panting excessively Heart Rate and Respiratory Rates HR - 104 RR- panting Blood Pressure Measurements None taken Current Medications Thyroid Tabs 0.6mg (1/2 tab BID), Medrol 1mg SID Primary Question/Differential to Be Answered in This Exam R/O any abdominal abnormalities that may be causing the painful abdomen (tumors/masses) R/O adrenals tumors or abnormalities that could have caused the first crisis episode. Cardiac - making sure everything is wnl, verify that the excessive panting is not caused by heart disease.

Abnormal PE/Chem/CBC/UA Results: July- SDMA high at 16 Cortisol low at 1.1 CPL wnl at 30 Aug- Chloride low at 105 Oct- Cortisol low at 0.2 SDMA 11 (wnl) Chloride low at 104

ULTRASONOGRAPHIC EXAMINATION OF THE HEART & ABDOMEN

CANINE CARDIAC PARAMETERS	MR VMAX (m/s)	TR VMAX (m/s)	LA/AO (Boon method)	LA/AO (Heart Base; Swe)	FS (%)	EF (%)	EPSS (cm)
NORMAL PARAMETER	4.5-5.5	<2.7	1.3	<1.3	28-40	40-100	<0.6
PATIENT	--	2.9	1.0	1.0	34	64	0.48
CANINE CARDIAC PARAMETERS	HR (BPM)	AV VMAX (m/s)	PV MAX (m/s)	BODY WEIGHT (kg)	LA 2D short axis Base view (cm)	LVIDd Avg; 2D and m-mode short axis (cm)	LVIDs Avg; 2D and m-mode short axis (cm)
NORMAL PARAMETER	50-100	0.7-1.7	0.7-1.6				
PATIENT	95	1.10	.61	--	3.8	3.43	--

Cardiac Presentation

The echocardiogram presented a prominent **right heart** with mild **right ventricular** hypertrophy, and normal **right atrial** size. **Tricuspid** insufficiency was noted. No evidence of neoplasia was noted in the right auricle, or elsewhere in the heart. The **pulmonary artery** was uniformly prominent with mildly depressed pulmonic velocity measured on PW Doppler. No overt heartworms were noted in the main or visible deep pulmonary arteries. Yet, theoretically heartworms could be present in the deep pulmonary vasculature out of visible sonographic range. More likely, however, this prominent right heart is due to excessive intra-thoracic pressures caused by chronic respiratory disease or



PATIENT

Cletus Eggleston

SPECIES

Canine

BREED

Bulldog

SEX

Neutered Male

AGE

8 Years

WEIGHT

58.96 Pounds

INTERPRETED BY

Eric Lindquist, DMV,
DABVP, Cert. IVUSS

IMAGING PERFORMED BY

Jenna Walsh, CVT

HOSPITAL NAME

Balanced Veterinary
Care

REFERRING VET

Dr. Wright

DATE

11/4/22

Invoice

17977

potentially excessive intra-thoracic fat (Pickwickian syndrome). The **left heart** demonstrated a linear **ventricular septum**. Contractility was functionally adequate demonstrated by the FS% measurement. The mitral valve presented adequate apposition with trivial insufficiency, not clinically significant. No significant **left atrial** dilation was noted. The **left ventricular outflow** demonstrated normal flow patterns and velocities through the aortic valve. No evidence of tumor, pericardial or pleural effusion was noted. The visible **extra-cardiac** tissues were uniformly linear without evidence of masses, infiltrative or inflammatory mediastinal tissue. No evident arrhythmic activity was noted during the exam.

Urinary System

The **urinary bladder**, trigone, and pelvic urethra presented normal thicknesses and normal tone. The ureters were not visible which is normal. No uroliths or sediment were visualized and anechoic urine was present. No evidence of inflammatory or neoplastic changes were noted. Ureteral papillae were normal. The pelvic urethra was imaged 2.0 cm beyond the cystourethral junction. The residual prostate was uniform, measuring 1.9 cm.

The **kidneys** revealed normal size and structure, corticomedullary definition and ratio for this age. The cortices presented largely uniform texture with normal echogenic relationship to liver and spleen. Medullary structure differed distinctly from the cortex and no evidence of pelvic dilation was present. The capsules were acceptably uniform without significant irregularities. The right kidney measured 6.44 cm. The left kidney measured 7.04 cm.

Adrenal Glands

The **left adrenal gland** revealed moderate excessive enlargement at the cranial pole, measuring 3.23 cm x 1.24 cm at the cranial pole and 0.8 cm at the caudal pole. A slight nodule or cyst was noted at the cranial pole of the left adrenal gland as well.

Minor heterogenous changes were noted in the caudal pole of the **right adrenal gland**. The right adrenal gland measured 2.74 cm x 0.9 cm at the caudal pole and 0.56 cm at the cranial pole.

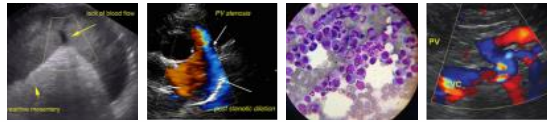
Spleen

The **spleen** presented a smooth homogeneous parenchyma hyperechoic to liver and renal cortical parenchyma. The capsule was smooth without noticeable expansion or deviation from within the spleen or adjacent pathology. The splenic vasculature demonstrated normal volume without signs of congestion or thrombosis. No sonographic evidence of acute or chronic inflammatory, neoplastic, or infarctual changes were noted.

Liver

The **liver** images submitted revealed subjectively normal liver size, contour, and structure. Parenchymal echogenicity was naturally coarse and hypoechoic to the spleen. Vascular and biliary tracts were of normal volume with no evidence of congestion. The gallbladder presented acceptably thin walls with primarily anechoic content. The cystic and common bile ducts were normal. No pathological hepatic lymphadenopathy was evident. No overt structural evidence of inflammatory, infiltrative or regenerative pathology was evident.

Gastrointestinal



PATIENT

Cletus Eggleston

Examination of the **gastrointestinal tract** revealed a stomach and intestine free of stasis, of normal wall thickness, acceptable curvilinear mural detail, and peristaltic activity. Small and large intestine demonstrated normal luminal chyme and stool consistency respectively. No obstructive or overt infiltrative disease was noted. No associated abnormal lymphatic activity was noted.

SPECIES

Pancreas

Canine

The base and limbs of the **pancreas** were observed to be largely isoechoic to surrounding omental fat. Pancreatic duct and capsular contour were acceptably normal and parenchyma respected normal curvilinear patterns. No overt evidence of active inflammatory or neoplastic disease was noted.

BREED

Bulldog

ULTRASONOGRAPHIC FINDINGS

- Cor pulmonale, largely conformational issue given the breed
- Trivial mitral insufficiency
- Mild tricuspid insufficiency, compensated
- Nodular right adrenal and enlarged left adrenal

SEX

Neutered Male

INTERPRETATION OF THE FINDINGS & FURTHER RECOMMENDATIONS

AGE

8 Years

The right adrenal nodular changes are likely hyperplasia. The left adrenal cystic nodule should be monitored carefully. I'm more concerned about the left adrenal being potentially pathologic. Full adrenal panel (to University of Tennessee) is indicated. The panting is not cardiac related. Tricuspid insufficiency was fairly mild. Blood pressure measurements 20 minutes after Torbutrol injection could be considered to eliminate white coat effect and anxiety. If hypertension is present, then urine catecholamine is indicated to rule out potential pheochromocytoma of the left adrenal. Recheck sonogram in one month. No other evidence of pathology.

WEIGHT

58.96 Pounds

INTERPRETED BY

Eric Lindquist, DMV,
DABVP, Cert. IVUSS

IMAGING PERFORMED BY

Jenna Walsh, CVT

HOSPITAL NAME

Balanced Veterinary
Care

REFERRING VET

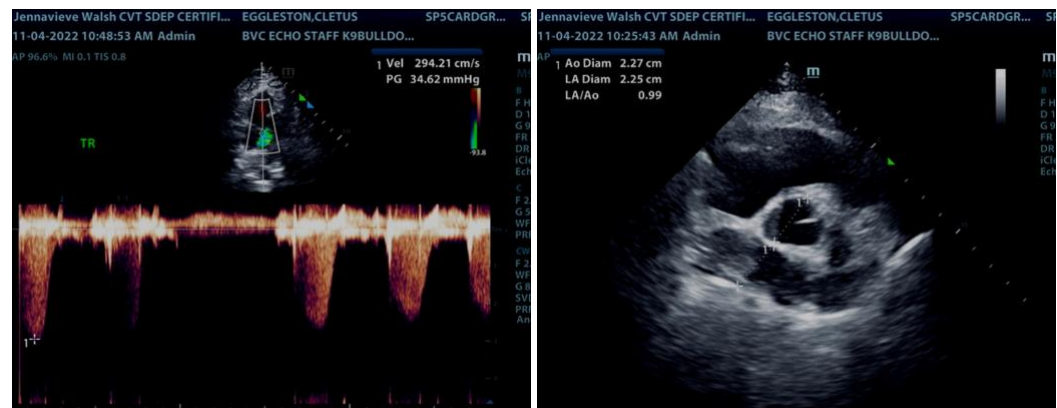
Dr. Wright

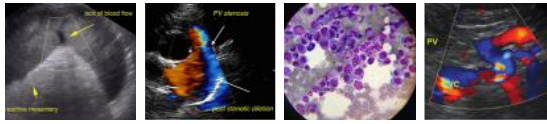
DATE

11/4/22

Invoice

17977





PATIENT

Cletus Eggleston

SPECIES

Canine

BREED

Bulldog

SEX

Neutered Male

AGE

8 Years

WEIGHT

58.96 Pounds

INTERPRETED BY

Eric Lindquist, DMV,
DABVP, Cert. IVUSS

IMAGING PERFORMED BY

Jenna Walsh, CVT

HOSPITAL NAME

Balanced Veterinary
Care

REFERRING VET

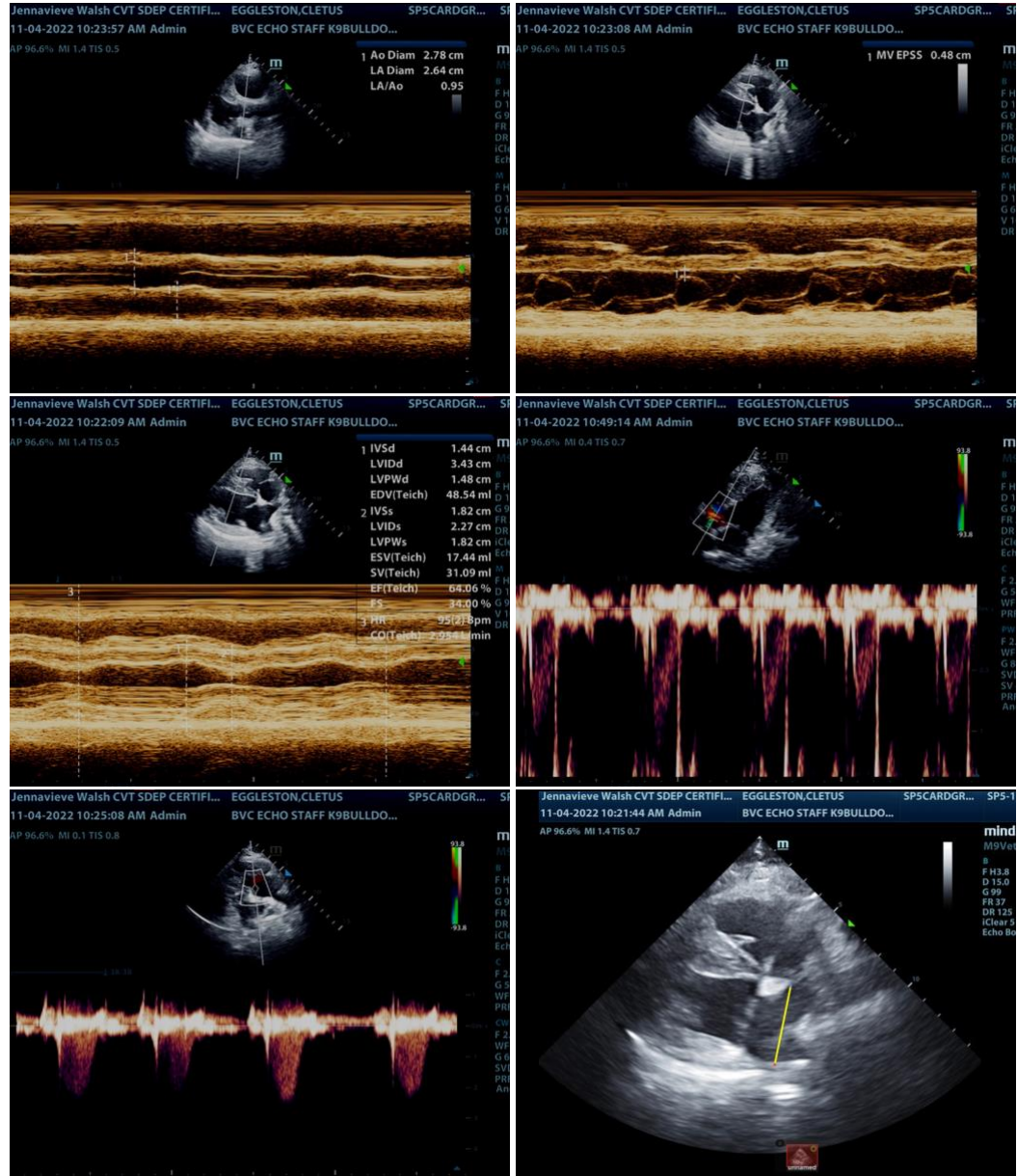
Dr. Wright

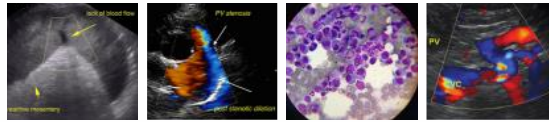
DATE

11/4/22

Invoice

17977





PATIENT

Cletus Eggleston

SPECIES

Canine

BREED

Bulldog

SEX

Neutered Male

AGE

8 Years

WEIGHT

58.96 Pounds

INTERPRETED BY

Eric Lindquist, DMV,
DABVP, Cert. IVUSS

IMAGING PERFORMED BY

Jenna Walsh, CVT

HOSPITAL NAME

Balanced Veterinary
Care

REFERRING VET

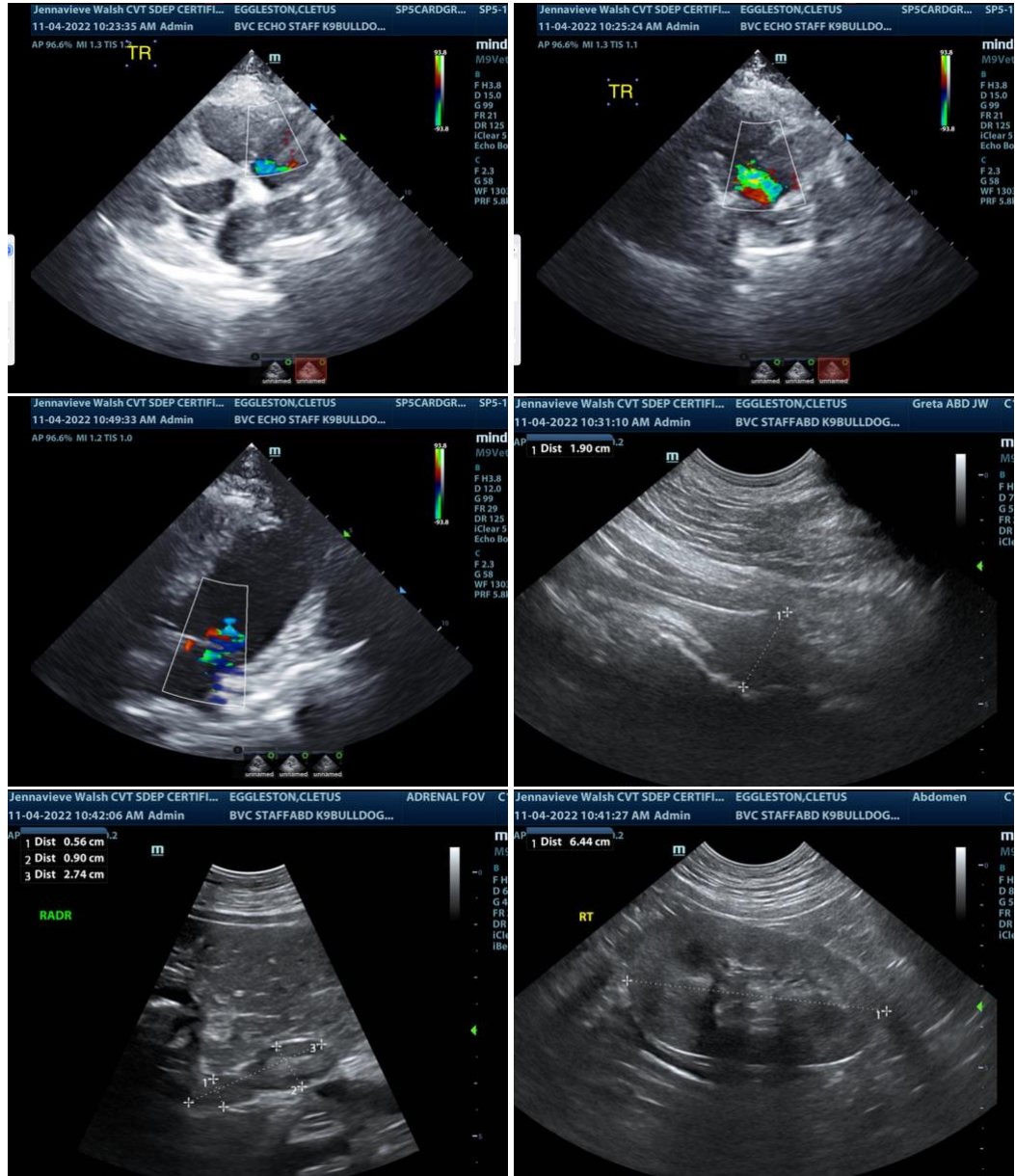
Dr. Wright

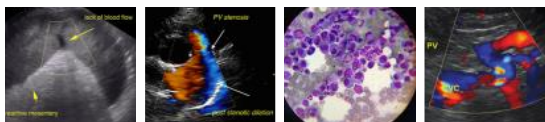
DATE

11/4/22

Invoice

17977





PATIENT

Cletus Eggleston

SPECIES

Canine

BREED

Bulldog

SEX

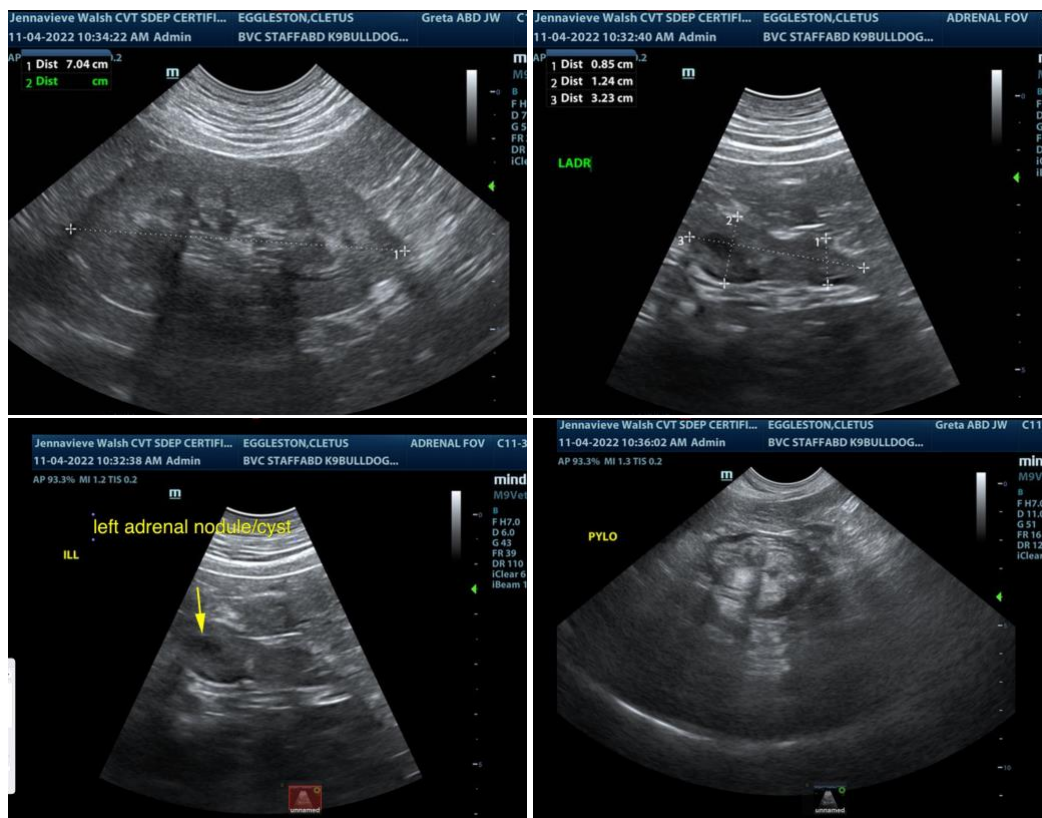
Neutered Male

AGE

8 Years

WEIGHT

58.96 Pounds



The information and recommendations provided are based on the images presented by the referring veterinarian. No evaluation can be communicated regarding pathology that was not visible in the image/video clips provided.

Thank you for this referral. If the clinical or image interpretation does not parallel your findings or if I can be of any further assistance please contact me.

Eric Lindquist, DMV, DABVP, Cert. IVUSS, CEO of SonoPath.com

info@SonoPath.com

INTERPRETED BY

Eric Lindquist, DMV,
DABVP, Cert. IVUSS

IMAGING PERFORMED BY

Jenna Walsh, CVT

HOSPITAL NAME

Balanced Veterinary
Care

REFERRING VET

Dr. Wright

DATE

11/4/22

Invoice

17977