



PATIENT PRESENTING CLINICAL SIGNS

Charlie Young History: New onset of grade 3/6 LAS murmur

SPECIES ULTRASONOGRAPHIC EXAMINATION OF THE HEART

Canine

BREED

Golden Doodle

SEX

Neutered male

AGE

6 years

The echocardiogram in this patient demonstrated normal **left atrial** size based on 3 separate methods of LA evaluation. Minor **mitral** valve insufficiency was noted in this patient with a septally directed jet. The **left ventricle** presented normal thicknesses with linear contour and was not dilated nor restricted. The **myocardium** presented normal echogenicity without subjective evidence of significant fibrotic or ischemic disease. **Contractility** of the ventricular walls was adequate and in normal range for this patient evidenced by the fractional shortening measurement and subjective evaluation of the different regions of the myocardium. The **left ventricular outflow** tract demonstrated normal laminar flow and subjective structural integrity. The **right atrium** and auricle revealed normal size, structure and content. No evidence of masses was noted. Minor **tricuspid** insufficiency was noted at 2.2 m/sec. The **right ventricle** was of normal size (1/3 diameter of LV), chordae structure, myocardial echogenicity and thickness. **Pulmonary outflow** tract assessment revealed normal valve structure, laminar flow, and diameter (approx. 1:1 pa/ao ratio). No visible **pericardial** or free pleura fluid was noted. The cranial **mediastinum and pericardial and extra-cardiac regions** were free of masses in the visible window.

WEIGHT

74 lbs

INTERPRETED BY

Eric Lindquist, DMV
DABVP, Cert. IVUSS

IMAGING PERFORMED BY

Dr. Waffle

HOSPITAL NAME

Torch Lake

| CANINE CARDIAC PARAMETERS | MR VMAX (m/s) | TR VMAX (m/s) | LA/AO (Boon method) | LA/AO (Heart Base; Swe) | FS (%) | EF (%) | EPSS (cm) |
|---------------------------|---------------|---------------|---------------------|-------------------------|-----------------------------------|--|--|
| NORMAL PARAMETER | 4.5-5.5 | <2.7 | 1.3 | <1.6 | 28-40 | 40-100 | <0.6 |
| PATIENT | | 2.2 | 1.15 | 1.0 | 35 | | NM |
| CANINE CARDIAC PARAMETERS | HR (BPM) | AV VMAX (m/s) | PV MAX (m/s) | BODY WEIGHT | LA (2D short axis Base view) (cm) | LVIDd (Avg; 2D and m-mode short axis) (cm) | LVIDs (Avg; 2D and m-mode short axis) (cm) |
| NORMAL PARAMETER | 50-100 | 0.7-1.7 | 0.7-1.6 | BELOW | BELOW | BELOW | BELOW |
| PATIENT | | 1.5 | 0.9 | 74 lbs | | 3.26 | |

REFERRING VET

Dr. Waffle

INVOICE

42340

DATE

11/4/22

ULTRASONOGRAPHIC FINDINGS

Fairly normal echocardiogram with trivial mitral insufficiency and tricuspid insufficiency.

INTERPRETATION OF THE FINDINGS & FURTHER RECOMMENDATIONS

There was no evidence of clinically significant disease.

The heart is stable without clinical disease. No overt contraindication for anesthesia of brief to moderate duration. I suggest Torbutrol premed, Propofol induction, Isoflor maintenance or similar



PATIENT

Charlie Young

protocol if anesthesia is desired. Blood pressure recommended if not already performed and target white coat negative systolic pressure of < 160 mmHg. If higher than this ACE-inhibitor is suggested to reach this level. Recheck echocardiogram is recommended in 6 months, earlier if murmur grade increases or clinical signs initiate.

SPECIES

Canine

BREED

Golden Doodle

SEX

Neutered male

AGE

6 years

WEIGHT

74 lbs

INTERPRETED BY

Eric Lindquist, DMV
DABVP, Cert. IVUSS

IMAGING PERFORMED BY

Dr. Waffle

HOSPITAL NAME

Torch Lake

REFERRING VET

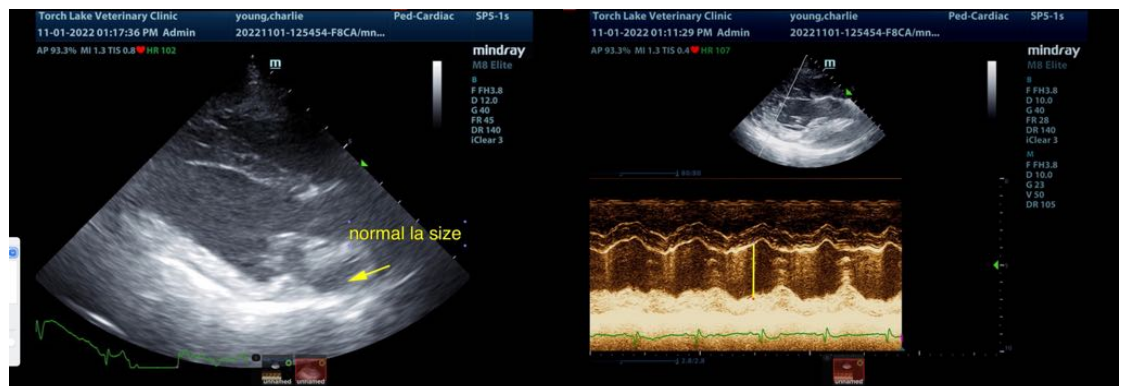
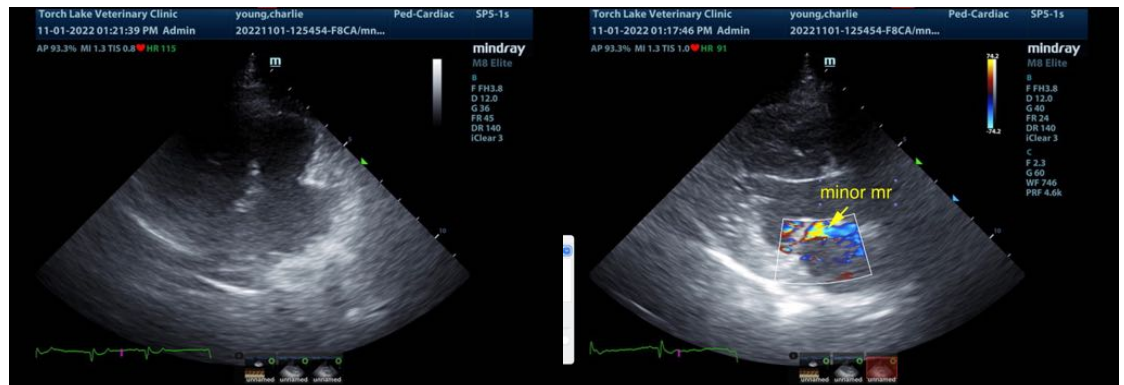
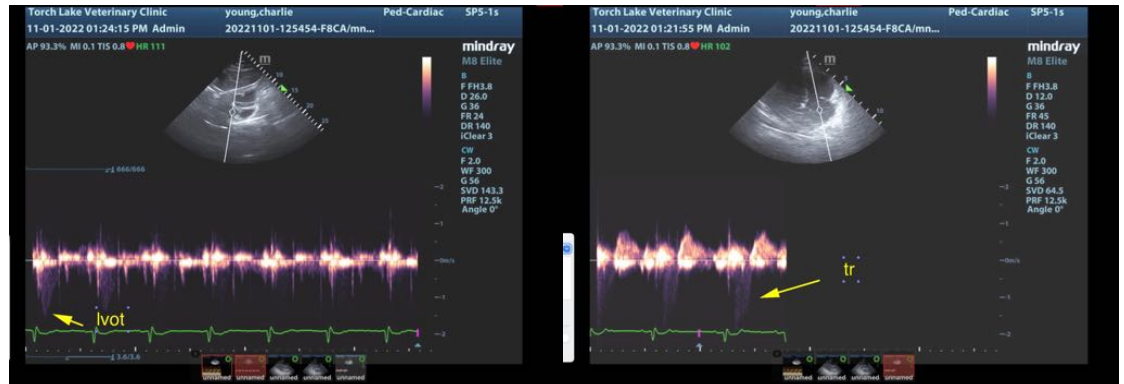
Dr. Waffle

INVOICE

42340

DATE

11/4/22





PATIENT

Charlie Young

SPECIES

Canine

BREED

Golden Doodle

SEX

Neutered male

AGE

6 years

WEIGHT

74 lbs

INTERPRETED BY

Eric Lindquist, DMV
DABVP, Cert. IVUSS

IMAGING PERFORMED BY

Dr. Waffle

HOSPITAL NAME

Torch Lake

REFERRING VET

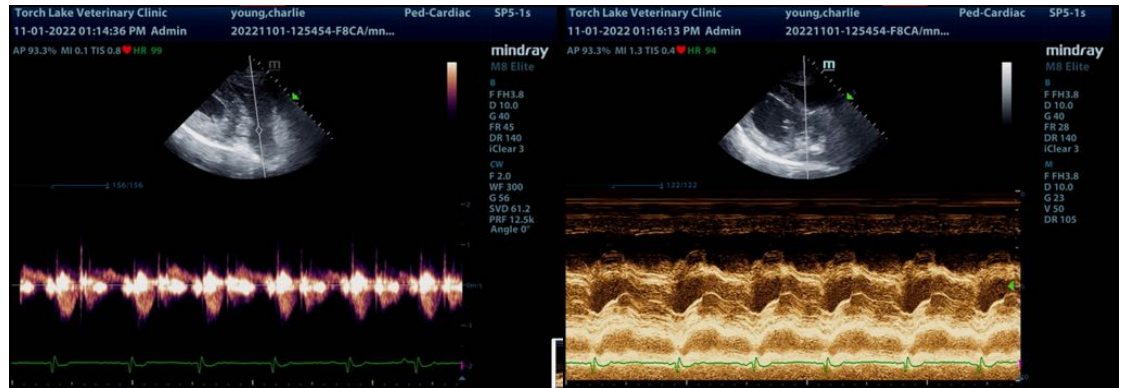
Dr. Waffle

INVOICE

42340

DATE

11/4/22



The information and recommendations provided are based on the images presented by the referring veterinarian/sonographer. No evaluation can be communicated regarding pathology that was not visible in the image/video clips provided.

Thank you for this referral. If the clinical or image interpretation does not parallel your findings or if I can be of any further assistance please contact me.

Eric Lindquist, DMV, DABVP, Cert. IVUSS, CEO of SonoPath.com
info@SonoPath.com