



PATIENT

Prince Johnson

SPECIES

Canine

BREED

Yorkshire Terrier

SEX

Neutered Male

AGE

13 Years

WEIGHT

7.3 kg

INTERPRETED BY

Eric Lindquist, DMV
DABVP, Cert. IVUSS

IMAGING PERFORMED BY

Dr. Callihan

HOSPITAL NAME

Pacific Crest Mobile

REFERRING VET

Dr. Sanders - Skagit AC

INVOICE

33144

DATE

11/30/21

PRESENTING CLINICAL SIGNS

History 3-4 weeks PU/PD and coughing Double cavity ultrasound was performed today and the single hypoechoic splenic nodule (~1.cm irregular, no disruption of capsule) was aspirated and submitted to Sonopath for cytology.

Abnormal PE/Chem/CBC/UA Results: PE unremarkable other than obese, heart murmur 3/6 left apical pmi. Hepatosplenomegaly. Blood pressure is normal. CBC: Normal Chems: -mild elev ALKP, else normal -elev BNP (1404, ref 0-900) UA: Isosthenuria 1.020, quiet sed, no protein, no bacteria Radiographs: (radiologist interpretation) -mineralization in both renal diverticula, numerous cystic calculi -mild right heart and moderate left atrial enlargement -hepatomegaly -normal trachea, no pulmonary edema

ULTRASONOGRAPHIC EXAMINATION OF THE HEART & ABDOMEN

CANINE CARDIAC PARAMETERS	MR VMAX (m/s)	TR VMAX (m/s)	LA/AO (Boon method)	LA/AO (Heart Base; Swe)	FS (%)	EF (%)	EPSS (cm)
NORMAL PARAMETER	4.5-5.5	<2.7	1.3	<1.6	28-40	40-100	<0.6
PATIENT	5.0		1.7	1.4	29	58	0.18
CANINE CARDIAC PARAMETERS	HR (BPM)	AV VMAX (m/s)	PV MAX (m/s)	BODY WEIGHT (kg)	LA 2D short axis Base view (cm)	LVIDd Avg; 2D and m-mode short axis (cm)	LVIDs Avg; 2D and m-mode short axis (cm)
NORMAL PARAMETER	50-100	0.7-1.7	0.7-1.6				
PATIENT		1.48	0.89		1.86	2.81	

Cardiac Presentation

The echocardiogram in this patient demonstrated normal **left atrial** size based on 3 different LA measurement methods. The cranial and caudal **mitral** valve leaflets presented vegetative thickening consistent with endocardiosis. Color flow of the mitral valve revealed moderate filling of the left atrium. The **left ventricle** presented thicknesses with linear contour and was not dilated nor restricted. The **myocardium** presented normal echogenicity without subjective evidence of significant fibrotic or ischemic disease. **Contractility** of the ventricular walls was adequate and in normal range for this patient evidenced by the fractional shortening measurement and subjective evaluation of the different regions of the myocardium. **Aortic** insufficiency noted at 4.5 m/sec. The **right atrium** was slightly enlarged. No evidence of masses was noted or chamber overload. 1:1 right atrial to left atrial ratio present owing to mild right-sided enlargement. Minor **tricuspid** insufficiency noted. The **right ventricle** was of normal size (1/3 diameter of LV), chordae structure, myocardial echogenicity and thickness. **Pulmonic** tract assessment revealed normal valve structure, laminar flow, and diameter (approx.1:1 pa/ao ratio). No visible **pericardial** or free pleura fluid was noted. No echographically detectable evidence of infiltrative disease was visible. The cranial **mediastinum** and **pericardial** regions were free of masses in the visible window.



PATIENT

Urinary System

Prince Johnson

The **urinary bladder**, trigone, and pelvic urethra presented normal thicknesses and normal tone. The ureters were not visible which is normal. A small grouping of non-obstructive cystic calculi was present measuring approximately 1.0 cm. No evidence of inflammatory or neoplastic changes were noted. Ureteral papillae were normal. The pelvic urethra was imaged 2.0 cm beyond the cystourethral junction.

SPECIES

Canine

BREED

Yorkshire Terrier

The **kidneys** revealed largely normal size and structure, corticomedullary definition and ratio (cortex 1/3 of medulla) were essentially maintained with some age-related loss of curvilinear patterns regarding the capsule and C/M junction. The cortices presented largely uniform texture with some increased echogenicity expected for his age patient. Medullary structure differed distinctly from that of the cortex. Mineralization noted in both kidneys. The right kidney measured 4.5 cm. Slight pyelectasia noted in the left kidney at 0.17 cm. The left kidney measured 4.67 cm.

SEX

Adrenal Glands

Neutered Male

Both **adrenal glands** were swollen, yet technically within normal limits for this patient. The right adrenal gland measured 0.62 cm. The left adrenal gland was slightly heterogeneous at 0.6 cm.

AGE

Spleen

13 Years

The **spleen** presented a 1.35 cm hypoechoic, undifferentiated nodule at the mid cranial body.

Liver

WEIGHT

7.3 kg

The **liver** presented heterogenous parenchyma with increased portal markings and coarse architecture. Slight undulating capsular contour was noted. The gallbladder and common bile duct were unremarkable. This is consistent with chronic inflammatory hepatopathy. A heterogeneous, microcystic, nodular hepatic lymph node noted, likely reactive given that length to width ratio was maintained, likely sequelae from chronic lymphadenitis.

INTERPRETED BY

Eric Lindquist, DMV
DABVP, Cert. IVUSS

Gastrointestinal

Examination of the **gastrointestinal tract** revealed a stomach and intestine free of stasis, of normal wall thickness, acceptable curvilinear mural detail, and peristaltic activity. Small and large intestine demonstrated normal luminal chyme and stool consistency respectively. No obstructive or overt infiltrative disease was noted. No associated abnormal lymphatic activity was noted.

IMAGING PERFORMED BY

Dr. Callihan

Pancreas

HOSPITAL NAME

Pacific Crest Mobile

The base and limbs of the **pancreas** were observed to be largely isoechoic to surrounding omental fat. Some parenchymal remodeling, however, with mild deviation from curvilinear normalcy was observed. Pancreatic duct and capsular irregularities were present consistent with age related changes. If pain upon imaging (+ Murphy sign) was present or if the patient is focally painful in subxyphoid palpation then low-grade smoldering chronic pancreatitis should be suspected.

REFERRING VET

Dr. Sanders - Skagit AC

ULTRASONOGRAPHIC FINDINGS

INVOICE

33144

- Stage B1 valvular disease with mild cor pulmonale present
- Nephrolithiasis, non-obstructive at the time of the sonogram
- Splenic nodule - concerning for emerging round cell neoplasia, hemangiosarcoma, pronounced benign hyperplasia possible.
- Small non-obstructive bladder stones

DATE

11/30/21



PATIENT

Prince Johnson

SPECIES

Canine

BREED

Yorkshire Terrier

SEX

Neutered Male

AGE

13 Years

WEIGHT

7.3 kg

INTERPRETATION OF THE FINDINGS & FURTHER RECOMMENDATIONS

The cough is non-cardiogenic at this time. However, decompensation in the future is always a possibility in this patient. Primary respiratory disease warranted given the coughing history.

FNA of the splenic nodule indicated. The patient may be passing calculi periodically. If USG is persistently < 1.020, then emerging PDH is a potential in this patient. Cushing Work UP

Efficient & Accurate Cushing's Work up-Lindquist

Notes regarding Cushing's Clinical Presentations:

Nearly all Cushing's dogs have SAP elevations and true PU/PD (USG < 1.025) and most are polyphagic. Cushing's dogs are > 6 years and usually > 9 years old, usually have poor skin coats, body scores > 3/5, and are usually sedentary animals.

Its important to remember that Cushing's dogs usually look and play the part and other diseases cause false + stress related cortisol spikes. On rare occasion a Cushing's dog will not follow the rules but this is truly an exception.

Potential Cushing's patient workups can be costly and frustrating if not definitive and, in my experience, the non-definitive patient usually has something else going on that may be contributing to some of the clinical signs a Cushing's dog will have, especially SAP elevations or PU/PD. Based on this prelude of information I came up with the following algorithm in the spirit of diagnostic efficiency.

The following suggested protocol is based on current available literature on Cushing's disease and extensive clinical-sonographic experience evaluation + Cushing's and False + LDDST & ACTH stim. cases in order to maximize the efficiency of a Cushing's workup in practice.

Screen first, workup second

INTERPRETED BY

Eric Lindquist, DMV
DABVP, Cert. IVUSS

1) **UA:** Repeatable (2-3 urine samples) Urine specific gravity & urine cortisol/creatinine ratio (UCCR): If **repeatable USG < 10.20 and + UCCR** move to next step 2.

Note: UA is inexpensive and easy to obtain and if UA criteria is not met for Cushing's then resources can be spent into other more pertinent diagnostics or left on hold until the UA criteria is met in emerging Cushing's cases.

IMAGING PERFORMED BY

Dr. Callihan

2) **Sonogram:** Does the patient **have concurrent disease** clinically or sonographically as non-Cushing's illness will influence the potential false + LDDST or even ACTH stim. The sonogram gives a global perspective of the internal health of the patient to be considered in the Cushing's workup as an assessment of concurrent disease. Is there a concurrent neoplastic process, UTI pancreatitis, mucocele....? Are the adrenals enlarged (Cushing's-PDH, stress, age related or breed variant), or atrophied (iatrogenic Cushing's or adrenal burnout), have asymmetric enlargement (Adrenal tumor, hyperplasia, adenoma, age related variant), or is there vascular invasion (Invasive pheo with false + UA criteria or adenocarcinoma or phrenic thrombosis)? The sonogram answers these questions proactively.

HOSPITAL NAME

Pacific Crest Mobile

REFERRING VET

Dr. Sanders - Skagit AC

3) **LDDST** (0.01 D-Sodium phosphate mg/kg IV) (Better screening test but plagued with false +) Use if there is potential early Cushing's or if adrenal asymmetry present on sonogram suspecting tumor. Use LDDST in cats at a higher dose (0.1 mg/kg IV).

INVOICE

33144

OR

4) **ACTH stim.** (Better confirming test but can have false +) Use if the patient "looks" Cushingoid or if bilateral adrenal enlargement is present, or high normal width on sonogram, or if iatrogenic Cushing's suspected (Cortisone Tx in past).

DATE

11/30/21

5) If **diabetic** then run both LDDST & ACTH stim.



PATIENT

Prince Johnson

5) Run a **serial blood pressure** in a BP friendly non “white coat effect” atmosphere. Run at least 3 at different times over a few hours or when eating as the patient tends to be calm when eating or give Torbutrol when entering the facility.

SPECIES

Canine

6) **Perform CT** of the pituitary to identify macro adenoma expansion if any lethargy or dullness or other central clinical CNS signs are minimally present.

BREED

Yorkshire Terrier

Behrend EN, Kooistra HS, Nelson R, et al. Diagnosis of Spontaneous Canine Hyperadrenocorticism: 2012 ACVIM Consensus Statement (Small Animal). J Vet Intern Med 2013;27:1292–1304.

SEX

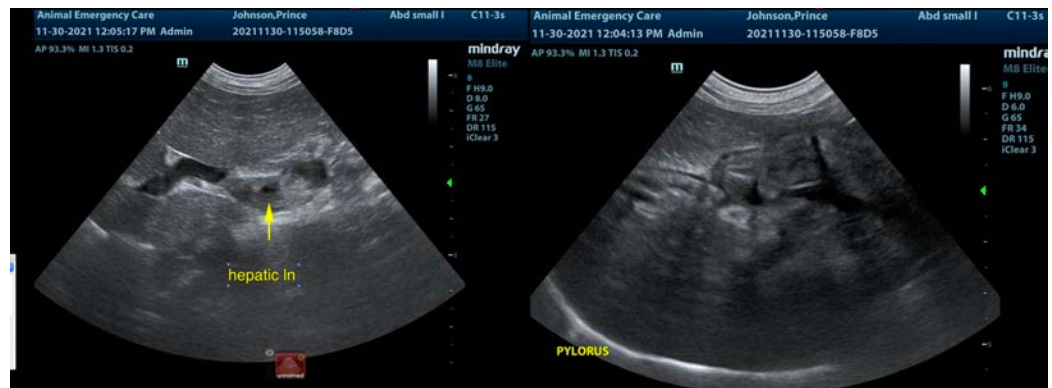
Neutered Male

AGE

13 Years

WEIGHT

7.3 kg

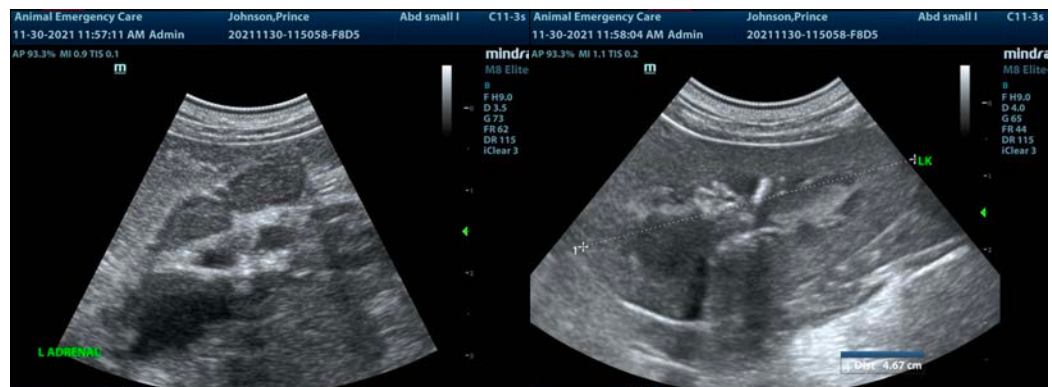


INTERPRETED BY

Eric Lindquist, DMV
DABVP, Cert. IVUSS

IMAGING PERFORMED BY

Dr. Callihan

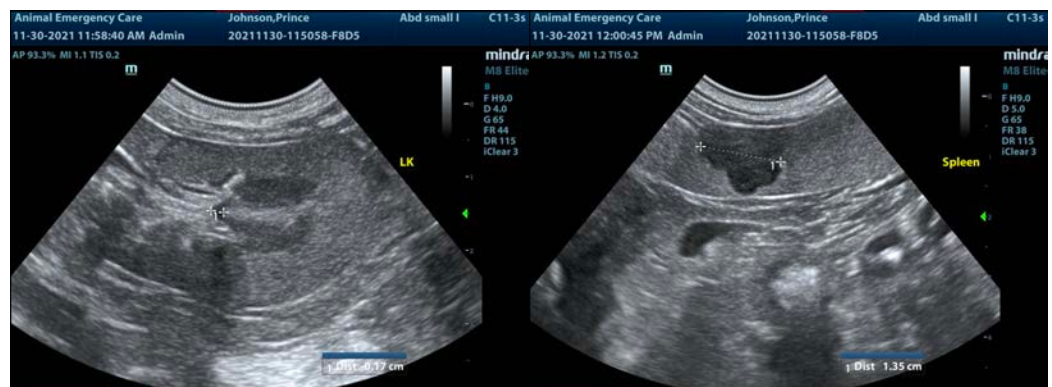


HOSPITAL NAME

Pacific Crest Mobile

REFERRING VET

Dr. Sanders – Skagit AC

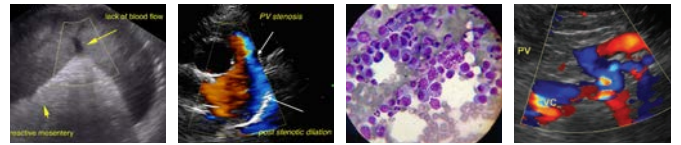


INVOICE

33144

DATE

11/30/21



PATIENT

Prince Johnson

SPECIES

Canine

BREED

Yorkshire Terrier

SEX

Neutered Male

AGE

13 Years

WEIGHT

7.3 kg

INTERPRETED BY

Eric Lindquist, DMV
DABVP, Cert. IVUS

IMAGING PERFORMED BY

Dr. Callihan

HOSPITAL NAME

Pacific Crest Mobile

REFERRING VET

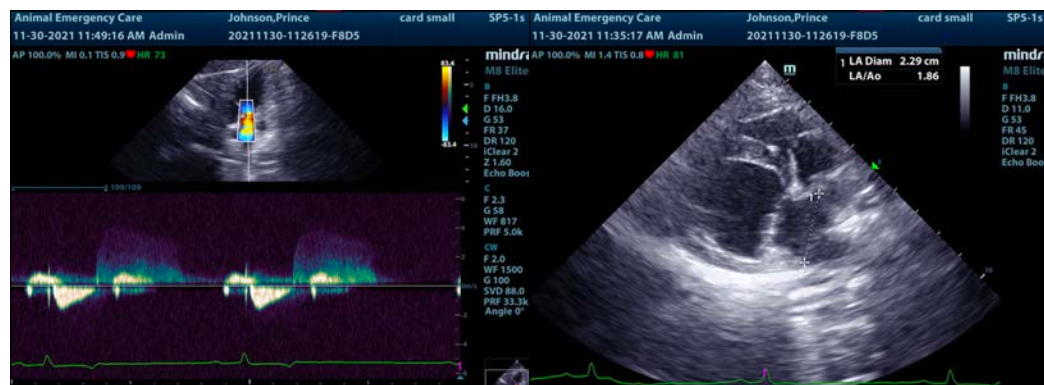
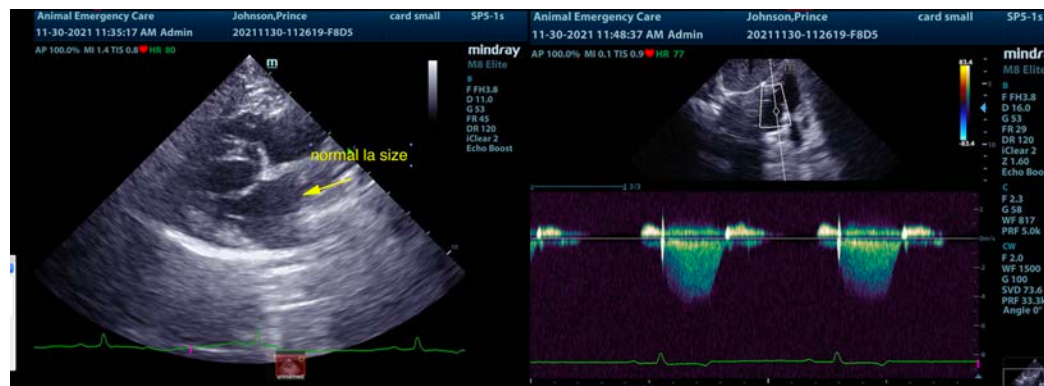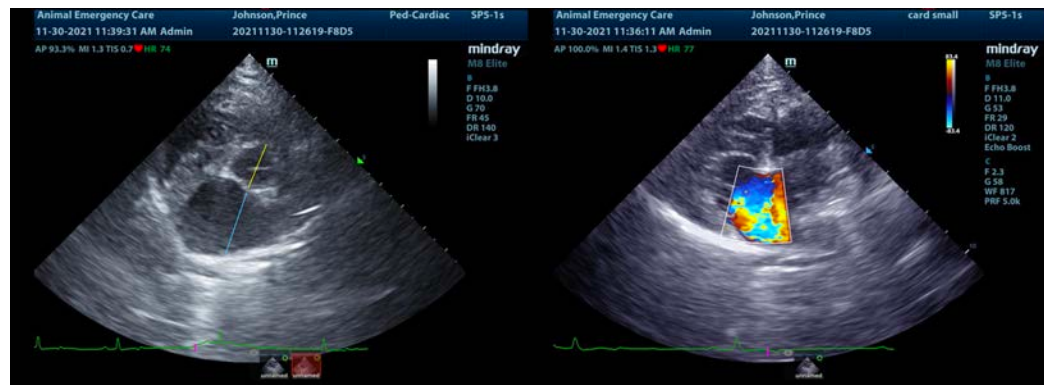
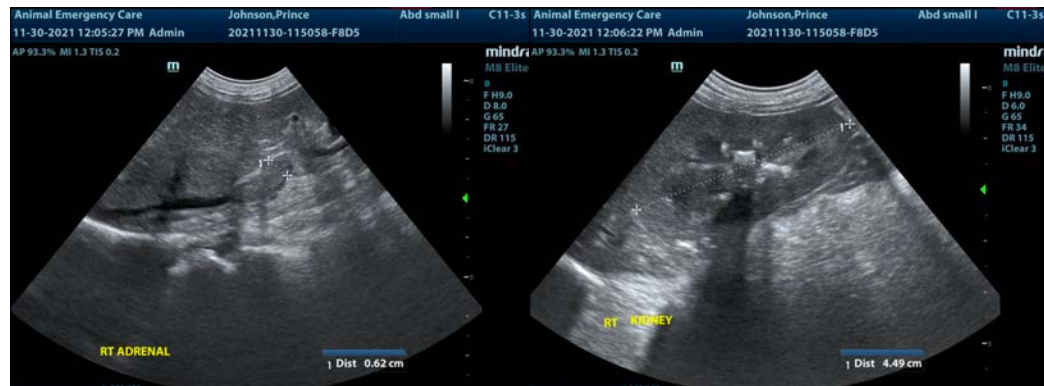
Dr. Sanders - Skagit AC

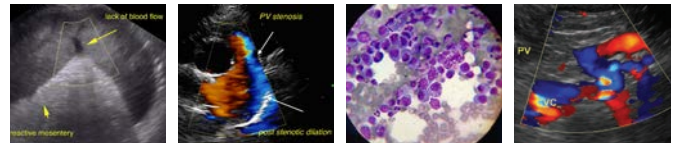
INVOICE

33144

DATE

11/30/21





PATIENT

Prince Johnson

SPECIES

Canine

BREED

Yorkshire Terrier

SEX

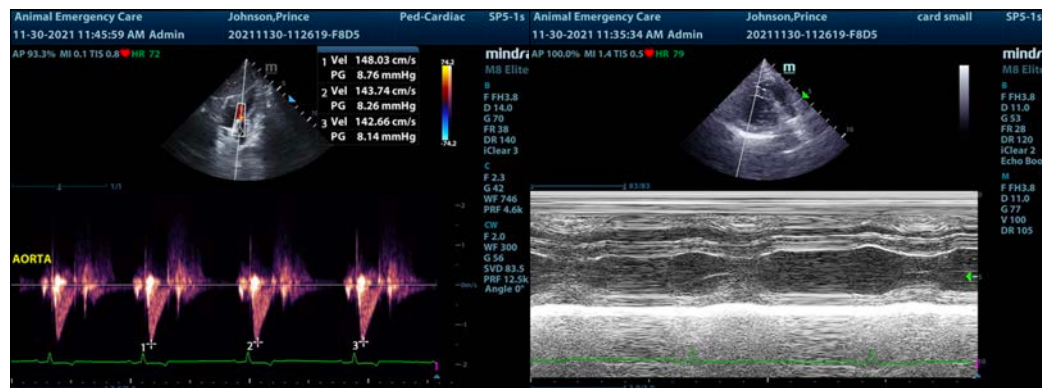
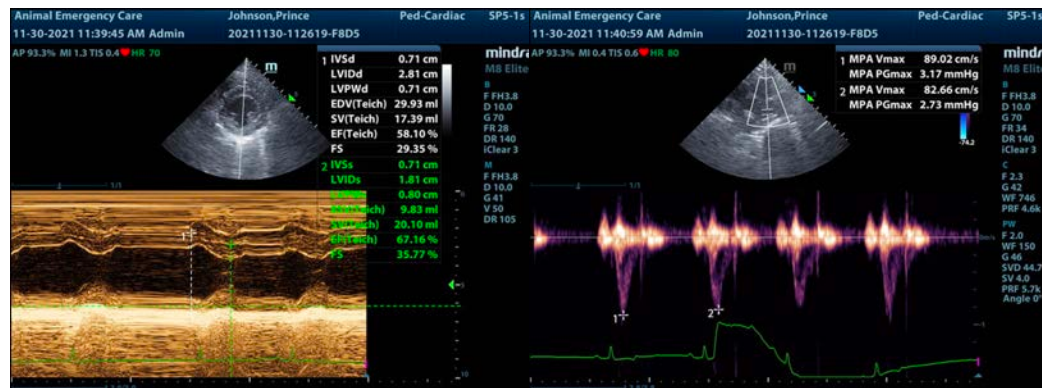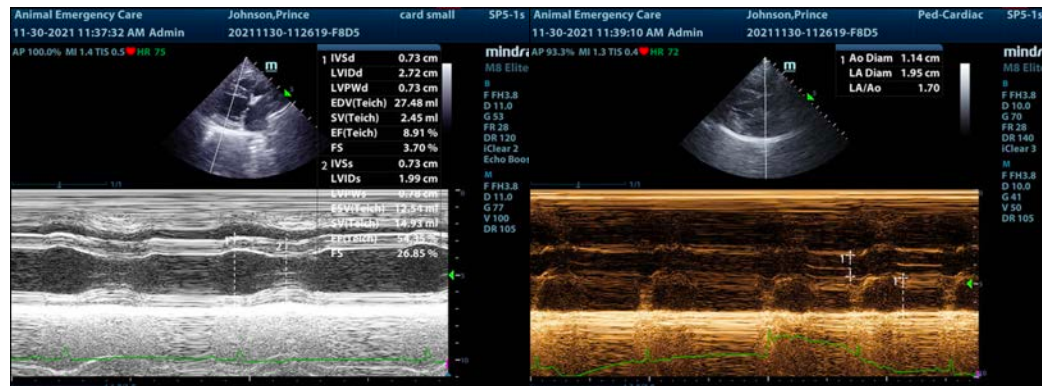
Neutered Male

AGE

13 Years

WEIGHT

7.3 kg



INTERPRETED BY

Eric Lindquist, DMV
DABVP, Cert. IVUSS

IMAGING PERFORMED BY

Dr. Callihan

HOSPITAL NAME

Pacific Crest Mobile

REFERRING VET

Dr. Sanders - Skagit AC

INVOICE

33144

DATE

11/30/21

The information and recommendations provided are based on the images presented by the referring veterinarian. No evaluation can be communicated regarding pathology that was not visible in the image/video clips provided.

Thank you for this referral. If the clinical or image interpretation does not parallel your findings or if I can be of any further assistance please contact me.

Eric Lindquist, DMV, DABVP, Cert. IVUSS, CEO of SonoPath.com
info@SonoPath.com