



PATIENT

Jasper West

SPECIES

Canine

BREED

Walker Hound

SEX

Neutered male

AGE

11 years

WEIGHT

66 lbs

INTERPRETED BY

Eric Lindquist, DMV
DABVP, Cert. IVUSS

IMAGING PERFORMED BY

Dr. Beard

HOSPITAL NAME

West Prince AH

REFERRING VET

Dr. Beard

INVOICE

94174

DATE

11/30/21

PRESENTING CLINICAL SIGNS

History: Mass was removed on his R side, behind shoulder, size of a walnut, subcutaneous and under the muscles, looked like a peach pit. Diagnosis was extramedullary plasma cell tumor. Had angiolymphatic invasion and dirty margins. Therefore, staging for chemotherapy.
Abnormal PE/Chem/CBC/UA Results: CBC/Chemistry/UA all pending. 3 view chest films pending.

ULTRASONOGRAPHIC EXAMINATION OF THE ABDOMEN

Urinary System

The **urinary bladder**, trigone, and pelvic urethra presented normal thicknesses and normal tone. The ureters were not visible which is normal. No uroliths or sediment were visualized and anechoic urine was present. No evidence of inflammatory or neoplastic changes was noted. Ureteral papillae were normal.

The **kidneys** revealed largely normal size and structure, corticomedullary definition and ratio (cortex 1/3 of medulla) were essentially maintained with some age-related loss of curvilinear patterns regarding the capsule and C/M junction. The cortices presented largely uniform texture with some increased echogenicity expected for this age patient. Medullary structure differed distinctly from that of the cortex and no evidence of pelvic dilation was present. The left kidney measured 4.0 cm with a 1.3 cm anechoic cortical cyst. Blood flow to the kidneys appeared to be adequate on color flow assessment.

Adrenal Glands

Both **adrenal glands** were visualized and recognized as having normal shape, size, position and echogenicity for this breed. The phrenic vasculature, glandular echogenicity and detail were unremarkable. Capsule, cortex, and medullary definition were normal for this age patient. The left adrenal gland measured 0.5 cm. The right adrenal gland was visualized obliquely.

Spleen

The **spleen** was largely smooth with subtle heterogeneous parenchymal changes while maintaining normal echogenic relationship to the liver and kidney. These changes are consistent with normal age-related alteration. The capsule was smooth without noticeable impingement from within the spleen or from pathology in the adjacent abdomen. The splenic vasculature demonstrated normal volume without signs of congestion or significant contraction. No evidence of active acute or chronic inflammatory, neoplastic, or infarctual changes was noted.

Liver

The **liver** was uniformly swollen with minor, excessive gallbladder debris and over distension with dependent and suspended bile without evidence of overt mucocele formation. However, excessive sludge was present. Subtle heterogenous parenchymal changes were noted, yet there was no evidence of disruptive disease. The liver presented coarse architecture with mildly increased portal markings and subtle, mixed echogenic changes. This is consistent with vacuolar hepatopathy and some level of remodeling and history of inflammatory component. There was no overt suspicion of neoplasia.



PATIENT

Gastrointestinal

Jasper West

Examination of the **gastrointestinal tract** revealed a stomach and intestine free of stasis, of normal wall thickness, acceptable curvilinear mural detail, and peristaltic activity. Small and large intestine demonstrated normal luminal chyme and stool consistency respectively. No obstructive or overt infiltrative disease was noted. No associated abnormal lymphatic activity was noted.

SPECIES

Canine

BREED

Walker Hound

Pancreas

The base and limbs of the **pancreas** were observed to be largely isoechoic to surrounding omental fat. Pancreatic duct and capsular contour were acceptably normal and parenchyma respected normal curvilinear patterns. No overt evidence of active inflammatory or neoplastic disease was noted.

SEX

Neutered male

ULTRASONOGRAPHIC FINDINGS

Unremarkable abdomen.

AGE

11 years

Left renal cyst.

WEIGHT

66 lbs

INTERPRETATION OF THE FINDINGS & FURTHER RECOMMENDATIONS

The changes are largely age related in this patient. There was no evidence of any significant primary or metastatic disease. Screening FNA of the spleen and liver can be justified given the minor heterogenous changes. However, there is no organ distortion that would suggest infiltrative disease.

INTERPRETED BY

Eric Lindquist, DMV
DABVP, Cert. IVUSS

IMAGING PERFORMED BY

Dr. Beard

HOSPITAL NAME

West Prince AH

REFERRING VET

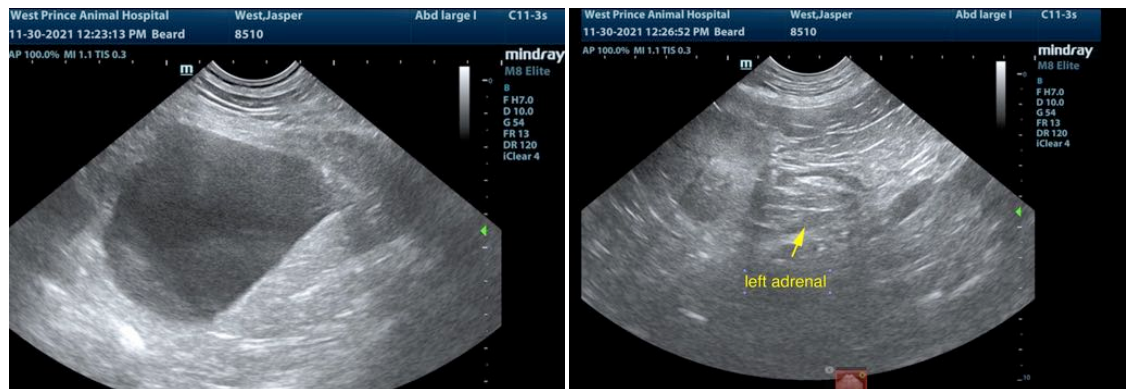
Dr. Beard

INVOICE

94174

DATE

11/30/21





PATIENT

Jasper West

SPECIES

Canine

BREED

Walker Hound

SEX

Neutered male

AGE

11 years

WEIGHT

66 lbs

INTERPRETED BY

Eric Lindquist, DMV
DABVP, Cert. IVUSS

IMAGING PERFORMED BY

Dr. Beard

HOSPITAL NAME

West Prince AH

REFERRING VET

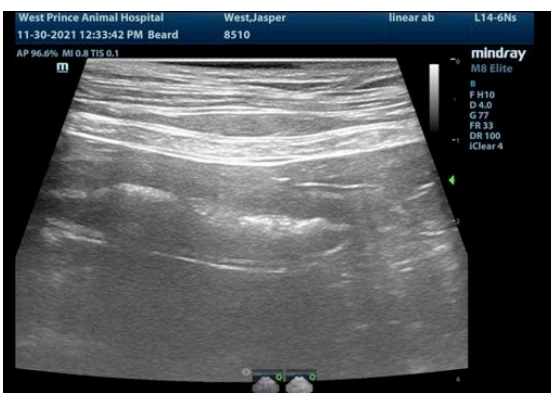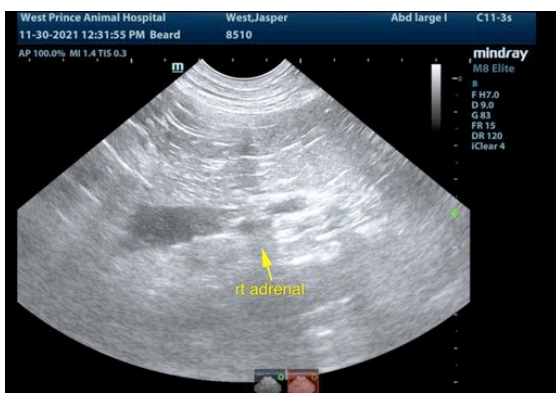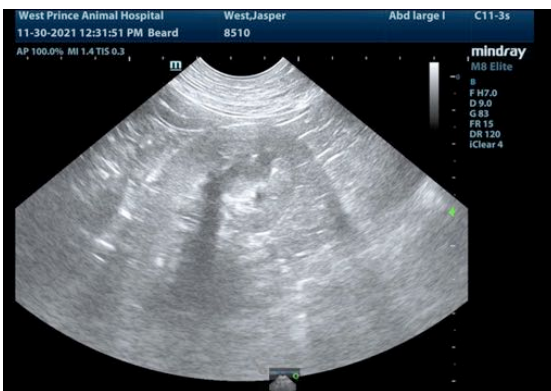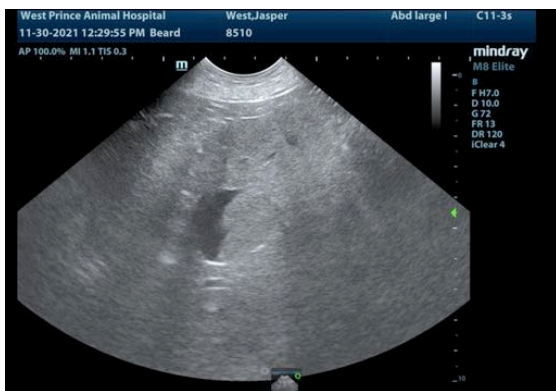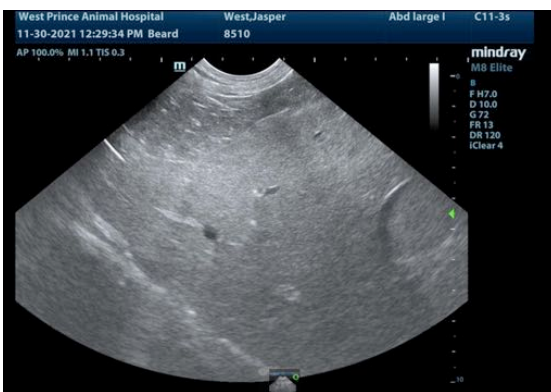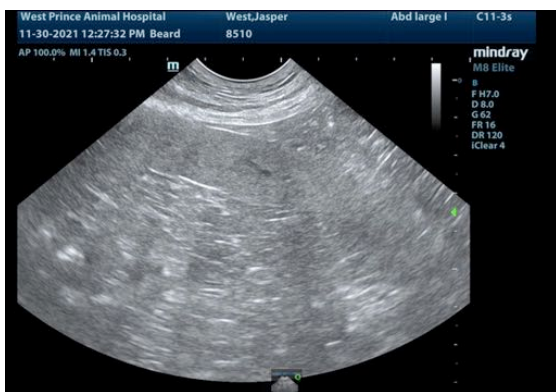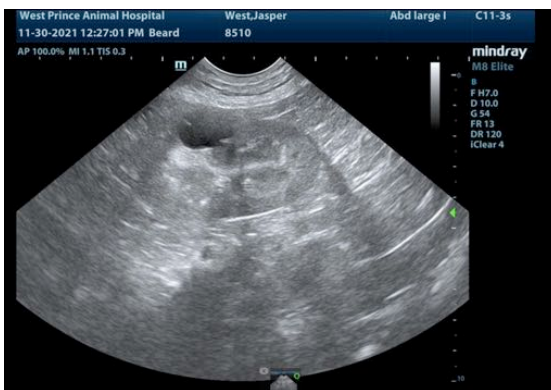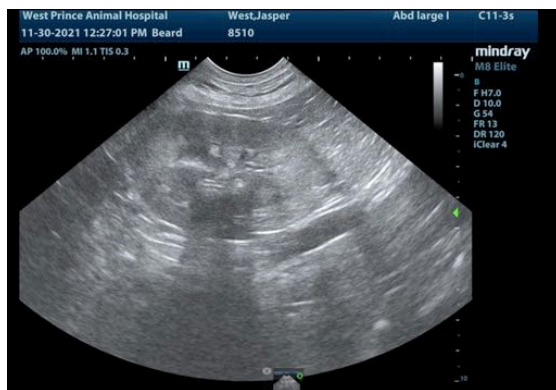Dr. Beard

INVOICE

94174

DATE

11/30/21





PATIENT

Jasper West

SPECIES

Canine

BREED

Walker Hound

SEX

Neutered male

AGE

11 years

WEIGHT

66 lbs

INTERPRETED BY

Eric Lindquist, DMV
DABVP, Cert. IVUSS

**IMAGING
PERFORMED BY**

Dr. Beard

HOSPITAL NAME

West Prince AH

REFERRING VET

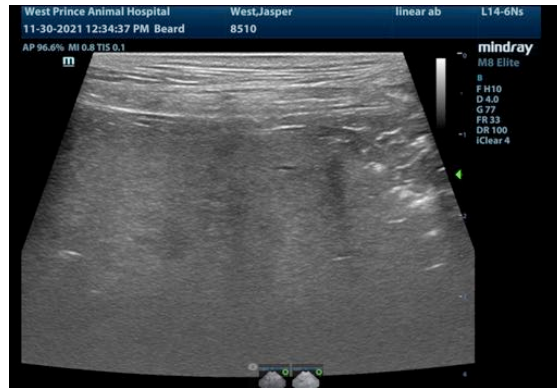Dr. Beard

INVOICE

94174

DATE

11/30/21



The information and recommendations provided are based on the images presented by the referring veterinarian. No evaluation can be communicated regarding pathology that was not visible in the image/video clips provided.

Thank you for this referral. If the clinical or image interpretation does not parallel your findings or if I can be of any further assistance please contact me.

Eric Lindquist, DMV, DABVP, Cert. IVUSS, CEO of SonoPath.com
info@SonoPath.com