



PATIENT

Wagner West

SPECIES

C canine

BREED

Swiss Mountain Dog

SEX

Neutered male

AGE

5 years

WEIGHT

132 lbs

INTERPRETED BY

Eric Lindquist, DMV
DABVP, Cert. IVUSS

IMAGING PERFORMED BY

Laura Klaassen

HOSPITAL NAME

Animal Care Group of
Lake Oswego

REFERRING VET

Dr. Inman

INVOICE

68276

DATE

11/3/25

PRESENTING CLINICAL SIGNS

History: - cancer screen due to breed
Abnormal PE/Chem/CBC/UA Results: - none

ULTRASONOGRAPHIC EXAMINATION OF THE ABDOMEN

Urinary System

The **urinary bladder**, trigone, and pelvic urethra presented normal thicknesses and normal tone. The ureters were not visible which is normal. No uroliths or sediment were visualized and anechoic urine was present. No evidence of inflammatory or neoplastic changes was noted. Ureteral papillae were normal.

The **kidneys** revealed normal size and structure, corticomedullary definition and ratio for this age. The cortices presented largely uniform texture with normal echogenic relationship to liver and spleen. Medullary structure differed distinctly from the cortex and no evidence of pelvic dilation was present. The capsules were acceptably uniform without significant irregularities. The left kidney measured 7.8 cm. The right kidney measured 6.5 cm.

Adrenal Glands

The left **adrenal gland** was not overtly visualized. However, the region of the left adrenal gland appeared unremarkable. The right adrenal gland was visualized and measured approximately 0.6 cm at the caudal pole and 1.0 cm at the cranial pole.

Spleen

The **spleen** presented a smooth homogeneous parenchyma hyperechoic to liver and renal cortical parenchyma. The capsule was smooth without noticeable expansion or deviation from within the spleen or adjacent pathology. The splenic vasculature demonstrated normal volume without signs of congestion or thrombosis. No sonographic evidence of acute or chronic inflammatory, neoplastic, or infarctual changes was noted.

Liver

The **liver** images submitted revealed subjectively normal liver size, contour, and structure. Parenchymal echogenicity was naturally coarse and hypoechoic to the spleen. Vascular and biliary tracts were of normal volume with no evidence of congestion. The gallbladder and common bile duct was unremarkable.



PATIENT

Wagner West

SPECIES

Canine

BREED

Swiss Mountain Dog

SEX

Neutered male

AGE

5 years

WEIGHT

132 lbs

INTERPRETED BY

Eric Lindquist, DMV
DABVP, Cert. IVUSS

IMAGING PERFORMED BY

Laura Klaassen

HOSPITAL NAME

Animal Care Group of
Lake Oswego

REFERRING VET

Dr. Inman

INVOICE

68276

DATE

11/3/25

Gastrointestinal

Examination of the **gastrointestinal tract** revealed a stomach and intestine free of stasis, of normal wall thickness, acceptable curvilinear mural detail, and peristaltic activity. Small and large intestine demonstrated normal luminal chyme and stool consistency respectively. No obstructive or overt infiltrative disease was noted. No associated abnormal lymphatic activity was noted.

Pancreas

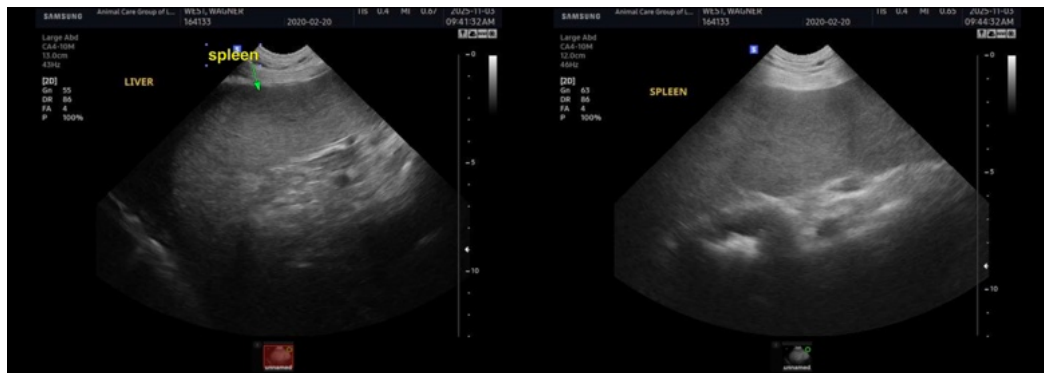
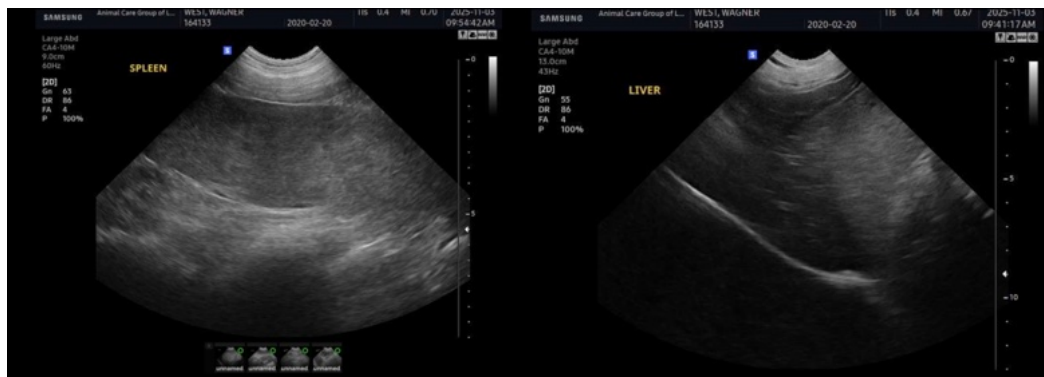The base and limbs of the **pancreas** were observed to be largely isoechoic to surrounding omental fat. Pancreatic duct and capsular contour were acceptably normal and parenchyma respected normal curvilinear patterns. No overt evidence of active inflammatory or neoplastic disease was noted.

ULTRASONOGRAPHIC FINDINGS

- Structurally unremarkable abdomen.

INTERPRETATION OF THE FINDINGS & FURTHER RECOMMENDATIONS

There was no evidence of pathology.





PATIENT

Wagner West

SPECIES

Canine

BREED

Swiss Mountain Dog

SEX

Neutered male

AGE

5 years

WEIGHT

132 lbs

INTERPRETED BY

Eric Lindquist, DMV
DABVP, Cert. IVUSS

IMAGING PERFORMED BY

Laura Klaassen

HOSPITAL NAME

Animal Care Group of
Lake Oswego

REFERRING VET

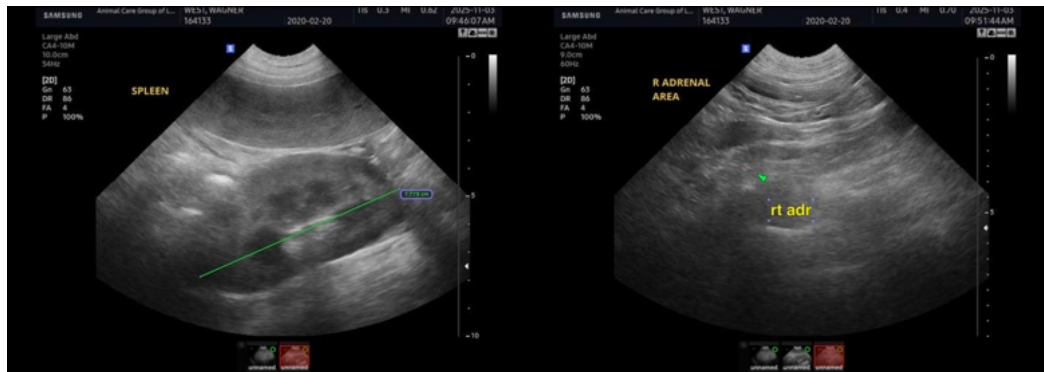
Dr. Inman

INVOICE

68276

DATE

11/3/25



The information and recommendations provided are based on the images presented by the referring veterinarian/sonographer. No evaluation can be communicated regarding pathology that was not visible in the image/video clips provided.

Thank you for this referral. If the clinical or image interpretation does not parallel your findings or if I can be of any further assistance please contact me.

Eric Lindquist, DMV, DABVP (CFM), Cert. IVUSS, CEO of SonoPath.com

info@SonoPath.com