



PATIENT

Starbuck Appel

SPECIES

Canine

BREED

Dachshund

SEX

Neutered male

AGE

16 years

WEIGHT

5.55 kg

INTERPRETED BY

Eric Lindquist, DMV
DABVP, Cert. IVUSS

IMAGING PERFORMED BY

Dr. Carver

HOSPITAL NAME

Animal Emergency
Hospital Volusia

REFERRING VET

Dr. Carver

INVOICE

68257

DATE

11/3/25

PRESENTING CLINICAL SIGNS

History: Patient presented for urinating blood. He was diagnosed with pancreatitis on Thursday at rDVM after going for ADR, decreased appetite (not interested in his normal diet of Fresh Pet, but is eating hamburger, decreased amount.) AUS and bloodwork at rDVM indicated pancreatitis per O. He was started on medications. O went back Friday as he was straining to urinate on Thursday overnight and very uncomfortable. He was diagnosed with a UTI on Friday, and is now urinating blood. O has had a hard time medicating him and does not feel he has really gotten any/ much medications down. Previous history of a splenectomy. Heart murmur 5/6 P last ate at 5 AM - o approved AUS after p ate.

ULTRASONOGRAPHIC EXAMINATION OF THE ABDOMEN

Urinary System

The **urinary bladder** revealed polypoid changes and a cystourethral junction mass. The cystourethral junction mass measured 1.0 cm x 2.0-4.0 cm in depth and is non-resectable. Secondary polypoid change at the dorsal wall of the cystourethral junction measured approximately 0.5 cm. This is strongly mineralizing and consistent with urothelial carcinoma. The mineralizing mass entered into the prostatic urethra and occupied the prostate measuring 3.3 cm. This may be the origin of the mass given the strong mineralization in the prostate.

The **kidneys** revealed largely normal size and structure, corticomedullary definition and ratio (cortex 1/3 of medulla) were essentially maintained with some age-related loss of curvilinear patterns regarding the capsule and C/M junction. The cortices presented largely uniform texture with some increased echogenicity expected for this age patient. Medullary structure differed distinctly from that of the cortex and no evidence of pelvic dilation was present. The left and right kidney measured 4.2 cm.

Adrenal Glands

The **adrenal glands** appeared slightly enlarged and swollen. No evidence of focal capsular expansion or invasion into the phrenic veins was noted. No overt suspicion of neoplasia was noted. This is considered likely a hyperplastic change associated with stress or adrenal endocrinopathy (PDH). If isosthenuria is persistently present and the patient morphologically suggests Cushing's disease then ACTH testing would be indicated. The left adrenal gland measured 0.8 cm. The right adrenal gland measured 1.3 cm at the cranial pole and 1.0 cm at the caudal pole. Slight phrenic vein occupation was noted on the right adrenal gland. This is consistent with thrombus or potential emerging neoplastic event.

Spleen

The **spleen** presented a smooth homogeneous parenchyma hyperechoic to liver and renal cortical parenchyma. The capsule was smooth without noticeable expansion or deviation from within the spleen or adjacent pathology. The splenic vasculature demonstrated normal volume without signs of congestion or thrombosis. No sonographic evidence of acute or chronic inflammatory, neoplastic, or infarctual changes was noted.



PATIENT

Starbuck Appel

SPECIES

Canine

BREED

Dachshund

SEX

Neutered male

AGE

16 years

WEIGHT

5.55 kg

INTERPRETED BY

Eric Lindquist, DMV
DABVP, Cert. IVUSS

IMAGING PERFORMED BY

Dr. Carver

HOSPITAL NAME

Animal Emergency
Hospital Volusia

REFERRING VET

Dr. Carver

INVOICE

68257

DATE

11/3/25

Liver

The **liver** revealed increased portal markings and coarse architecture. The gallbladder presented acceptably thin walls with primarily anechoic content. The cystic and common bile ducts were normal. No pathological hepatic lymphadenopathy was evident. No overt structural evidence of inflammatory, infiltrative or regenerative pathology was evident.

Gastrointestinal

The **stomach** presented mild hypertrophy without loss of mural detail. There was retention of ingesta present. The small intestines and colon were unremarkable with normal curvilinear mural patterns and content.

Pancreas

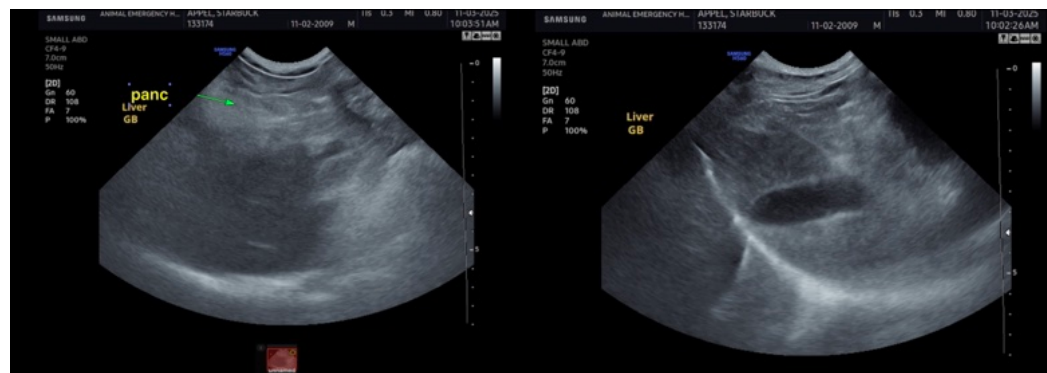
The **pancreas** revealed hyperechoic parenchymal changes. This is consistent with remodeling.

ULTRASONOGRAPHIC FINDINGS

- Prostatic and urethral bladder mass.
- Bilateral adrenal hypertrophy, potential concurrent PDH. Phrenic vein occupation of the right adrenal gland. Right adrenal thrombosis versus emerging carcinoma.
- Otherwise, geriatric abdomen.

INTERPRETATION OF THE FINDINGS & FURTHER RECOMMENDATIONS

Referral for oncological intervention is recommended.





PATIENT

Starbuck Appel

SPECIES

Canine

BREED

Dachshund

SEX

Neutered male

AGE

16 years

WEIGHT

5.55 kg

INTERPRETED BY

Eric Lindquist, DMV
DABVP, Cert. IVUSS

IMAGING PERFORMED BY

Dr. Carver

HOSPITAL NAME

Animal Emergency
Hospital Volusia

REFERRING VET

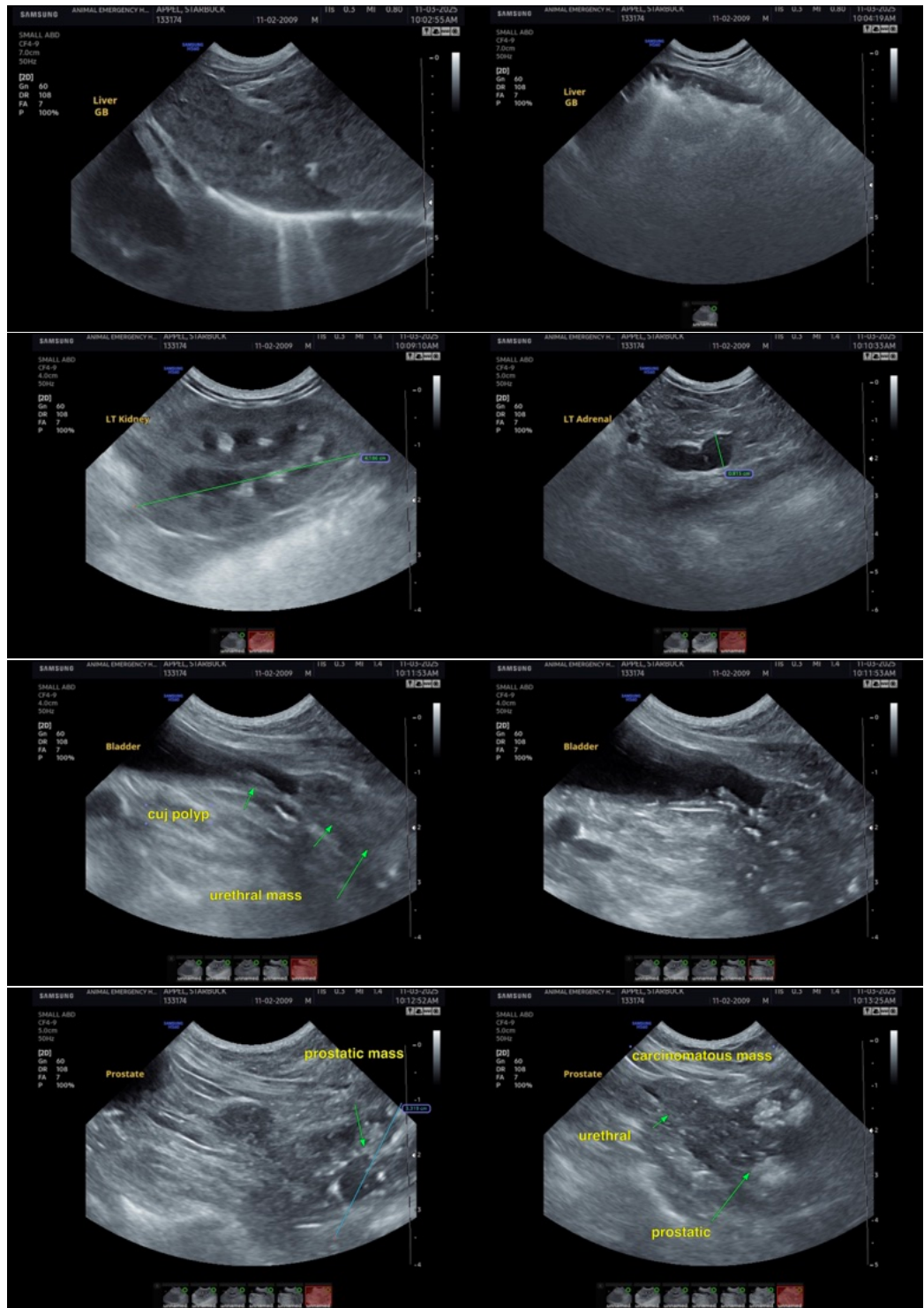
Dr. Carver

INVOICE

68257

DATE

11/3/25





PATIENT

Starbuck Appel

SPECIES

Canine

BREED

Dachshund

SEX

Neutered male

AGE

16 years

WEIGHT

5.55 kg

INTERPRETED BY

Eric Lindquist, DMV
DABVP, Cert. IVUSS

IMAGING PERFORMED BY

Dr. Carver

HOSPITAL NAME

Animal Emergency
Hospital Volusia

REFERRING VET

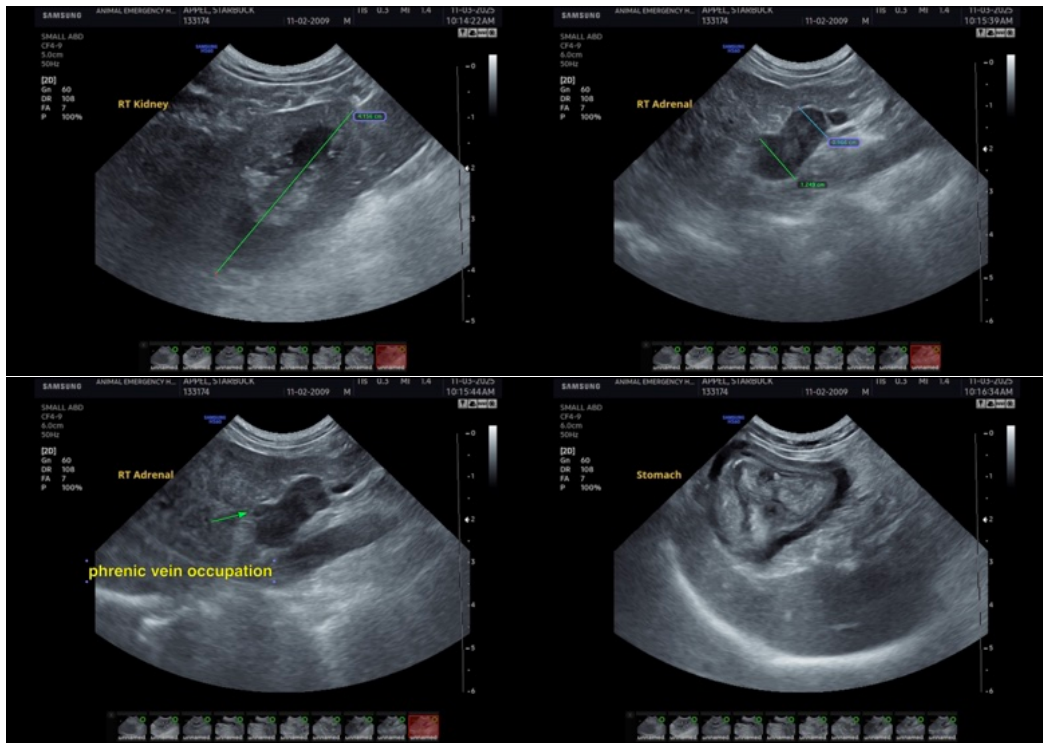
Dr. Carver

INVOICE

68257

DATE

11/3/25



The information and recommendations provided are based on the images presented by the referring veterinarian/sonographer. No evaluation can be communicated regarding pathology that was not visible in the image/video clips provided.

Thank you for this referral. If the clinical or image interpretation does not parallel your findings or if I can be of any further assistance please contact me.

Eric Lindquist, DMV, DABVP (CFM), Cert. IVUSS, CEO of SonoPath.com

info@SonoPath.com

Canine Prostatic Neoplasia

<http://www.sonopath.com/ProstaticCarcinoma>

Description: Prostatic neoplasia is frequently seen in dogs and can be diagnosed via ultrasonographic examination. The most commonly diagnosed prostatic neoplasms are adenocarcinoma and undifferentiated carcinoma. Transitional cell carcinoma (TCC) frequently spreads from the urinary bladder and urethra to the prostatic tissue (see the “Transitional Cell Carcinoma” chapter for more details). Metastatic squamous cell carcinoma, lymphoma, hemangiosarcoma, and leiomyosarcoma have been reported, but are less prevalent. Prostatic neoplasia has been documented in cats, but is quite rare.

Clinical Signs: Prostatic neoplasia presents in both neutered and intact males; however, a 2002 study suggested that neutered males were at greater risk for developing prostatic neoplasia than



PATIENT

Starbuck Appel

SPECIES

Canine

BREED

Dachshund

SEX

Neutered male

AGE

16 years

WEIGHT

5.55 kg

INTERPRETED BY

Eric Lindquist, DMV
DABVP, Cert. IVUSS

IMAGING PERFORMED BY

Dr. Carver

HOSPITAL NAME

Animal Emergency
Hospital Volusia

REFERRING VET

Dr. Carver

INVOICE

68257

DATE

11/3/25

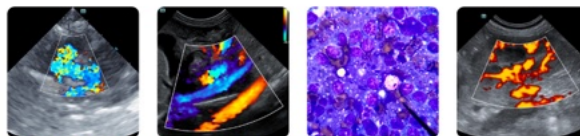
intact males. Typically, prostatic neoplasia is seen in older dogs (mean age of 10 years). Breed predilection includes mixed breed dogs, Shetland Sheepdogs, Dobermans, Scottish Terriers, and Airedale Terriers. Clinical signs and commonly reported signs from owners typically include: stranguria, frequent urinations, hematuria, dyschezia, weight loss, and decreased appetite. Other findings upon physical examination include fever, ataxia, pain upon rectal examination, and pain upon spinal palpation.

Diagnostics: Ultrasonographic examination should be performed if prostatic neoplasia is suspected. Common ultrasonographic findings include an enlarged, irregular prostate that typically has a hypoechoic appearance. Multifocal, poorly coalescing hyperechoic foci are also seen in prostatic malignancies. Hyperechoic foci are due to mineralization of the prostate; they cause far field shadowing. Cystic components can also be observed and are thought to indicate abscessation and/or necrosis. It can be difficult to differentiate chronic bacterial prostatitis from a prostatic neoplasia; however, regional lymphadenopathy is much more common with prostatic neoplasia than it is with chronic bacterial prostatitis. Malignancies of the prostate have often metastasized by the time of diagnosis. Frequent sites of metastases include the sublumbar lymph nodes, the pelvis, lumbar vertebrae, and the lungs. If metastases to the pelvis or lumbar vertebrae have occurred, bony lysis will often be noted radiographically. Metastasis to the liver, brain, kidney and spleen may occur. A definitive diagnosis of a prostatic neoplasm can be achieved through biopsy as well as fine needle aspiration (FNA) or through ultrasound-guided traumatic catheterization.

A complete and thorough workup includes a CBC, biochemical profile, urinalysis, as well as three radiographic views of the thorax, an abdominal ultrasound, and an ultrasound-guided prostatic biopsy or FNA, if indicated. Urinalysis may reveal hematuria and pyuria. Prostatic fluid analysis can also be helpful in identifying neoplastic cells.

Treatment: Unfortunately, once diagnosed, prostatic carcinoma offers a poor prognosis; prostatectomy, chemotherapy, and radiation therapy have proven unsuccessful in improving quality or length of life. Nonsteroidal anti-inflammatory drugs (NSAIDs), such as deracoxib, meloxicam, and piroxicam, have been used for their palliative, anti-neoplastic properties with prostatic carcinomas. Certain tumors, including various carcinomas (e.g. TCC, prostatic carcinoma, mammary carcinoma, squamous cell carcinoma) overexpress COX-2, which converts arachidonic acid to prostaglandin G₂ (PGG₂)/prostaglandin H₂ (PGH₂), and ultimately to prostaglandin E₂ (PGE₂). The metabolite, PGE₂, is associated with increased inflammation, tumor invasiveness, angiogenesis, and reduced apoptosis. In vivo and in vitro, NSAIDs inhibit COX-2, resulting in the suppression of PGE₂, and thereby inhibiting tumor growth and metastasis. This effect has been achieved with both non-selective COX inhibitors as well as COX-2 inhibitors (the latter will suppress COX-1 at increased doses).

Some cases of prostatic carcinoma are managed palliatively with cyst/abscess ultrasound-guided drainage, antibiotic infusion, systemic antibiotics, and NSAID treatment and/or chemotherapy. Anecdotally, it has been observed that patients that often present clinical signs of hematuria or



PATIENT

Starbuck Appel

SPECIES

Canine

BREED

Dachshund

SEX

Neutered male

AGE

16 years

WEIGHT

5.55 kg

INTERPRETED BY

Eric Lindquist, DMV
DABVP, Cert. IVUSS

IMAGING PERFORMED BY

Dr. Carver

HOSPITAL NAME

Animal Emergency
Hospital Volusia

REFERRING VET

Dr. Carver

INVOICE

68257

DATE

11/3/25

dysuria owing to cyst or abscess formation may be treated with repeat ultrasound-guided drainage. This appears to work especially well if there is a considerable cystic component to the prostatic tumor. The key is to image the prostate adequately, drain any cysts that are present, sample the abnormal parenchyma (FNA or biopsy), and potentially infuse antibiotics directly into the cystic cavities if a suppurative fluid is retrieved. The patient should be monitored clinically over time and reevaluated to see if cysts recur. Every case responds differently to treatment, and the behavior of parenchymal and cystic growth will vary.

Currently, investigational studies involving fluoroscopic-guided direct chemotherapeutic embolization through the iliac arteries as well as urethral stent placement are offered by select tertiary veterinary facilities that have an interventional radiology department. Ultrasound-guided endoscopic diode laser ablation through a perineal urethrostomy is also being attempted as a salvage and palliative procedure.

Conclusion: Prostatic neoplasia is more commonly detected in neutered male dogs than intact males. Diagnosis is typically obtained using ultrasound, cytology, and histopathology. Unfortunately, traditional therapy typically yields a guarded to poor long-term prognosis, but palliation with NSAIDs and/or chemotherapy can temporarily improve clinical signs. Investigational techniques may provide additional therapeutic options but are currently experimental.

References:

Cerf DJ, Lindquist EC. Palliative ultrasound-guided endoscopic laser ablation of transitional cell carcinomas of the lower urinary tract in dogs. *J Am Vet Med Assoc* 2012;240(1):51-60.

Culp, WTN. Interventional oncology and the management of urinary tract cancer. Proceedings from the American College of Veterinary Internal Medicine, New Orleans, LA, May 30-June 2, 2012.

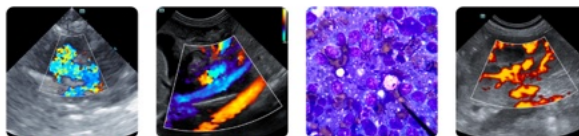
Francey T. Prostatic Diseases. In: Ettinger SJ, Feldman EC, eds. *Textbook of Veterinary Internal Medicine 7th ed.* Philadelphia, PA: WB Saunders; 2010:2047-58.

Hecht S. Male Reproductive Tract. In: Pennick D, D'Anjou MA, eds. *Atlas of Small Animal Ultrasonography.* Ames, IA: Blackwell Publishing; 2008:417-43.

Milner RJ. Do NSAIDs make a difference in cancer. Proceedings from the American College of Veterinary Internal Medicine, Denver, CO, June 15-18, 2011.

Mohammed SI, Khan KN, Sellers RS, et al. Expression of cyclooxygenase-1 and 2 in naturally-occurring canine cancer. *Prostag Leukotr Ess* 2004;70(5):479-83.

Nyland, TG, Mattoon JS. *Small Animal Diagnostic Ultrasound 2nd ed.* Philadelphia, PA: WB Saunders; 2002:250-66.



PATIENT

Starbuck Appel

SPECIES

Canine

BREED

Dachshund

SEX

Neutered male

AGE

16 years

WEIGHT

5.55 kg

INTERPRETED BY

Eric Lindquist, DMV
DABVP, Cert. IVUSS

IMAGING PERFORMED BY

Dr. Carver

HOSPITAL NAME

Animal Emergency
Hospital Volusia

REFERRING VET

Dr. Carver

INVOICE

68257

DATE

11/3/25

Sorenmo KU, Goldschmidt MH, Shofer FS, et al. Evaluation of cyclooxygenase-1 and cyclooxygenase-2 expression and the effect of cyclooxygenase inhibitors in canine prostatic carcinoma. *Vet Comp Oncol* 2004;2(1):13-23.