



PATIENT

Pippin Sagmoen

SPECIES

Canine

BREED

Miniature Schnauzer

SEX

Neutered male

AGE

11 years

WEIGHT

8.2 kg

INTERPRETED BY

Eric Lindquist, DMV
DABVP, Cert. IVUSS

IMAGING PERFORMED BY

Kaitlyn Varga

HOSPITAL NAME

Shuswap VC

REFERRING VET

Dr. Horsley

INVOICE

68280

DATE

11/3/25

PRESENTING CLINICAL SIGNS

History: re-check 6 months since last ultrasound diagnosed stage B1 mitral valve disease. No clinical change/ progression.

Abnormal PE/Chem/CBC/UA Results: Grade 3/6 systolic murmur PMI left apex.

ULTRASONOGRAPHIC EXAMINATION OF THE HEART

The echocardiogram in this patient presented normal volume in all four chambers. Contractility was adequate. Trivial turbulence was noted on the mitral valve. There was no pericardial or pleural effusion. Doppler assessment did not allow for velocities or degree of insufficiency. However, there was no evidence of volume overload or pressure overload in this patient.

CANINE CARDIAC PARAMETERS	MR VMAX (m/s)	TR VMAX (m/s)	LA/AO	LA/AO (Heart Base)	FS (%)	EF (%)	EPSS (cm)
NORMAL PARAMETER	4.5-5.5	<2.7	1.3	<1.6	28-40	40-100	<0.6
PATIENT			1.1	1.4	39	59	0.1
CANINE CARDIAC PARAMETERS	HR (BPM)	AV VMAX (m/s)	PV MAX (m/s)	BODY WEIGHT (kg)	LA 2D short axis Base view (cm)	LVIDd Avg; 2D and m-mode short axis (cm)	LVIDs Avg; 2D and m-mode short axis (cm)
NORMAL PARAMETER	50-100	0.7-1.7	0.7-1.6	BELOW	BELOW	BELOW	BELOW
PATIENT			1.0	8.2 kg	2.04	2.73	

ULTRASONOGRAPHIC FINDINGS

- Stable valvular disease.

INTERPRETATION OF THE FINDINGS & FURTHER RECOMMENDATIONS

I recommend a recheck in 6 months or earlier if murmur grade increases.



PATIENT

Pippin Sagmoen

SPECIES

Canine

BREED

Miniature Schnauzer

SEX

Neutered male

AGE

11 years

WEIGHT

8.2 kg

INTERPRETED BY

Eric Lindquist, DMV
DABVP, Cert. IVUSS

IMAGING PERFORMED BY

Kaitlyn Varga

HOSPITAL NAME

Shuswap VC

REFERRING VET

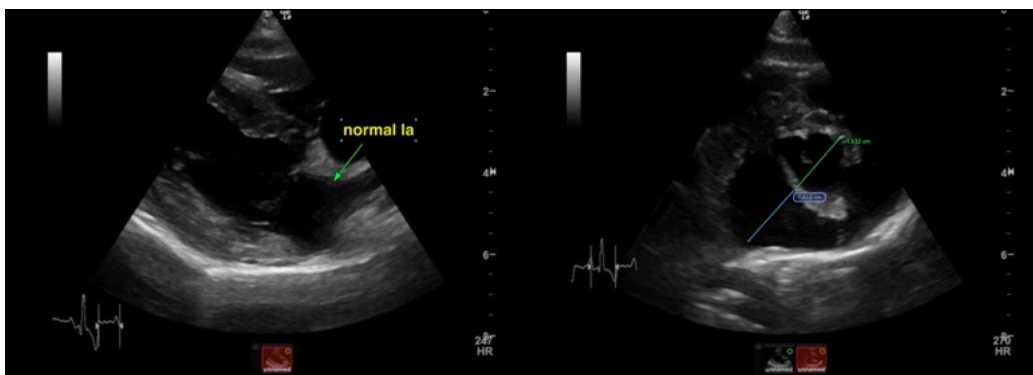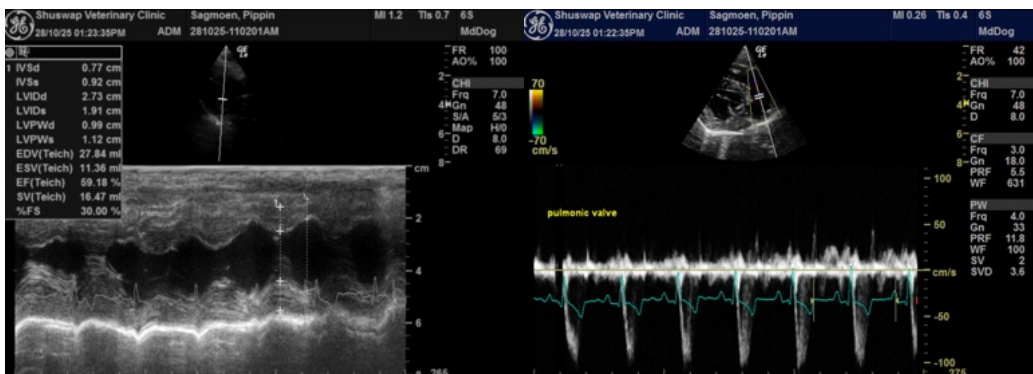
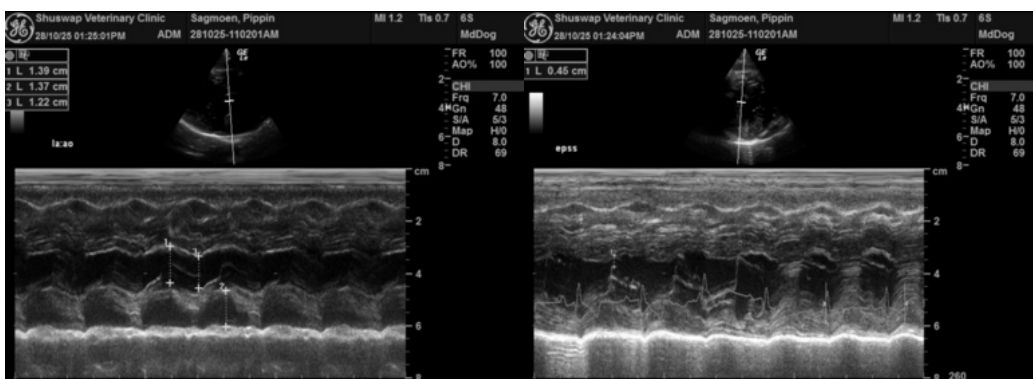
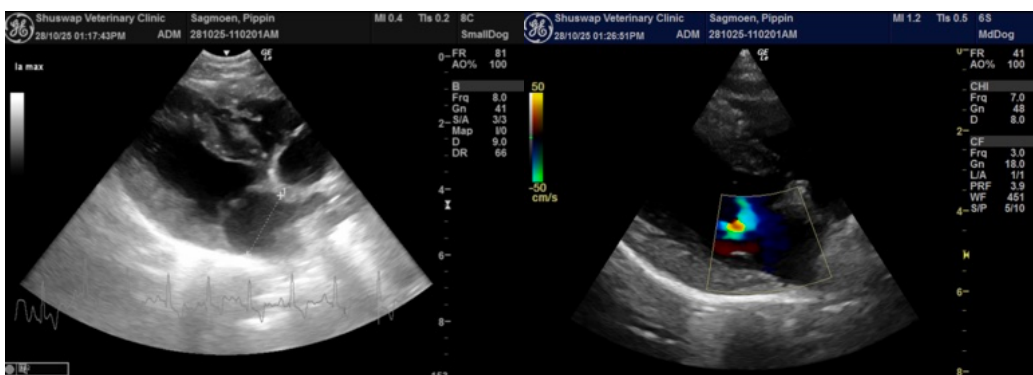
Dr. Horsley

INVOICE

68280

DATE

11/3/25





PATIENT

Pippin Sagmoen

SPECIES

Canine

BREED

Miniature Schnauzer

SEX

Neutered male

AGE

11 years

WEIGHT

8.2 kg

INTERPRETED BY

Eric Lindquist, DMV
DABVP, Cert. IVUSS

IMAGING PERFORMED BY

Kaitlyn Varga

HOSPITAL NAME

Shuswap VC

REFERRING VET

Dr. Horsley

INVOICE

68280

DATE

11/3/25

The information and recommendations provided are based on the images presented by the referring veterinarian/sonographer. No evaluation can be communicated regarding pathology that was not visible in the image/video clips provided.

Thank you for this referral. If the clinical or image interpretation does not parallel your findings or if I can be of any further assistance please contact me.

Eric Lindquist, DMV, DABVP (CFM), Cert. IVUSS, CEO of SonoPath.com

info@SonoPath.com