



PATIENT

McBone Malinowski

SPECIES

Feline

BREED

Domestic Shorthair

SEX

Male

AGE

19 months

WEIGHT

11.1 lbs

INTERPRETED BY

Eric Lindquist, DMV
DABVP, Cert. IVUSS

IMAGING PERFORMED BY

Dr. Levy

HOSPITAL NAME

Court Street VH

REFERRING VET

Dr. Miller

INVOICE

68273

DATE

11/3/25

PRESENTING CLINICAL SIGNS

History: Routine lab work was run and found incidental kidney changes.
Abnormal PE/Chem/CBC/JA Results: Creat 1.6 mg/dL (0.9-2.3), SDMA 17 ug/dL (0-14), Phos 3.6 mmol/L (3.7-5.2) USG 1.034, urine protein 1+

ULTRASONOGRAPHIC EXAMINATION OF THE ABDOMEN

Urinary System

The **urinary bladder** and trigone presented normal thicknesses and normal tone. The ureters were not visible which is normal. No uroliths or sediment were visualized and anechoic urine was present. No evidence of inflammatory or neoplastic changes was noted. Ureteral papillae were normal.

The **kidneys** revealed normal size and structure, corticomedullary definition and ratio for this age. The cortices presented largely uniform texture with normal echogenic relationship to liver and spleen. Medullary structure differed distinctly from the cortex and no evidence of pelvic dilation was present. The capsules were acceptably uniform without significant irregularities. The left kidney measured 3.5 cm. The right kidney measured 3.7 cm.

Adrenal Glands

The **adrenal glands** were not overtly visualized. However, the regions of the adrenal glands appeared unremarkable.

Spleen

The **spleen** was mildly enlarged with uniform parenchyma, and undulating capsular contour. This is consistent with reactive spleen owing to immune stimulus or early infiltrative disease such as mast cell disease or lymphoma. 25-gauge FNA would be ideal if weight loss is an issue to differentiate early round cell neoplasia versus splenitis or reactive spleen all of which can present in this manner. The spleen measured 1.3-1.9 cm in width.

Liver

The **liver** images submitted revealed subjectively normal liver size, contour, and structure. Parenchymal echogenicity was naturally coarse and hypoechoic to the spleen. Vascular and biliary tracts were of normal volume with no evidence of congestion. The gallbladder presented acceptably thin walls with primarily anechoic content. The cystic and common bile ducts were normal. No pathological hepatic lymphadenopathy was evident. No overt structural evidence of inflammatory, infiltrative or regenerative pathology was evident.



PATIENT

McBone Malinowski

SPECIES

Feline

BREED

Domestic Shorthair

SEX

Male

AGE

19 months

WEIGHT

11.1 lbs

INTERPRETED BY

Eric Lindquist, DMV
DABVP, Cert. IVUSS

IMAGING PERFORMED BY

Dr. Levy

HOSPITAL NAME

Court Street VH

REFERRING VET

Dr. Miller

INVOICE

68273

DATE

11/3/25

Gastrointestinal

Examination of the **gastrointestinal tract** revealed a stomach and intestine free of stasis, of normal wall thickness, acceptable curvilinear mural detail, and peristaltic activity. Small and large intestine demonstrated normal luminal chyme and stool consistency respectively. No obstructive or overt infiltrative disease was noted. No associated abnormal lymphatic activity was noted.

Pancreas

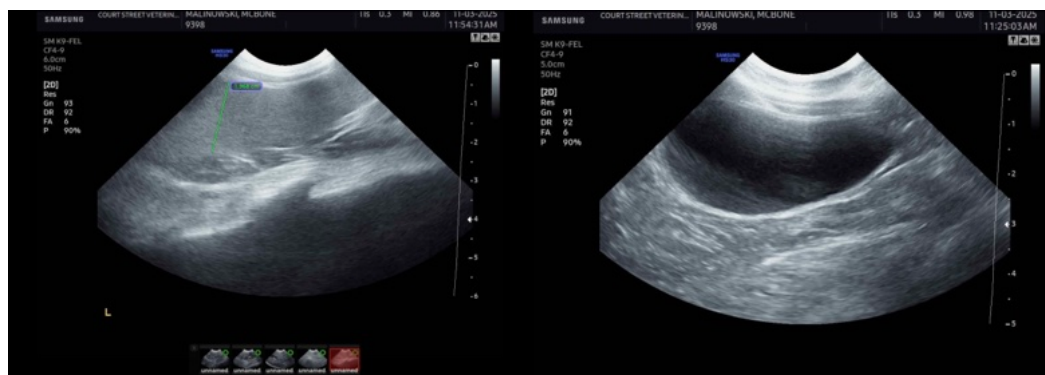
The base and limbs of the **pancreas** were observed to be largely isoechoic to surrounding omental fat. Pancreatic duct and capsular contour were acceptably normal and parenchyma respected normal curvilinear patterns. No overt evidence of active inflammatory or neoplastic disease was noted.

ULTRASONOGRAPHIC FINDINGS

- Splenic enlargement. Round cell neoplasia should be ruled out.

INTERPRETATION OF THE FINDINGS & FURTHER RECOMMENDATIONS

Screening FNA of the spleen is indicated. The SDMA elevation may be a paraneoplastic manifestation as structurally the kidneys appear normal. There is no significant inflammatory sediment in the urine, yet the spleen is solidly enlarged. Some splenic enlargement may occur with sedation, however, this appears excessive if the patient was sedated.





PATIENT

McBone Malinowski

SPECIES

Feline

BREED

Domestic Shorthair

SEX

Male

AGE

19 months

WEIGHT

11.1 lbs

INTERPRETED BY

Eric Lindquist, DMV
DABVP, Cert. IVUSS

IMAGING PERFORMED BY

Dr. Levy

HOSPITAL NAME

Court Street VH

REFERRING VET

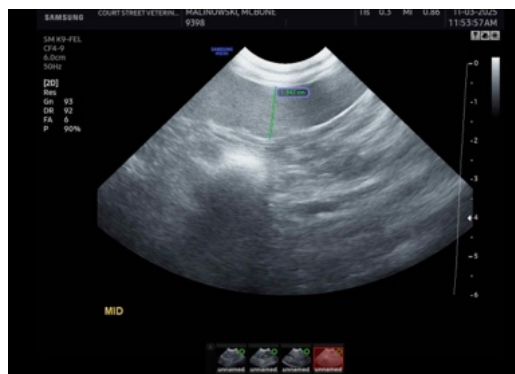
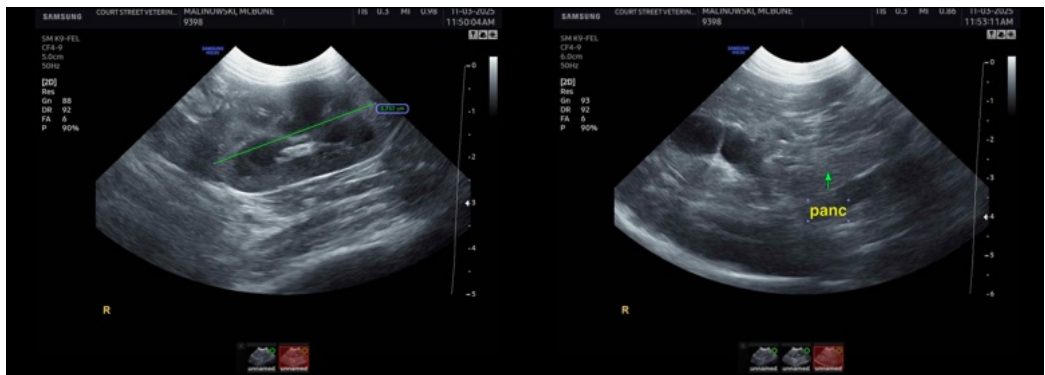
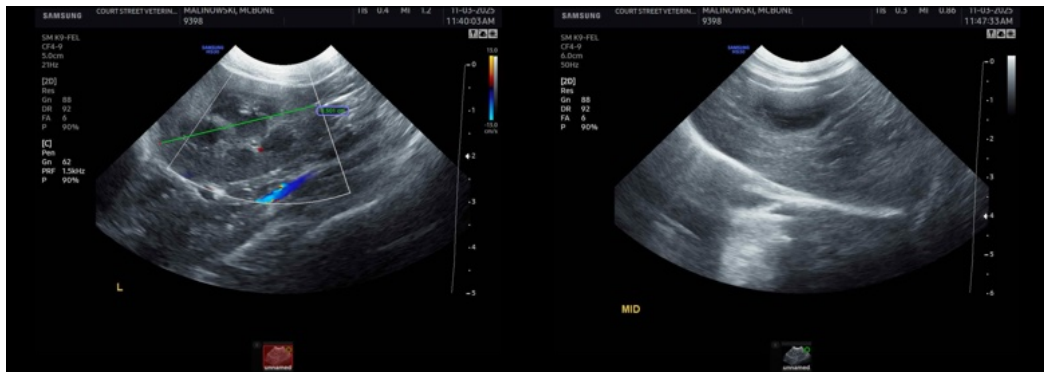
Dr. Miller

INVOICE

68273

DATE

11/3/25



The information and recommendations provided are based on the images presented by the referring veterinarian/sonographer. No evaluation can be communicated regarding pathology that was not visible in the image/video clips provided.

Thank you for this referral. If the clinical or image interpretation does not parallel your findings or if I can be of any further assistance please contact me.

Eric Lindquist, DMV, DABVP (CFM), Cert. IVUSS, CEO of SonoPath.com

info@SonoPath.com