



PATIENT

Lavina Parker
Buckelew

SPECIES

Feline

BREED

Domestic Shorthair

SEX

Spayed female

AGE

2 years

WEIGHT

4.7 lbs

INTERPRETED BY

Eric Lindquist, DMV
DABVP, Cert. IVUSS

IMAGING PERFORMED BY

Dr. Carver

HOSPITAL NAME

Animal Emergency
Hospital Volusia

REFERRING VET

Dr. Carver

INVOICE

68288

DATE

11/3/25

PRESENTING CLINICAL SIGNS

History: Patient presented for not eating or drinking, falling over, and lethargic. Three days ago patient ate a vole's back legs and intestines. No vomiting, diarrhea, coughing or sneezing. Yesterday patient fell over and collapsed. Owner feels patient is dehydrated and breathing weird at home. Indoor/outdoor cat. P had a fever of 105.4 on presentation, it has since normalized. She has become increasingly dull in hospital. She had one episode during the AUS of labored breathing and vocalizing. She has not had any interest in food.

ULTRASONOGRAPHIC EXAMINATION OF THE ABDOMEN

Urinary System

The **urinary bladder**, trigone, and pelvic urethra presented normal thicknesses and normal tone. The ureters were not visible which is normal. No uroliths or sediment were visualized and anechoic urine was present. No evidence of inflammatory or neoplastic changes was noted. Ureteral papillae were normal.

The **kidneys** revealed normal size and structure, corticomedullary definition and ratio for this age. The cortices presented largely uniform texture with normal echogenic relationship to liver and spleen. Medullary structure differed distinctly from the cortex. The capsules were acceptably uniform without significant irregularities. Slight pyelectasia was noted in both kidneys this may be owing to fluid therapy if the patient was on fluids at the time of the sonogram. The right kidney measured 4.3 cm. The left kidney measured 4.2 cm.

Adrenal Glands

Both **adrenal glands** were visualized and recognized as having normal shape, size, position and echogenicity for this breed. The phrenic vasculature, glandular echogenicity and detail were unremarkable. Capsule, cortex, and medullary definition were normal for this age patient. The left adrenal gland measured 0.4 cm. The right adrenal gland measured 0.5 cm.

Spleen

The **spleen** presented a smooth homogeneous parenchyma hyperechoic to liver and renal cortical parenchyma. The capsule was smooth without noticeable expansion or deviation from within the spleen or adjacent pathology. The splenic vasculature demonstrated normal volume without signs of congestion or thrombosis. No sonographic evidence of acute or chronic inflammatory, neoplastic, or infarctual changes was noted.

Liver

The **liver** images submitted revealed subjectively normal liver size, contour, and structure. Parenchymal echogenicity was naturally coarse and hypoechoic to the spleen. The hepatic veins are mildly dilated. This would be normal if the patient is under fluid therapy. The gallbladder presented acceptably thin



PATIENT

Lavina Parker
Bucklelew

SPECIES

Feline

BREED

Domestic Shorthair

SEX

Spayed female

AGE

2 years

WEIGHT

4.7 lbs

INTERPRETED BY

Eric Lindquist, DMV
DABVP, Cert. IVUSS

IMAGING PERFORMED BY

Dr. Carver

HOSPITAL NAME

Animal Emergency
Hospital Volusia

REFERRING VET

Dr. Carver

INVOICE

68288

DATE

11/3/25

walls with primarily anechoic content. The cystic and common bile ducts were normal. Minor hepatic lymphadenopathy was noted and measured up to 0.7 cm. This may be a normal reactive state, yet there was no other evidence of significant disease.

Gastrointestinal

Examination of the **gastrointestinal tract** revealed a stomach and intestine free of stasis, of normal wall thickness, acceptable curvilinear mural detail, and peristaltic activity. Small and large intestine demonstrated normal luminal chyme and stool consistency respectively. No obstructive or overt infiltrative disease was noted. No associated abnormal lymphatic activity was noted.

Pancreas

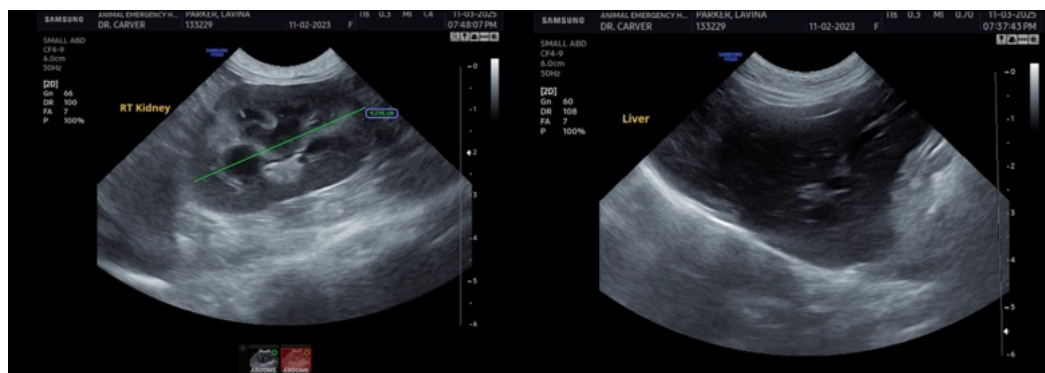
The base and limbs of the **pancreas** were observed to be largely isoechoic to surrounding omental fat. Pancreatic duct and capsular contour were acceptably normal and parenchyma respected normal curvilinear patterns. No overt evidence of active inflammatory or neoplastic disease was noted.

ULTRASONOGRAPHIC FINDINGS

- Dilated hepatic veins. Passive congestion or fluid therapy is suspected.
- Slight hepatic lymphadenopathy.
- Structurally normal abdomen.

INTERPRETATION OF THE FINDINGS & FURTHER RECOMMENDATIONS

CBC path review and bone marrow aspirate is indicated in this patient. There is no evidence of significant visceral disease. Underlying viral disease is a strong potential given the degree of fever and lack of any significant abdominal pathology other than minor reactive hepatopathy. Bartonella and Toxoplasmosis titers are indicated if the patient has been exposed.





PATIENT

Lavina Parker
Buckelew

SPECIES

Feline

BREED

Domestic Shorthair

SEX

Spayed female

AGE

2 years

WEIGHT

4.7 lbs

INTERPRETED BY

Eric Lindquist, DMV
DABVP, Cert. IVUS

IMAGING PERFORMED BY

Dr. Carver

HOSPITAL NAME

Animal Emergency
Hospital Volusia

REFERRING VET

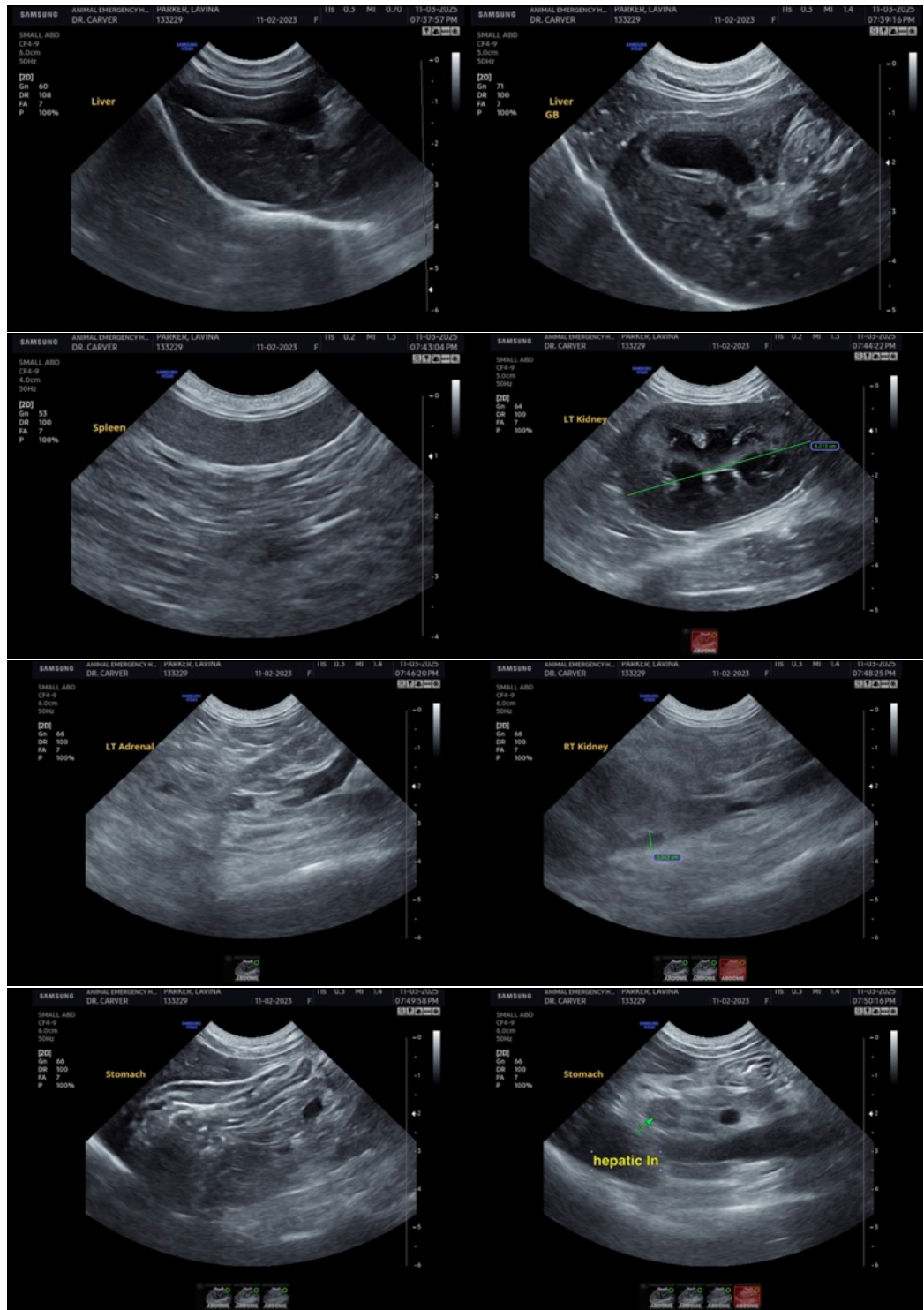
Dr. Carver

INVOICE

68288

DATE

11/3/25





PATIENT

Lavina Parker
Buckelew

SPECIES

Feline

BREED

Domestic Shorthair

SEX

Spayed female

AGE

2 years

WEIGHT

4.7 lbs

INTERPRETED BY

Eric Lindquist, DMV
DABVP, Cert. IVUSS

IMAGING PERFORMED BY

Dr. Carver

HOSPITAL NAME

Animal Emergency
Hospital Volusia

REFERRING VET

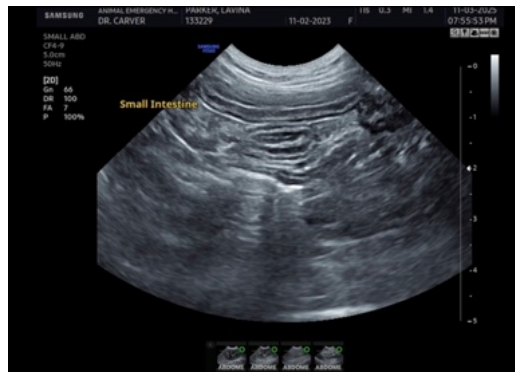Dr. Carver

INVOICE

68288

DATE

11/3/25



The information and recommendations provided are based on the images presented by the referring veterinarian/sonographer. No evaluation can be communicated regarding pathology that was not visible in the image/video clips provided.

Thank you for this referral. If the clinical or image interpretation does not parallel your findings or if I can be of any further assistance please contact me.

Eric Lindquist, DMV, DABVP (CFM), Cert. IVUSS, CEO of SonoPath.com

info@SonoPath.com

Fever of Unknown Origin

<http://www.sonopath.com/FUO>

Description: The definition of a fever of unknown origin (FUO) has not been clearly defined for animals. Currently, it is either understood to be a fever that does not resolve within the period one would expect for a “self-limiting infection” being treated with appropriate antimicrobial therapy, or that for which an underlying diagnosis has not been determined despite considerable diagnostic effort. The common causes of FUO were summarized concisely in a presentation at the American College of Veterinary Internal Medicine 2004 Forum. The presenters synthesized information from three veterinary papers on the subject, which suggested the following:

1.1.Final Diagnosis	1.2.Bennett (dogs & cats)	1.3.Dunn and Dunn 1.4.(dogs only)	1.5.Lunn 1.6.(dogs & one cat)	1.7.Total
Infection	21	16	10	47
Immune	18	22	6	46



PATIENT

Lavina Parker
Buckelew

SPECIES

Feline

BREED

Domestic Shorthair

SEX

Spayed female

AGE

2 years

WEIGHT

4.7 lbs

INTERPRETED BY

Eric Lindquist, DMV
DABVP, Cert. IVUSS

IMAGING PERFORMED BY

Dr. Carver

HOSPITAL NAME

Animal Emergency
Hospital Volusia

REFERRING VET

Dr. Carver

INVOICE

68288

DATE

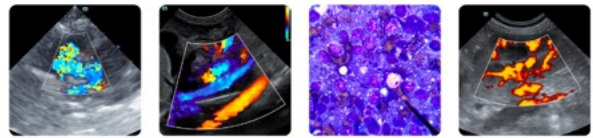
11/3/25

	1.1.Final Diagnosis	1.2.Bennett (dogs & cats)	1.3.Dunn and Dunn 1.4.(dogs only)	1.5.Lunn 1.6.(dogs & one cat)	1.7.Total
Bone marrow disease		4	22	2	28
Neoplasia (outside marrow)		0	10	2	12
Miscellaneous		2	12	2	16
No diagnosis		0	19	2	21
TOTALS		45	101	24	170

The types of infection diagnosed in this case series were varied, ranging from discospondylitis (8 cases), blastomycosis (6), and bacterial endocarditis (4), to leishmaniasis (1), prostatitis (1), and *Ehrlichia canis* infection (1); a multitude of other infectious causes also fell within the spectrum. Of the cases in which immune-mediated disease was found, 44% had immune-mediated polyarthritis. Bone marrow diseases included myeloproliferative disease, myelodysplasia (8), lymphocytic leukemia (8), myeloma (3), chronic granulocytic leukemia (3), lymphoblastic leukemia, and malignant histiocytosis. The types of neoplasia located outside the bone marrow included lymphoma (6), metastatic disease (2), and neoplasms of the lung, spleen, and stomach. Finally, miscellaneous diseases included hypertrophic osteodystrophy (6), meningitis (3), portosystemic shunt (3), lymphadenitis (2), panosteitis, and intervertebral disc disease. Overall, the most common causes across all cases were polyarthritis (44), lymphoid neoplasia (15), discospondylitis (8), myelodysplasia (8), hypertrophic osteodystrophy (6), and blastomycosis (6).

Clinical Signs: Animals usually present with either persistent or waxing and waning fevers ranging from 103°F to 106°F. Other clinical signs depend on the underlying cause of the fever. Careful and thorough physical examination is required to assess potential causes.

Diagnostics: FUI etiologies are partly related to geography, and thus locale or travel history should factor into a practitioner's diagnostic approach. A patient's lifestyle may also provide clues regarding exposure to certain etiologic agents. Therefore, conducting a thorough history can unveil important pieces of the diagnostic puzzle. Physical examination is especially important and should include an inspection of all accessible lymph nodes, palpation and movement of the joints, a fundic examination, a neurological evaluation, spinal and limb palpation and range of motion tests, and a rectal examination.



PATIENT

Lavina Parker
Buckelew

SPECIES

Feline

BREED

Domestic Shorthair

SEX

Spayed female

AGE

2 years

WEIGHT

4.7 lbs

INTERPRETED BY

Eric Lindquist, DMV
DABVP, Cert. IVUSS

IMAGING PERFORMED BY

Dr. Carver

HOSPITAL NAME

Animal Emergency
Hospital Volusia

REFERRING VET

Dr. Carver

INVOICE

68288

DATE

11/3/25

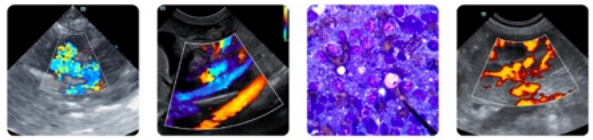
A minimum database should include a CBC reviewed by a clinical pathologist, as well as a biochemical profile and urinalysis. Retroviral testing should also be considered in cats. In areas where tick-borne disease is prevalent, in-house testing should be performed early. Advanced laboratory work can include: urine culture, blood culture, and infectious disease panels (PCR and/or serology). In dogs, one may screen for the following infectious agents: *Ehrlichia* spp., *Borrelia burgdorferi*, Rock Mountain Spotted Fever, *Bartonella* spp. (culture and PCR), and *Leptospira* spp. in cases of hepatic or renal involvement. In cats, one should evaluate for FeLV, FIV, feline infectious peritonitis (FIP) virus, toxoplasmosis, *Hemoplasma* spp. (*Mycoplasma*), and *Bartonella* spp. (culture and PCR). Testing for *Ehrlichia* spp., *Rickettsia* spp., and *Anaplasma phagocytophilum* can also be considered. A fungal assay is indicated if the patient lives in or has had exposure to a region with a higher incidence of fungal disease. Other infectious disease tests may be performed depending on the geographical location of the pet. Screening for *Brucella* should be done in breeding dogs. Immune-mediated disease screening can include a Coomb's test, a slide agglutination test (if the patient is anemic), and an antinuclear antibody (ANA) test. Immune disease is often a diagnosis of exclusion.

Imaging should include thoracic radiographs, abdominal ultrasound, and/or abdominal radiographs. Ultrasound can be very useful for assessing evidence of cholangiohepatitis, pyelonephritis, chronic urinary tract infection, abscess formation, peritonitis, and neoplasia; it also permits an examination of the intra-abdominal lymph nodes. An echocardiogram can offer assessment for vegetative endocarditis, whereas spinal radiographs offer assessment for discospondylitis. In cases where all other testing has proven negative and the patient has not responded to broad-spectrum antibiotics and supportive care, arthrocentesis should be considered to evaluate for septic joint disease, immune-mediated polyarthritis, and infectious disease. Finally, one can consider assessing the cerebrospinal fluid for meningoencephalitis, GME, and meningitis/arteritis. A bone marrow exam should be performed if blood dyscrasias are noted on the CBC.

Treatment: Treatment of the fever depends entirely on the underlying cause. Ideally, a thorough diagnostic plan will yield a diagnosis that will guide the appropriate therapeutic course. However, if an exhaustive approach has not produced a definitive diagnosis and there is no response to broad-spectrum antibiotics, trial therapy with immunosuppressive agents such as prednisolone can be considered to treat presumed immune-mediated diseases. Given the potential for negative sequelae should an underlying infection be present, one must be certain that the investigation is thorough and monitor the patient's response carefully.

Conclusion: If a documented fever has not responded to antibiotics, antipyretics, or general nursing care, it is important to obtain a diagnosis to guide more specific treatment. A systematic physical examination and thorough history-taking will help inform further diagnostics in addition to what is revealed by the minimum database.

References:



PATIENT

Bennet D. Diagnosis of pyrexia of unknown origin. *In Practice* 1995;17(10):470-81.

Lavina Parker
Buckelew

Dunn KJ, Dunn JK. Diagnostic investigations in 101 dogs with pyrexia of unknown origin. *J Sm Anim Pract* 1998;39(12):574-80.

SPECIES

Feline

Flood J. The diagnostic approach to fever of unknown origin in cats. *Compend Contin Educ Vet* 2009;31(1):26-31.

BREED

Domestic Shorthair

Flood J. The diagnostic approach to fever of unknown origin in dogs. *Compend Contin Educ Vet* 2009;31(1):14-21.

SEX

Spayed female

Lappin MR. The role of blood borne pathogens in feline fever of unknown origin. Proceedings from the American College of Veterinary Internal Medicine, Denver, CO, June 15-18, 2011.

AGE

2 years

Lunn KF. Fever of unknown origin: a systematic approach to diagnosis. *Compend Contin Educ Vet* 2001;23(11):976-92.

WEIGHT

4.7 lbs

Lunn KF. Fever of unknown origin: appropriate choice of diagnostic tests. Proceedings from the American College of Veterinary Internal Medicine, Minneapolis, MN, June 9-12, 2004.

INTERPRETED BY

Eric Lindquist, DMV
DABVP, Cert. IVUSS

IMAGING PERFORMED BY

Dr. Carver

HOSPITAL NAME

Animal Emergency
Hospital Volusia

REFERRING VET

Dr. Carver

INVOICE

68288

DATE

11/3/25