

PATIENT

Echo Scherer

SPECIES

Canine

BREED

Mix

SEX

Neutered male

AGE

13 years

WEIGHT

56 lbs

INTERPRETED BY

Eric Lindquist, DMV
DABVP, Cert. IVUSS

IMAGING PERFORMED BY

Chelsea Pastor

HOSPITAL NAME

Fredon AH

REFERRING VET

Dr. Grau

INVOICE

42321

DATE

11/3/22

PRESENTING CLINICAL SIGNS

History: Mass removal R shoulder 10/19/22, grade 2 mast cell w/clean margins Suture removal 10/26/22 At emergency 10/28/22.. Horner's syndrome, cp delayed, knuckling right hind, motor and pain ok, decrease femoral pulse and cold paw right hind Ultrasound showed aortic thrombus in iliac trifurcation, pt has been on plavix and is clinically improved, using leg, cool but not cold, pulse still very weak, was very agitated by scan so limited follow up scan to aortic trifurcation, area of primary concern
Abnormal PE/Chem/CBC/UA Results: improving use and temperature to right hind

ULTRASONOGRAPHIC EXAMINATION

The iliac lymph nodes are unremarkable. Inspissated blood was noted in the aorta in this patient.

ULTRASONOGRAPHIC FINDINGS

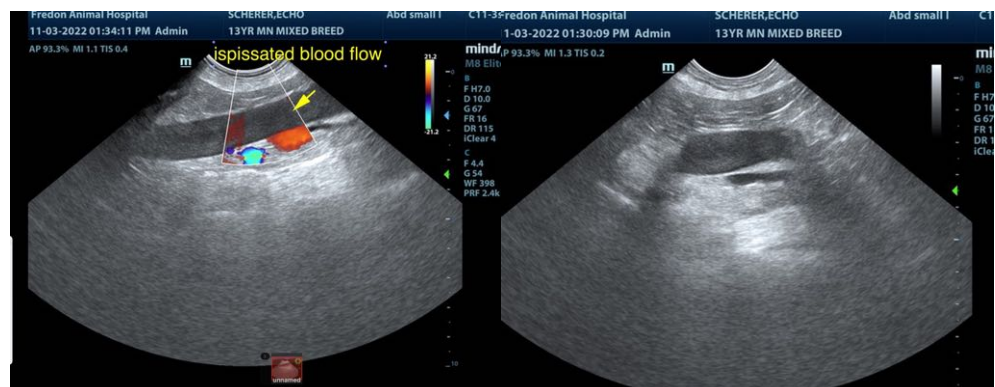Inspissated blood flow without thrombosis.

INTERPRETATION OF THE FINDINGS & FURTHER RECOMMENDATIONS

Assessment for hypercoagulable/pre-thrombotic state is recommended. However, no overt thrombus was present. Hydration status should be evaluated as well. The iliac trifurcation appeared to be clear. I cannot rule out distal thrombosis in the iliac arteries. Given the patient's history skull and cervical spinal CT is indicated.

ABOUT SONOPATH CT SERVICES:

SonoPath CT Services are offered at the SonoPath Imaging and Veterinary Education Center, 141 Main St (rt 206), Andover, New Jersey, a 20-minute drive west on route 80/206 North from the route 80/287 interchange/Parsippany, New Jersey. More information can be found at <https://sonopath.com/services/sonopath-ct-services>





PATIENT

Echo Scherer

SPECIES

Canine

BREED

Mix

SEX

Neutered male

AGE

13 years

WEIGHT

56 lbs

INTERPRETED BY

Eric Lindquist, DMV
DABVP, Cert. IVUSS

**IMAGING
PERFORMED BY**

Chelsea Pastor

HOSPITAL NAME

Fredon AH

REFERRING VET

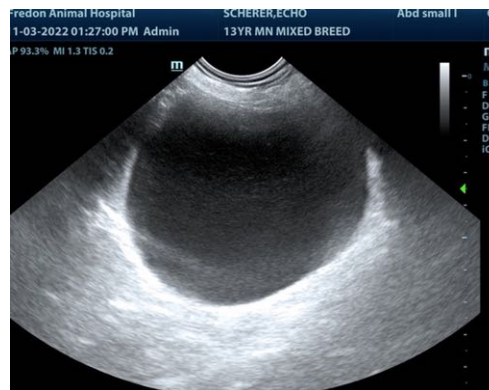
Dr. Grau

INVOICE

42321

DATE

11/3/22



The information and recommendations provided are based on the images presented by the referring veterinarian/sonographer. No evaluation can be communicated regarding pathology that was not visible in the image/video clips provided.

Thank you for this referral. If the clinical or image interpretation does not parallel your findings or if I can be of any further assistance please contact me.

Eric Lindquist, DMV, DABVP, Cert. IVUSS, CEO of SonoPath.com
info@SonoPath.com