

**DATE**

11/29/22

PRESENTING CLINICAL SIGNS

Treating pet for multiple weeks - Liver values elevated and T4 initially elevated- treated hyperthyroidism; no clinical improvement, liver no improvement and kidney values worsened. Stopped treating hyperthyroidism, started treating kidneys

PATIENT

Trouble Casey

Recommend ultrasound to look for liver disease

Notes: LE - still up-- plump liver on rads

Thyroid now low still and renal up more--- d/c methimazole doing k/d, no sub q fluids yet consider US

SPECIES

Feline

Current Medications: Tresaderm Solution, Maropitant Citrate (Cerenia) 10mg/mL Solution Injection, Vitamin B12 1000mcg/mL Injection.

Lab Results: Attached.

Date of Previous IntraPet Ultrasound: No previous.

BREED

Domestic Shorthair

Sedation: Not required to complete full diagnostic ultrasound.

Stat Report: Not requested.

Imaging Performed By: Rachel Brillhart, RDMS.

SEX

Spayed female

ULTRASONOGRAPHIC EXAMINATION OF THE ABDOMEN**Urinary System**

The **urinary bladder**, trigone, and pelvic urethra presented normal thicknesses and normal tone. The ureters were not visible which is normal. No uroliths or sediment were visualized and anechoic urine was present. No evidence of inflammatory or neoplastic changes was noted. Ureteral papillae were normal.

AGE

2007

The **kidneys** revealed largely normal structure, corticomedullary definition and ratio (cortex 1/3 of medulla) were essentially maintained with some age-related loss of curvilinear patterns regarding the capsule and C/M junction. The cortices presented largely uniform texture with some increased echogenicity expected for his age patient. Medullary structure differed distinctly from that of the cortex. Mild mineralization was noted. The left kidney was normal in size and measured 3.86 cm. The right kidney revealed pelvic calculus that measured 0.4 cm. Pyelectasia in the right kidney measured 0.36 cm. The right kidney was slightly subnormal in size and measured 2.91 cm.

WEIGHT

7.4 lbs

INTERPRETED BY

Eric Lindquist, DMV
DABVP, Cert. IVUSS

Adrenal Glands

Both **adrenal glands** were visualized and recognized as having normal shape, size, position and echogenicity for this breed. The phrenic vasculature, glandular echogenicity and detail were unremarkable. Capsule, cortex, and medullary definition were normal for this age patient. The right adrenal gland measured 0.4 cm.

HOSPITAL NAME

Animal Emergency
Hospital

Spleen

The **spleen** was mildly enlarged with uniform, but subtly micronodular parenchyma, and undulating capsular contour. This is consistent with reactive spleen owing to immune stimulus or early infiltrative disease such as mast cell disease or lymphoma. 25-gauge FNA would be ideal if weight loss is an issue to differentiate early round cell neoplasia versus splenitis or reactive spleen all of which can present in this manner.

REFERRING VET

Dr. King

INVOICE

42768

Liver

The **liver** revealed mild enlargement with mildly increased portal markings. The gallbladder and common bile duct were unremarkable. The common bile duct measured 0.3 cm.

Gastrointestinal

The **gastrointestinal tract** revealed minor variable thickening and echogenic submucosal changes most consistent with low grade end result of chronic GI disease such as IBD and may be related to malassimilation

of nutrients if any weight loss is present. No obvious neoplastic patterns were noted and luminal content as unremarkable.

Pancreas

The **pancreas** was mildly enlarged and measured up to 1.0 cm. The pancreas was hypoechoic and mildly irregular.

ULTRASONOGRAPHIC FINDINGS

Non-specific inflammatory hepatopathy.

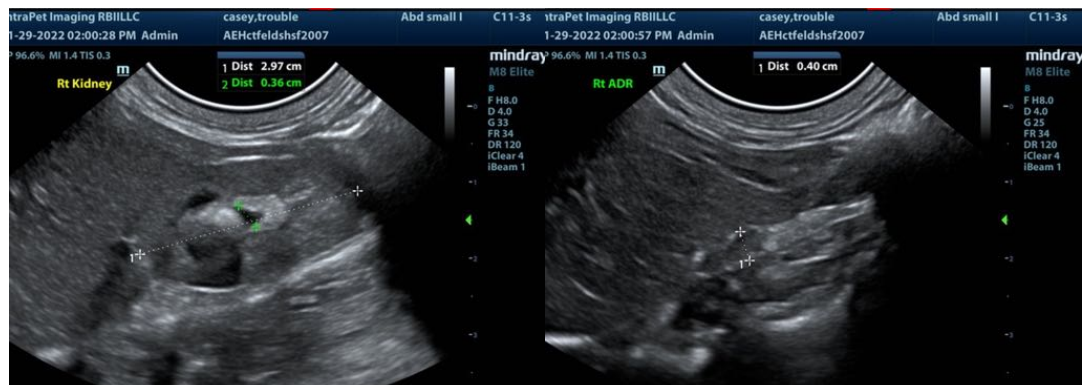
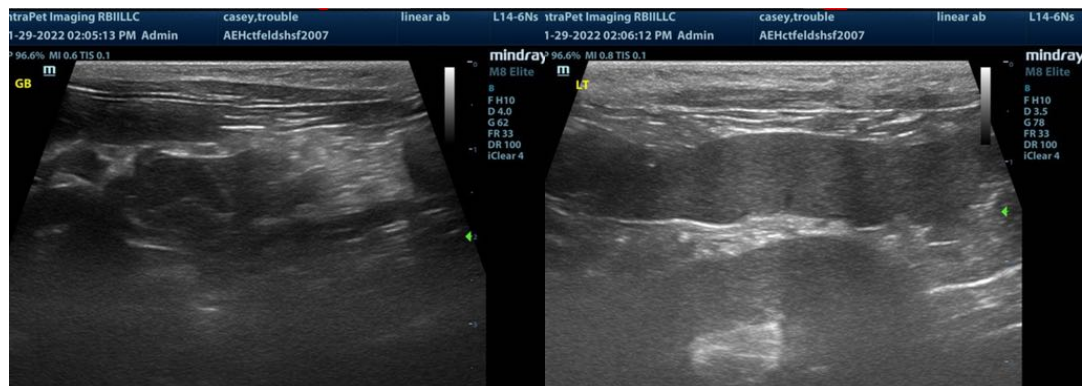Prominent pancreas.

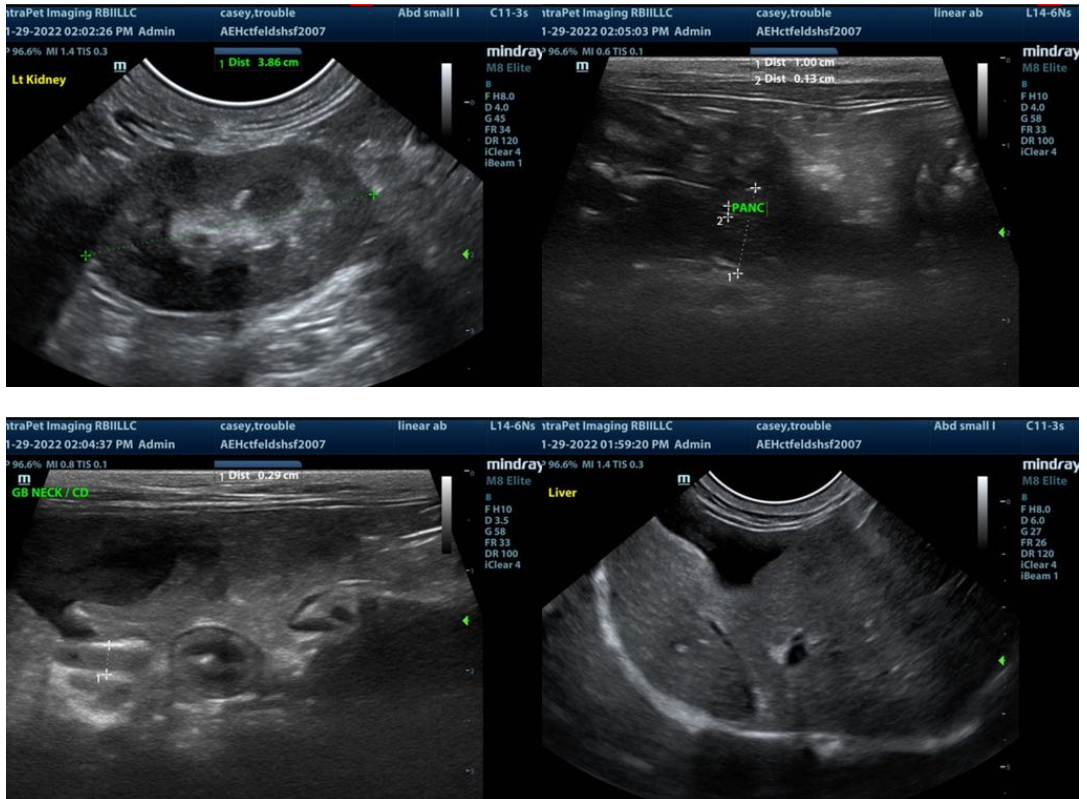
Minor splenic enlargement.

Non-obstructive right nephrolithiasis with moderate degenerative renal changes.

INTERPRETATION OF THE FINDINGS & FURTHER RECOMMENDATIONS

FNA of the liver and spleen +/- pancreas is indicated for further definition. History of pancreatitis is likely. This is likely a chronic triaditis patient; however, emerging round cell neoplasia is always a potential.





The information and recommendations provided are based on the images presented by the referring veterinarian. No evaluation can be communicated regarding pathology that was not visible in the image/video clips provided.

Thank you for this referral. If the clinical or image interpretation does not parallel your findings or if I can be of any further assistance please contact me.

Eric Lindquist, DMV, DABVP, Cert. IVUSS, CEO of SonoPath.com
 Eric.Lindquist@SonoPath.com