



PATIENT

Sergeant Whiskers
O'Brien

SPECIES

Feline

BREED

DSH

SEX

Neutered Male

AGE

14 Years

WEIGHT

21 Lbs.

INTERPRETED BY

Eric Lindquist, DMV
DABVP, Cert. IVUSS

IMAGING PERFORMED BY

Jenn

HOSPITAL NAME

Rockaway AH

REFERRING VET

Dr. Maniar

INVOICE

94149

DATE

11/29/21

PRESENTING CLINICAL SIGNS

History: labored breathing on and off gagging, bicavitary effusion

ULTRASONOGRAPHIC EXAMINATION OF THE HEART

The echocardiogram in this patient demonstrated normal **left atrial** size based on 3 separate LA measurements. The cranial and caudal **mitral** valve leaflets presented normal linear structure and kinetics. The **left ventricle** presented normal thicknesses with linear contour and was not dilated nor restricted. The **myocardium** presented normal echogenicity without subjective evidence of significant fibrotic or ischemic disease. **Contractility** of the ventricular walls was adequate and in normal range for this patient evidenced by the fractional shortening measurement and subjective evaluation of the different regions and angles of the myocardium. The **left ventricular outflow** tract demonstrated normal laminar flow and subjective structural integrity. The **right atrium** and auricle revealed normal size, structure and content. No evidence of masses was noted or chamber overload. **Tricuspid** valvular assessment demonstrated adequate linear morphology and kinetics. The **right ventricle** was of normal size (1/3 diameter of LV), chordae structure, myocardial echogenicity and thickness. **Pulmonic** tract assessment revealed normal valve structure, laminar flow, and diameter (approx. 1:1 pa/ao ratio). Non cardiogenic **pleural effusion** was noted. Arrhythmogenic activity was present.

FELINE CARDIAC PARAMETERS	BODY WEIGHT	HR (BPM)	IVSd (cm)	LVIDd (cm)	LVWd (cm)	FS (%)	EF (%)
NORMAL PARAMETER	-----	150-240	0.3-0.6	1.0-2.1	0.25-0.6	35-67	80-100
PATIENT	21 lbs	NM					
FELINE CARDIAC PARAMETERS	LA/AO (Boon)	LA/AO HEART BASE (Sisson)	LA 2D 4-chamber long axis AS to FW (Sisson) (cm)	LVOT VEL. (m/s)	RVOT VEL. (m/s)	IVRT (m)	
NORMAL PARAMETER	<1.5	0.88-1.79	0.7-1.7	<1.6	<1.3	40-60	
PATIENT	1.2	1.2	1.0		1.4	NM	
Adapted from June Boon, Veterinary Echocardiography, 1998 Sisson D et al. JVIM 1991; 5: 232, Jacobs et al. Am J Vet Res 1985; 46:1705							



PATIENT

ULTRASONOGRAPHIC EXAMINATION OF THE ABDOMEN

Sergeant Whiskers
O'Brien

Urinary System

The **urinary bladder**, trigone, and pelvic urethra presented normal thicknesses and normal tone. The ureters were not visible which is normal. No uroliths or sediment were visualized and anechoic urine was present. No evidence of inflammatory or neoplastic changes were noted. Ureteral papillae were normal.

SPECIES

Feline

BREED

DSH

The **kidneys** revealed normal size and structure, corticomedullary definition and ratio for this age. The cortices presented largely uniform texture with normal echogenic relationship to liver and spleen. Medullary structure differed distinctly from the cortex and no evidence of pelvic dilation was present. The capsules were acceptably uniform without significant irregularities.

SEX

Neutered Male

Adrenal Glands

Both **adrenal glands** were visualized and recognized as having normal shape, size, position and echogenicity for this breed. The phrenic vasculature, glandular echogenicity and detail were unremarkable. Capsule, cortex, and medullary definition were normal for this age patient.

AGE

14 Years

Spleen

The **spleen** in this patient was uniform, yet volume contracted. Hydration status should be assessed.

WEIGHT

21 Lbs.

INTERPRETED BY

Liver

Eric Lindquist, DMV
DABVP, Cert. IVUSS

The **liver** was uniform in size and contour. There was no evidence of passive congestion. The gallbladder presented acceptably thin walls with primarily anechoic content. The cystic and common bile ducts were normal.

IMAGING PERFORMED BY

Jenn

Gastrointestinal

HOSPITAL NAME

Rockaway AH

The **gastrointestinal tract** was unremarkable, yet nodular omental adhesions and nodular changes envelop portions of the gastrointestinal tract. A large amount of coalescing omental nodular changes were noted in the cranial abdomen with a large amount of echogenic ascites.

REFERRING VET

Dr. Maniar

Pancreas

The omentum appeared to be coalescing around the **pancreas**, which was nodular and irregular.

INVOICE

94149

DATE

11/29/21



PATIENT

ULTRASONOGRAPHIC FINDINGS

Sergeant Whiskers
O'Brien

- Carcinomatosis/dual cavity neoplastic pattern.

SPECIES

INTERPRETATION OF THE FINDINGS & FURTHER RECOMMENDATIONS

Feline

An abdominocentesis and pleurocentesis with cytospin is recommended to confirm the suspicion of neoplasia.

BREED

DSH

SEX

Neutered Male

AGE

14 Years

WEIGHT

21 Lbs.

INTERPRETED BY

Eric Lindquist, DMV
DABVP, Cert. IVUSS

IMAGING PERFORMED BY

Jenn

HOSPITAL NAME

Rockaway AH

REFERRING VET

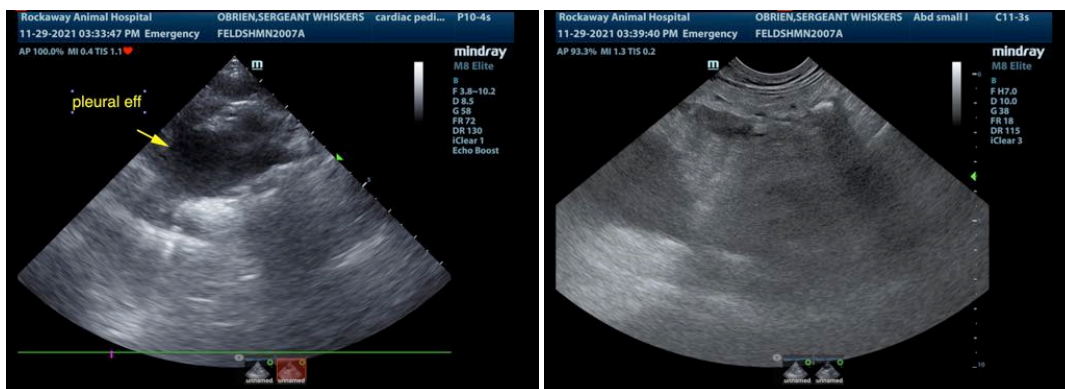
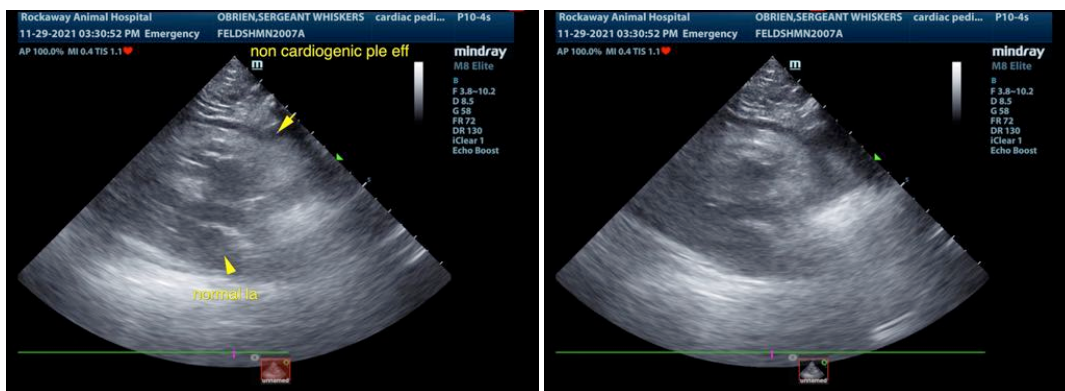
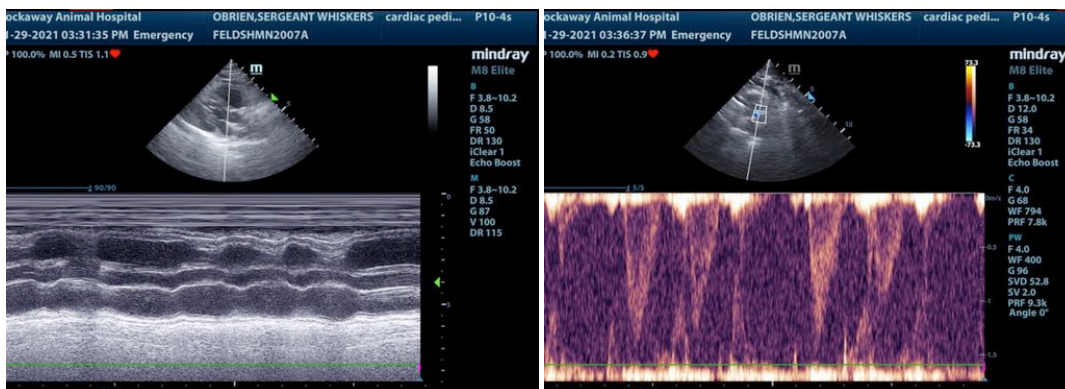
Dr. Maniar

INVOICE

94149

DATE

11/29/21





PATIENT

Sergeant Whiskers
O'Brien

SPECIES

Feline

BREED

DSH

SEX

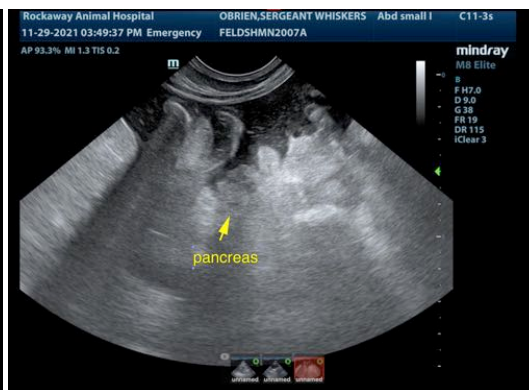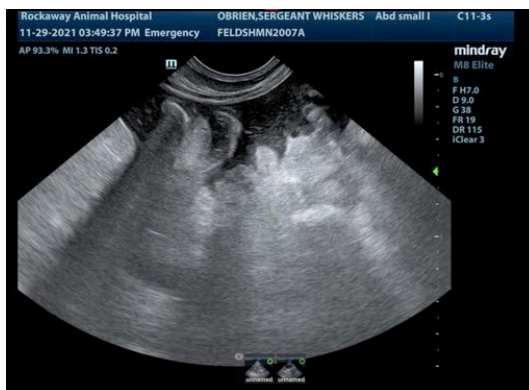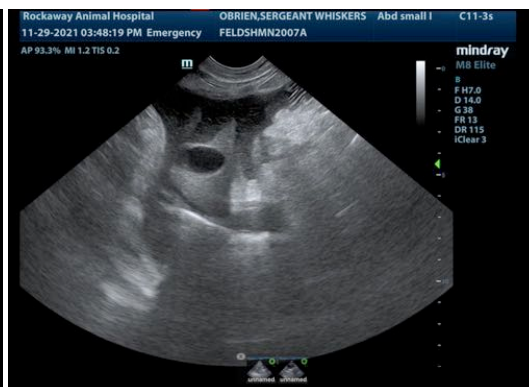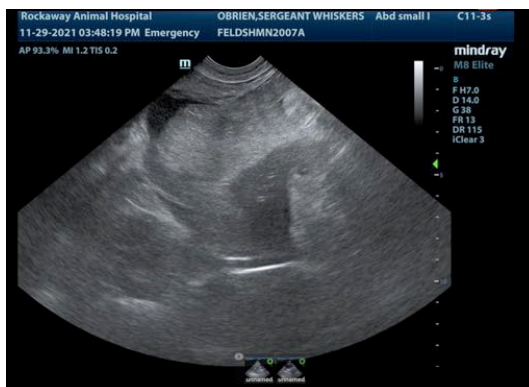Neutered Male

AGE

14 Years

WEIGHT

21 Lbs.



INTERPRETED BY

Eric Lindquist, DMV
DABVP, Cert. IVUSS

IMAGING PERFORMED BY

Jenn

HOSPITAL NAME

Rockaway AH

REFERRING VET

Dr. Maniar

INVOICE

94149

DATE

11/29/21

The information and recommendations provided are based on the images presented by the referring veterinarian. No evaluation can be communicated regarding pathology that was not visible in the image/video clips provided.

Thank you for this referral. If the clinical or image interpretation does not parallel your findings or if I can be of any further assistance please contact me.

Eric Lindquist, DMV, DABVP, Cert. IVUSS, CEO of SonoPath.com
info@SonoPath.com