

PATIENT PRESENTING CLINICAL SIGNS

Pepper Schwartz History: Heart murmur 3-4/6. Echo prior to a dental
Abnormal PE/Chem/CBC/UA Results: N/A

SPECIES

Canine

BREED

Miniature Poodle

SEX

Spayed Female

AGE

14 years

WEIGHT

8.8 lbs

ULTRASONOGRAPHIC EXAMINATION OF THE HEART

The echocardiogram in this patient demonstrated normal **left atrial** size based on 3 different LA measurement methods. Chamber volumes and echogenicity were normal. The cranial and caudal **mitral** valve leaflets presented vegetative thickening consistent with endocardiosis. Doppler indicated measurable insufficiency. The **left ventricle** presented thicknesses with linear contour and was not dilated nor restricted. The **myocardium** presented normal echogenicity without subjective evidence of significant fibrotic or ischemic disease. **Contractility** of the ventricular walls was adequate and in normal range for this patient evidenced by the fractional shortening measurement and subjective evaluation of the different regions of the myocardium. The **left ventricular outflow** tract demonstrated normal laminar flow and subjective structural integrity. The **right atrium** and auricle revealed normal size, structure and content. No evidence of masses was noted or chamber overload. **Tricuspid** valvular assessment demonstrated adequate linear morphology. The **right ventricle** was of normal size (1/3 diameter of LV), chordae structure, myocardial echogenicity and thickness. **Pulmonic** tract assessment revealed normal valve structure, laminar flow, and diameter (approx. 1:1 pa/ao ratio). No visible **pericardial** or free pleura fluid was noted. No echographically detectable evidence of infiltrative disease was visible. The cranial **mediastinum and pericardial regions** were free of masses in the visible window. Occasional arrhythmia was noted in this patient.

INTERPRETED BY

Eric Lindquist, DMV
DABVP, Cert. IVUSS

IMAGING PERFORMED BY

Dr. Rodriguez

HOSPITAL NAME

Foxfield VS

REFERRING VET

Dr. Rodriguez

INVOICE

94162

DATE

11/29/21

CANINE CARDIAC PARAMETERS	MR VMAX (m/s)	TR VMAX (m/s)	LA/AO (Boon method)	LA/AO (Heart Base; Swe)	FS (%)	EF (%)	EPSS (cm)
NORMAL PARAMETER	4.5-5.5	<2.7	1.3	<1.6	28-40	40-100	<0.6
PATIENT	5.0		1.1	1.3	78	98	NM
CANINE CARDIAC PARAMETERS	HR (BPM)	AV VMAX (m/s)	PV MAX (m/s)	BODY WEIGHT	LA 2D short axis Base view (cm)	LVIDd Avg; 2D and m- mode short axis (cm)	LVIDs Avg; 2D and m- mode short axis (cm)
NORMAL PARAMETER	50-100	0.7-1.7	0.7-1.6				
PATIENT		1.0	0.7	8.8 lbs	1.84	1.59	



PATIENT

Pepper Schwartz

ULTRASONOGRAPHIC FINDINGS

Stage B1 valvular disease.

SPECIES

Canine

Occasional arrhythmia.

BREED

Miniature Poodle

INTERPRETATION OF THE FINDINGS & FURTHER RECOMMENDATIONS

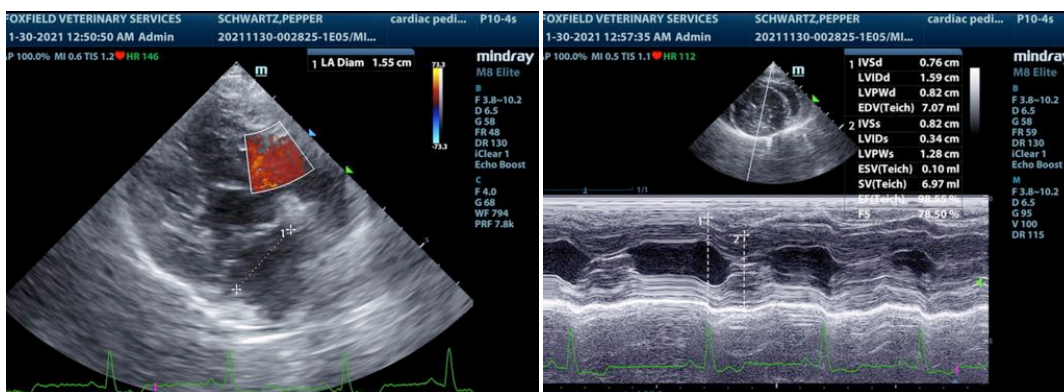
There is no overt contraindication to anesthetic procedure. Suggested protocol includes Torbutrol premed, Propofol induction, and Isoflurane maintenance. Recheck echocardiogram in 6 months or earlier if murmur grade increases or clinical signs initiate. Blood pressure measurements are warranted. If systolic pressure is > 160 then ace inhibitor therapy is indicated. EKG is indicated prior to dental procedure.

AGE

14 years

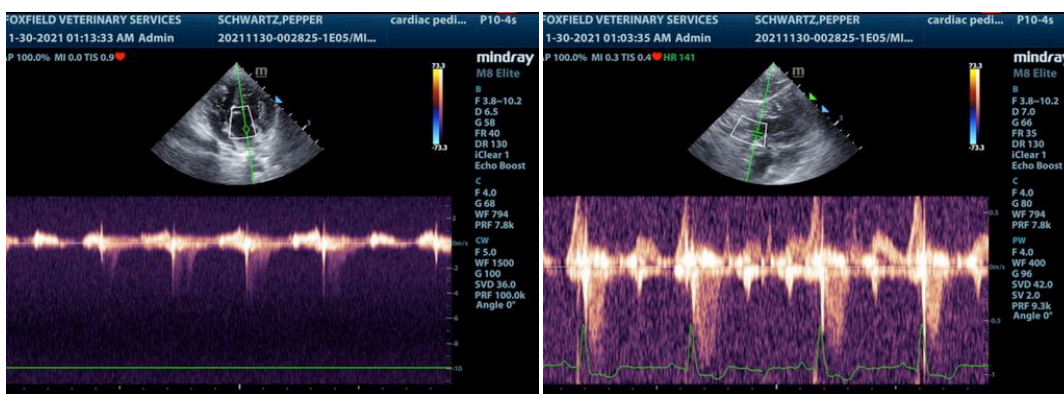
WEIGHT

8.8 lbs



INTERPRETED BY

Eric Lindquist, DMV
DABVP, Cert. IVUS



IMAGING PERFORMED BY

Dr. Rodriguez

HOSPITAL NAME

Foxfield VS

REFERRING VET

Dr. Rodriguez

INVOICE

94162

DATE

11/29/21



PATIENT

Pepper Schwartz

SPECIES

Canine

BREED

Miniature Poodle

SEX

Spayed Female

AGE

14 years

WEIGHT

8.8 lbs

INTERPRETED BY

Eric Lindquist, DMV
DABVP, Cert. IVUSS

IMAGING PERFORMED BY

Dr. Rodriguez

HOSPITAL NAME

Foxfield VS

REFERRING VET

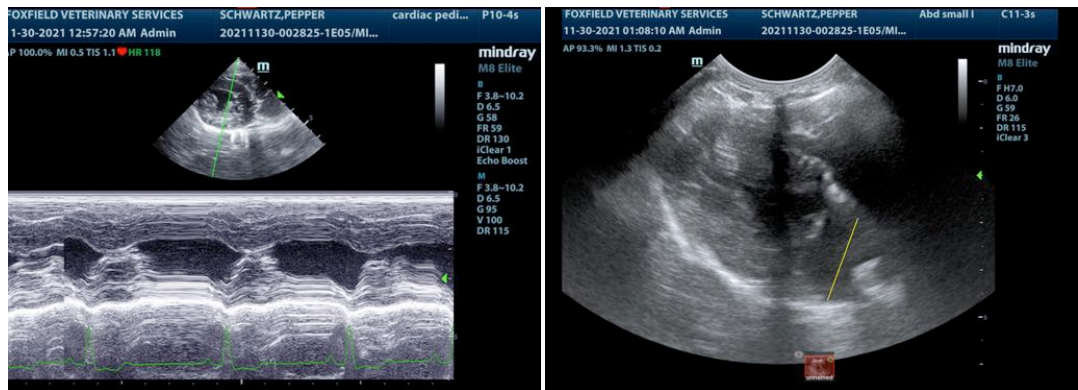
Dr. Rodriguez

INVOICE

94162

DATE

11/29/21



The information and recommendations provided are based on the images presented by the referring veterinarian. No evaluation can be communicated regarding pathology that was not visible in the image/video clips provided.

Thank you for this referral. If the clinical or image interpretation does not parallel your findings or if I can be of any further assistance please contact me.

Eric Lindquist, DMV, DABVP, Cert. IVUSS, CEO of SonoPath.com
info@SonoPath.com